

# Controlled Trial to Compare Therapeutic Efficacy of Endoscopic Third Ventriculostomy Plus Choroid Plexus Cauterization with Ventriculoperitoneal Shunt in Infants with Obstructive Hydrocephalus

## Abstract

**Context:** Ventriculoperitoneal (VP) shunt and endoscopic third ventriculostomy (ETV) are the established surgical treatments for obstructive hydrocephalus (HCP). Powerful evidence regarding the best therapeutic approach for infants with obstructive HCP is lacked. **Aims:** Comparison of the therapeutic efficacy of VP shunt and ETV/choroid plexus cauterization (CPC) in infants with obstructive HCP. **Settings and Design:** This was a randomized, active control, unblind, single-center, clinical trial. **Methods:** Infants with obstructive HCP were randomly allocated to each intervention group (ETV/CPC or VP shunt). They were monitored for at least 6 months for any sign of raised intracranial pressure (rICP). The recurrence of rICP signs requiring surgical intervention was considered as intervention failure. **Statistical Analysis:** The association between intervention group and outcome was tested with Chi-square test, and  $P = 0.05$  or less was considered statistically significant. **Results:** Of the total fifty patients entering the study, 49 were included in the final analysis, 27 of them were in VP shunt and 22 in ETV/CPC group. Seventeen patients (34%) were female and 33 (66%) were male with mean age of  $3.74 \pm 3.1$  months (range = 10 days – 11 months). Thirty-nine (79.6%) were under 6 months of age and the remaining were 6 months or older. The overall success rate in 36-month follow-up was 88.5% and 68.2% for VP shunt and ETV/CPC, respectively, with the difference being not statistically significant. **Conclusion:** The current study determined no inferiority of ETV/CPC compared to VP shunt, and therefore, it may become an efficient treatment for obstructive HCP in infants.

**Keywords:** Endoscopic third ventriculostomy, hydrocephalus, success, ventriculoperitoneal shunt

## Introduction

Hydrocephalus (HCP) could be defined as abnormal accumulation of cerebrospinal fluid (CSF) in cerebral ventricles resulting in raised intracranial pressure (rICP) which could lead to abnormal increase in head circumference when occurring in infancy.<sup>[1]</sup> HCP incidence has been reported to be increasing to 0.7 in 1000 live births within the last two decades which might be a result of improved prenatal diagnosis and enhancing survival of postintraventricular hemorrhage premature HCP.<sup>[1]</sup> HCP has been treated with ventriculoperitoneal (VP) shunt for over five decades, which used to be considered as the only treatment method for this disease.<sup>[2]</sup>

Although known as the most common treatment, VP shunt is associated with serious complications including infection, obstruction, and overdrainage, which

require surgical or medical intervention. Therefore, shunt maintenance for 1 and 2 years has been reported 61% and 47%, respectively.<sup>[2]</sup> On the other hand, since VP shunt would reduce the size of dilated ventricles, it may lead to slit ventricle syndrome which would be responsible for more complications in case of shunt revision indication.<sup>[3]</sup>

Recommended as an effective alternative treatment for obstructive HCP, endoscopic third ventriculostomy (ETV) has lower infection risk and when indicated, it may have relatively acceptable outcomes.<sup>[4]</sup> In cases who underwent ETV following shunt complications as infection or shunt malfunction, response to treatment rate has been reported 67%–87%.<sup>[5–8]</sup> However, the innate condition of patients as young age, HCP etiology, and extent

**How to cite this article:** Navaei AA, Hanaei S, Habibi Z, Jouibari MF, Heidari V, Naderi S, *et al.* Controlled trial to compare therapeutic efficacy of endoscopic third ventriculostomy plus choroid plexus cauterization with ventriculoperitoneal shunt in infants with obstructive hydrocephalus. *Asian J Neurosurg* 2018;13:1042-7.

Amir Amini Navaei,  
Sara Hanaei<sup>1</sup>,  
Zohreh Habibi<sup>1</sup>,  
Morteza Faghih  
Jouibari,  
Vahid Heidari<sup>1</sup>,  
Soheil Naderi<sup>1</sup>,  
Farideh Nejat<sup>1</sup>

*Department of Neurosurgery, Shariati Hospital, Tehran University of Medical Science, 'Department of Neurosurgery, Children's Hospital Medical Center, Tehran University of Medical Science, Tehran, Iran*

## Address for correspondence:

Dr. Farideh Nejat,  
Department of Neurosurgery,  
Children's Hospital Medical  
Center, Gharib Street, Postal  
Code 141557854, Tehran, Iran.  
E-mail: nejat@sina.tums.ac.ir

## Access this article online

Website: [www.asianjns.org](http://www.asianjns.org)

DOI: 10.4103/ajns.AJNS\_63\_17

## Quick Response Code:



This is an open access journal, and articles are distributed under the terms of the Creative Commons Attribution-NonCommercial-ShareAlike 4.0 License, which allows others to remix, tweak, and build upon the work non-commercially, as long as appropriate credit is given and the new creations are licensed under the identical terms.

For reprints contact: [reprints@medknow.com](mailto:reprints@medknow.com)

of choroid plexus cauterization (CPC) may cause ETV failure, and VP shunt would be indicated.<sup>[4,9-11]</sup> Besides, the opening status of aqueduct and scarring of prepontine cistern was reported as predictors for ETV success as well.<sup>[11,12]</sup> Moreover, ETV may pose potential complications such as intraoperative bleeding, diabetes insipidus, cranial nerve palsy, precocious puberty, abnormal weight gain, and reoperation indication.<sup>[5-8]</sup>

Despite the impressive advances in neurosurgical techniques, decision-making on the most efficient treatment for HCP, especially the first-line surgical intervention, is still controversial seeing the failure rate and complications of each approach. Considering the lack of powerful evidence, the current clinical trial was conducted to determine the efficacy of VP shunt and ETV/CPC for the treatment of obstructive HCP in infants.

## Methods

This randomized controlled trial (RCT) was approved by the Ethics Committee of Tehran University of Medical Sciences and was registered at Iranian Registry of Clinical Trials <http://www.irct.ir/>. (Irct ID: IRCT2014020416483N1).

### Trial design

After approving by the Institutional Ethical Committee of Tehran University of Medical Sciences, this study was designed as a single-center, unblind, two-arm, active control, parallel group, with 1:1 allocation ratio to compare therapeutic efficacy of ETV/CPC versus VP shunt in infants with obstructive HCP.

### Eligibility criteria

Pediatric patients with HCP who were admitted to Children's Medical Center between 2012 and 2015 were screened for eligibility to enter the clinical trial. The patients under 12 months with obstructive HCP confirmed by magnetic resonance imaging, whose parents or legal guardian signed informed consent form, were included in this study. The patients were cases of pure obstruction of either the third or fourth ventricles, without any communicating component. The patients over 1 year, those with communicating components, or previous surgical intervention for HCP management were excluded from the study.

### Interventions

The patients were randomly divided into two intervention groups as described below:

#### *Ventriculoperitoneal shunt*

VP shunt was done through the standardized protocol of our center in the supine position with head turned to the left through Keen's and subcostal incisions. Ventricular catheter was inserted in the standard way, and peritoneal catheter was prepared and put inside the abdominal cavity with enough length.

#### *Endoscopic third ventriculostomy/choroid plexus cauterization*

A curved incision in the right lateral corner of the anterior fontanel and minicraniotomy<sup>[13]</sup> centered on the midpupillary line was made. The rigid endoscope was inserted into the right frontal horn and third ventricle. The floor of the 3<sup>rd</sup> ventricle was penetrated and dilated with Fogarty balloon and then Liliequist membrane was fenestrated.

After completion of ETV, the CPC procedure was started from the choroid plexus of right lateral ventricle posterior to foramen of Monro toward glomus choroideum in the atrium up to the temporal horn. After CPC at the right side, the scope was aimed to the left lateral ventricle through wide fenestration of the septum pellucidum. Nonetheless, due to using rigid endoscope, at best, <70% of choroid plexus of each side could be cauterized.

## Outcomes

### *Primary outcomes*

The primary outcome measures included abnormal increase in head circumference and any sign or symptom of rICP including bulged fontanel, sunset eye, vomiting, cranial nerve palsy, and dilated ventricles within 6 months after intervention, which was assessed through physical examination and imaging.

### *Secondary outcomes*

The secondary outcome measures included CSF leakage, CSF collection, wound dehiscence, temporary rICP, ETV reoperation, further VP shunt (for ETV group), requiring external ventricular drainage (EVD), infection, shunt hardware failure, shunt exposure, abdominal pseudocyst, meningitis, and subdural hematoma. The outcomes were measured through physical examination and imaging whenever necessary.

The absence of permanent rICP signs was considered as positive response to treatment in both groups. In case of intervention failure in ETV group, the patient would undergo either repeated ETV or VP shunt insertion. In case of VP shunt complication, the classic treatment would be administered which included ETV or shunt revision in cases with obstruction and shunt removal plus with antibiotic therapy in cases with infection. For cases with temporary rICP, EVD, serial lumbar puncture, or ventricular tap was considered as rICP management approaches.

### **Sample size and randomization**

A sample size of 96 achieved 91% power to detect a noninferiority ratio (P0/baseline proportion [PB]) of 0.7000 using a one-sided binomial test for noninferiority. The target significance level was 0.0500. These results assumed a PB of 0.5000 and that the actual ratio (P1/PB) is 1.0000. As it is a preliminary report of an ongoing trial, the results

for fifty cases were analyzed. Accordingly, the sample size of fifty would achieve 66% power in this condition.<sup>[14,15]</sup> The computer-based randomization method was used for sequence generation, and random allocation was based on patient's admission order. Then, the sequences were separately stored in opaque pockets, which were inaccessible until randomization time. It was an unblind trial as the presence of VP shunt prevented postoperative blinding of patients or assessors.

### Statistical analysis

Qualitative variables as sex distribution and underlying disease were reported as proportion (percentage). Quantitative variables as age were reported as mean  $\pm$  standard deviation. The association between two qualitative variables as intervention group and outcome was tested with Chi-square test, and  $P = 0.05$  or less was considered statistically significant. The Kaplan–Meier curve was used to compare the 36-month success of ETV/CPC and VP shunt groups.

### Results

It is a preliminary report of an RCT considered for 100 infants with obstructive HCP.

#### Patients' characteristics

In the 3-year study period, a total number of 207 pediatric patients with HCP were screened for eligibility criteria. Of 56 clinically eligible patients, after clear explanation of benefits and harms of each treatment and that none of the treatments would be completely out of adverse events and also the patients will receive full medical/surgical care in case of any complication, only 6 parents refused to sign informed consent form and therefore were excluded from the study. The excluded patients were not clinically different from the other eligible patients [Figure 1]. Of the total 50 patients recruited in the 3-year interval, 17 patients (34%) were female and 33 (66%) were male with the mean age of  $3.74 \pm 3.1$  months (range = 10 days – 11 months). A larger proportion of patients, 39 (79.6%), were under 6 months of age and the remaining were 6 months or older. Twenty-seven patients (54%) were randomly allocated to VP shunt group and 22 (46%) were in ETV/CPC group. One patient was operated as ETV only because CPC was impossible due to lack of obvious choroid plexus at its normal anatomical site and therefore was excluded from the study. The distribution difference (for age, sex, and etiology) between intervention groups was not significant ( $P > 0.05$ ) [Table 1].

#### The association between success rate and intervention group

Of the total 22 patients in ETV/CPC group, response to treatment was observed in 15 patients comprising about 68.2% of ETV/CPC group. The other seven (31.8%) patients in ETV/CPC group, however, developed signs

of permanent rICP, five of them underwent ETV/CPC reoperation and two of them underwent VP shunt insertion. All seven patients were fine in further follow-up. In the VP shunt group, on the other hand, the response rate was 88.9%, which was observed in 24/27 of patients in this group. Three patients in VP shunt group had shunt complications, and therefore, the failure rate in this group was 11.1%. Two of these three patients had shunt infection, managed with shunt removal, antibiotic therapy according to antibiogram but were deceased in the follow-up period. The other patient with rICP signs was managed through ETV/CPC operation, showing a successful response within 11-month follow-up. However, the difference in the rate of response to treatment between two groups was not statistically significant ( $P = 0.09$ ).

In the whole follow-up period, two patients were deceased who were both in VP shunt group. One was a 2-month boy, known case of aqueduct stenosis who developed shunt infection and severe unresponsive sepsis leading to death within a few days of antibiotic treatment. The second was a 7-month boy with obstructive HCP and VP shunt who found inguinal hernia, which was surgically managed in another center. One week later, he was admitted in our hospital with high-grade fever. His evaluation confirmed positive blood culture for *Escherichia coli*, ascites and shunt infection with *E. coli*. The management with shunt removal and antibiotic therapy was unsuccessful and he died in 5 days due to severe sepsis.

#### The association between intervention success and age group

The overall success rate in both age groups were high with slightly higher rate in those over the age of 6 months (82.1% vs. 70%), which was not statistically significant; moreover, 6 of 7 patients with ETV/CPC failure and 1 of 3 patients with VP shunt failure were under 6 months which were not significant either. These results might be due to a higher proportion of patients younger than 6 months in our small sample size.

#### Intervention complications

In the VP shunt group, two patients had abnormal intraoperative bleeding resulted in anemia which was managed with irrigation and blood transfusion (they were young infants with abnormal dura mater venous system with venous lake under the burr hole which caused severe bleeding at the time of dural perforation). On the other hand, in ETV/CPC group, three patients experienced hypernatremia who were managed conservatively. The first case had sodium value increasing from 130 to 170, the second one from 129 to 137, and the last one from 130 to 147. Low urine specific gravity was detected in all of these three patients.

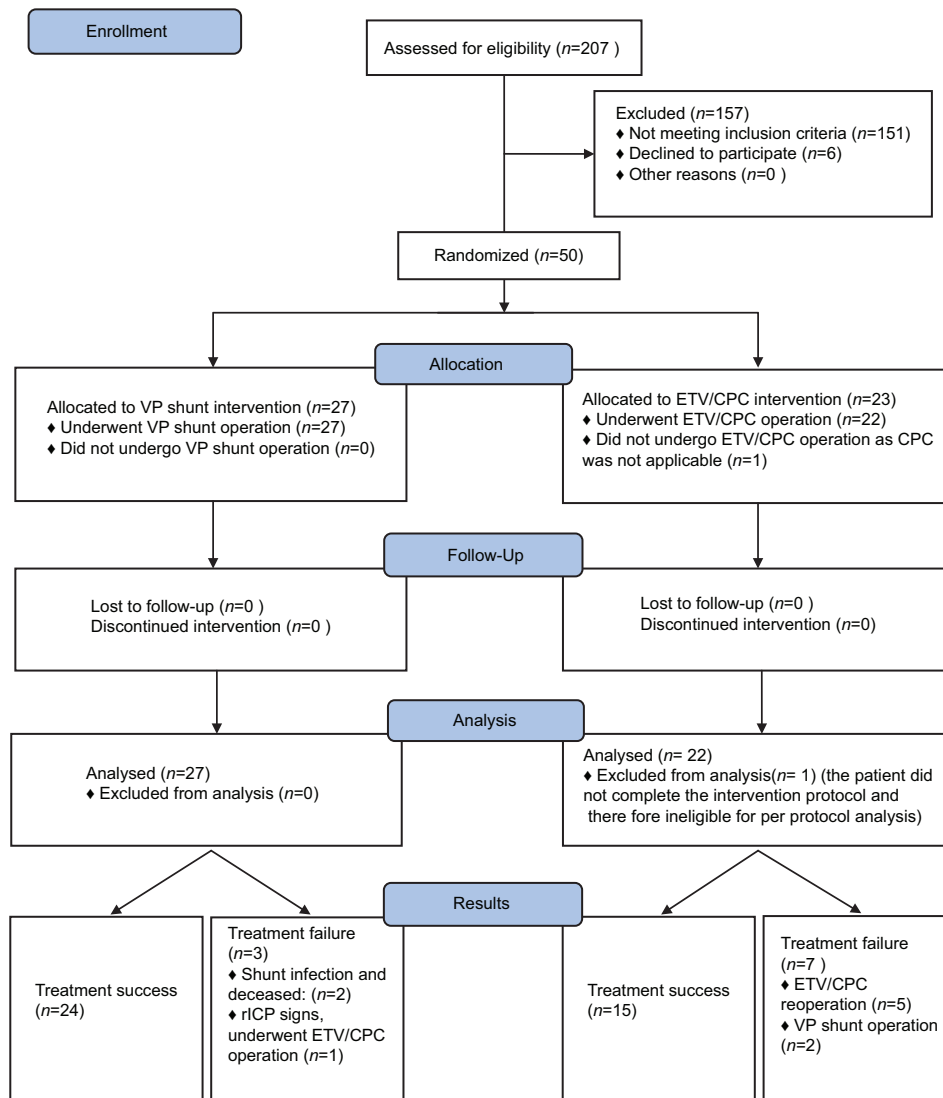


Figure 1: Endoscopic third ventriculostomy/choroid plexus cauterization versus ventriculoperitoneal shunt patients' recruitment diagram at a glance

### Endoscopic third ventriculostomy/choroid plexus cauterization and ventriculoperitoneal shunt survival curve

The 36-month success rate was 88.5% and 68.2% in VP shunt and ETV/CPC groups, respectively. The estimated survival was detected 31.93 and 25.13 months for VP shunt and ETV/CPC which was not statistically different ( $P = 0.108$ ) [Figure 2].

### Discussion

In the current study, the results of a prospective RCT to compare the therapeutic efficacy of VP shunt and ETV/CPC in infants with obstructive HCP were reported.

The ETV is affirmed as an effective surgical treatment for noncommunicating HCP. However, there are some obstacles for ETV success in young patients, especially in the first 12 months of life.<sup>[9,16]</sup> Several theories were proposed to explain the higher ETV failure rate in infants.

The insufficient CSF absorption by arachnoid villi in young ages would result in early onset ETV failure despite active CSF flow and then HCP would remain.<sup>[9,10]</sup> On the other hand, obstruction of the fenestrated stoma might be another potential cause for ETV failure. This obstruction might be the result of either gliosis or arachnoid membrane formation which is more common in infants. The opening status of aqueduct as well as scarring of prepontine cistern would be also effective in determining ETV success.<sup>[11,12]</sup> While scarred prepontine cistern was associated with approximately two times higher ETV failure rate, the obstructed aqueduct was associated with higher ETV success rate.<sup>[12]</sup> Besides, the underlying cause of HCP might be another determinant of ETV success as the best ETV success was reported in infants with congenital Aqueductal stenosis.<sup>[16-18]</sup>

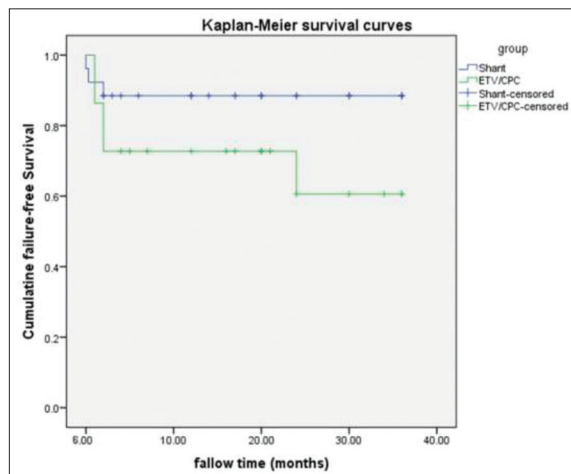
The mean ETV success score (ETVSS) of the current study was  $49.23 \pm 17.10\%$ , which was slightly lower than the actual 36-month ETV success of 68%, which could



**Table 1: Epidemiologic data of patients assigned in the clinical trial of endoscopic third ventriculostomy/choroid plexus cauterization and shunt in infants with obstructive hydrocephalus**

Variable	Total (n=49)	ETV/CPC (n=22)	VP shunt (n=27)	P
Age (mean±SD, months) (range)	3.74±3.1 (0.3-11)	3.91±3.34	3.60±2.95	0.73
Age (months) (%)				
<6	39 (79.6)	17 (77.3)	22 (81.5)	0.73
>6	10 (20.4)	5 (22.7)	5 (18.5)	
Sex (%)				
Female	17 (34.7)	9 (40.9)	8 (29.6)	0.54
Male	32 (65.3)	13 (59.1)	19 (70.4)	
ETVSS (mean±SD)	-	49.04±14.70 (10-70)	-	-
Mortality (%)	2 (4.1)	0	2 (4.1)	
Response to treatment (%)				
Success	39 (79.6)	15 (68.2)	24 (88.9)	0.09
Failure	10 (20.4)	7 (31.8)	3 (11.3)	
Follow-up (mean±SD), months	16.25±12.26 (0-36)	15.22±12.21	17.12±12.47	0.59

ETVSS – Endoscopic third ventriculostomy success score; SD – Standard deviation; ETV – Endoscopic third ventriculostomy; CPC – Choroid plexus cauterization; VP – Ventriculoperitoneal



**Figure 2: Kaplan–Meier curve for endoscopic third ventriculostomy and ventriculoperitoneal shunt success**

be explained as the larger proportion of patients under 6 months. In general, the ETV success rate in our study is compatible with other studies reporting success rate of about 58%–75% in young children.<sup>[19-23]</sup> Besides, in almost all of reported studies, the ETVSS was proposed as a suitable predictor for short- and long-term success rate of ETV.<sup>[19-22,24]</sup>

Concomitant use of ETV/CPC was established to enhance the efficacy and therefore success rate of intervention.<sup>[25-27]</sup> Considering the insufficient CSF absorption in infants, the CPC can enhance the success rate of ETV through decreasing the CSF production. The ETV/CPC was reported to increase the success rate from 48.6% to 81.9% compared to ETV alone in infants.<sup>[25]</sup> In another study, the combination of CPC increased the ETV success rate from 46% to 66% as well.<sup>[28]</sup> The combination of ETV/CPC was also reported to have success rate of about 52%–66% elsewhere.<sup>[26-28]</sup> Moreover, the extent of CPC was

determinative in the overall success as the higher success in cauterization of 90% of choroid plexus or more was achieved.<sup>[27]</sup> However, the shortcoming of using a rigid scope must be more stressed in infants, especially as the bulk of the choroid is inside the temporal horn in this age, and no more than 70% of choroid plexus of each side can be cauterized using rigid device. In the current study, the overall success rate was 88.5% and 68.2% in VP shunt and ETV/CPC, respectively, which was not remarkably different. In addition, the ETV was used concomitantly with CPC to improve the efficacy of treatment. Therefore, ETV/CPC might be considered as a safe alternative for VP shunt in cases with obstructive HCP although careful monitoring is mandatory in the 1<sup>st</sup> month postoperation.

A very recent RCT reported 36-month survival of 64.1% and 79.1% for ETV and VP shunt, respectively,<sup>[29]</sup> which were compatible with success rates in our study. However, in contrast to current results, this difference was found significant which might be due to the respective larger sample size. On the other hand, in the current study, we concomitantly used ETV with CPC which was different from the therapeutic approach in the previous RCT using ETV alone.<sup>[29]</sup>

In this single-center trial, all the surgical procedures were performed by an experienced neurosurgeon, and the outcomes were assessed by another neurosurgeon, which increased the internal validity of the study. The small sample size was an important limitation of the current study, but this study is an ongoing study, and a much larger sample size will be considered in the near future to detect the true effect of each intervention.

### Conclusion

The concomitant use of ETV with CPC could be considered as one of the first-line surgical approaches for the treatment

of obstructive HCP in infants due to the lower risk of infection or some other complications. In cases of ETV/CPC failure, re-ETV or VP shunt could be considered as the second-line surgical approaches dependent on the patient's condition.

#### Financial support and sponsorship

Nil.

#### Conflicts of interest

There are no conflicts of interest.

#### References

- Persson EK, Anderson S, Wiklund LM, Uvebrant P. Hydrocephalus in children born in 1999-2002: Epidemiology, outcome and ophthalmological findings. *Childs Nerv Syst* 2007;23:1111-8.
- Drake JM, Kestle JR, Milner R, Cinalli G, Boop F, Piatt J Jr, *et al.* Randomized trial of cerebrospinal fluid shunt valve design in pediatric hydrocephalus. *Neurosurgery* 1998;43:294-303.
- Neils DM, Wang H, Lin J. Endoscopic third ventriculostomy for shunt malfunction: What to do with the shunt? *Surg Neurol Int* 2013;4:3.
- Drake JM, Canadian Pediatric Neurosurgery Study Group. Endoscopic third ventriculostomy in pediatric patients: The Canadian experience. *Neurosurgery* 2007;60:881-6.
- Cinalli G, Salazar C, Mallucci C, Yada JZ, Zerah M, Sainte-Rose C. The role of endoscopic third ventriculostomy in the management of shunt malfunction. *Neurosurgery* 1998;43:1323-7.
- Hader WJ, Walker RL, Myles ST, Hamilton M. Complications of endoscopic third ventriculostomy in previously shunted patients. *Neurosurgery* 2008;63 1 Suppl 1:ONS168-74.
- Jenkinson MD, Hayhurst C, Al-Jumaily M, Kandasamy J, Clark S, Mallucci CL. The role of endoscopic third ventriculostomy in adult patients with hydrocephalus. *J Neurosurg* 2009;110:861-6.
- O'Brien DF, Javadpour M, Collins DR, Spennato P, Mallucci CL. Endoscopic third ventriculostomy: An outcome analysis of primary cases and procedures performed after ventriculoperitoneal shunt malfunction. *J Neurosurg* 2005;103 5 Suppl: 393-400.
- Wagner W, Koch D. Mechanisms of failure after endoscopic third ventriculostomy in young infants. *J Neurosurg* 2005;103 1 Suppl: 43-9.
- Koch D, Wagner W. Endoscopic third ventriculostomy in infants of less than 1 year of age: Which factors influence the outcome? *Childs Nerv Syst* 2004;20:405-11.
- Warf BC; East African Neurosurgical Research Collaboration. Pediatric hydrocephalus in East Africa: Prevalence, causes, treatments, and strategies for the future. *World Neurosurg* 2010;73:296-300.
- Warf BC, Kulkarni AV. Intraoperative assessment of cerebral aqueduct patency and cisternal scarring: Impact on success of endoscopic third ventriculostomy in 403 African children. *J Neurosurg Pediatr* 2010;5:204-9.
- Arjipour M, Hanaei S, Habibi Z, Esmaeili A, Nejat F, El Khashab M. Small size craniotomy in endoscopic procedures: Technique and advantages. *J Pediatr Neurosci* 2015;10:1-4.
- Blackwelder WC. Equivalence trials. *Encyclopedia of Biostatistics*. New York: Biostatistics; John Wiley and Sons; 1998.
- Chow SC, Wang H, Shao J. Sample Size Calculations in Clinical Research. New York: Basel CRC, Research Marcel Dekker Inc; 2007.
- Javadpour M, Mallucci C, Brodbelt A, Golash A, May P. The impact of endoscopic third ventriculostomy on the management of newly diagnosed hydrocephalus in infants. *Pediatr Neurosurg* 2001;35:131-5.
- Joedicke A, Boschert J, Wagner W, Hedderich J. Hydrocephalus 2005 International Consensus Meeting, Queenstown, New Zealand, 15-17 August 2005. *Childs Nerv Syst* 2005;21:591-601.
- Balthasar AJ, Kort H, Cornips EM, Beuls EA, Weber JW, Vles JS. Analysis of the success and failure of endoscopic third ventriculostomy in infants less than 1 year of age. *Childs Nerv Syst* 2007;23:151-5.
- Naftel RP, Reed GT, Kulkarni AV, Wellons JC. Evaluating the children's hospital of Alabama endoscopic third ventriculostomy experience using the endoscopic third ventriculostomy success score: An external validation study. *J Neurosurg Pediatr* 2011;8:494-501.
- Kulkarni AV, Riva-Cambrin J, Browd SR. Use of the ETV success score to explain the variation in reported endoscopic third ventriculostomy success rates among published case series of childhood hydrocephalus. *J Neurosurg Pediatr* 2011;7:143-6.
- García LG, López BR, Botella GI, Páez MD, da Rosa SP, Rius F, *et al.* Endoscopic Third Ventriculostomy Success Score (ETVSS) predicting success in a series of 50 pediatric patients. Are the outcomes of our patients predictable? *Childs Nerv Syst* 2012;28:1157-62.
- Durnford AJ, Kirkham FJ, Mathad N, Sparrow OC. Endoscopic third ventriculostomy in the treatment of childhood hydrocephalus: Validation of a success score that predicts long-term outcome. *J Neurosurg Pediatr* 2011;8:489-93.
- Vogel TW, Bahuleyan B, Robinson S, Cohen AR. The role of endoscopic third ventriculostomy in the treatment of hydrocephalus. *J Neurosurg Pediatr* 2013;12:54-61.
- Kulkarni AV, Riva-Cambrin J, Holubkov R, Browd SR, Cochrane DD, Drake JM, *et al.* Endoscopic third ventriculostomy in children: Prospective, multicenter results from the Hydrocephalus Clinical Research Network. *J Neurosurg Pediatr* 2016;18:423-9.
- Warf BC, Tracy S, Mugamba J. Long-term outcome for endoscopic third ventriculostomy alone or in combination with choroid plexus cauterization for congenital aqueductal stenosis in African infants. *J Neurosurg Pediatr* 2012;10:108-11.
- Stone SS, Warf BC. Combined endoscopic third ventriculostomy and choroid plexus cauterization as primary treatment for infant hydrocephalus: A prospective North American series. *J Neurosurg Pediatr* 2014;14:439-46.
- Kulkarni AV, Riva-Cambrin J, Browd SR, Drake JM, Holubkov R, Kestle JR, *et al.* Endoscopic third ventriculostomy and choroid plexus cauterization in infants with hydrocephalus: A retrospective Hydrocephalus Clinical Research Network study. *J Neurosurg Pediatr* 2014;14:224-9.
- Warf BC. Comparison of endoscopic third ventriculostomy alone and combined with choroid plexus cauterization in infants younger than 1 year of age: A prospective study in 550 African children. *J Neurosurg* 2005;103 6 Suppl: 475-81.
- Kulkarni AV, Sgouros S, Constantini S; IIHS Investigators. International Infant Hydrocephalus Study: Initial results of a prospective, multicenter comparison of endoscopic third ventriculostomy (ETV) and shunt for infant hydrocephalus. *Childs Nerv Syst* 2016;32:1039-48.