

## Secondary Arachnoid Cyst – A Late Complication of Craniotomy: A Case Report and Review of Literature

### Abstract

Arachnoid cyst can be defined as cerebral-spinal fluid entrapment within the central nervous system. It may occur primarily as a congenital malformation or secondary as a complication following trauma, infection, bleeding, or surgical manipulation. Congenital arachnoid cyst usually asymptomatic and cause no pressure symptoms. No treatment is needed unless size increase and cause pressure symptoms and increased intracranial pressure. We report a case presented to the hospital with neurological signs of increased intracranial pressure, 3 years Post aborted craniotomy for meningioma resection. Radiological imaging showed postoperative newly developed arachnoid cyst with mass effect. He underwent the urgent cerebral spinal fluid diversionary procedure with cystoperitoneal shunt.

**Keywords:** Arachnoid cyst, complication, congenital, craniotomy, secondary

**Mostafa Osman,  
Ahmed Diraz**

*Department Of Neurosurgery,  
Dr. Soliman Fakeeh Hospital,  
Jeddah, Saudi Arabia*

### Introduction

Arachnoid cysts are classified as developmental cysts; they were first described in 1831.<sup>[1]</sup> These cysts lie between 2 membranes of normal arachnoid matter and are more properly described as intra-arachnoid cysts.<sup>[2]</sup> Congenital or developmental arachnoid cysts differ from secondary or acquired arachnoid cysts, as the latter are loculations of cerebral spinal fluid (CSF) surrounded by arachnoid scarring.<sup>[3]</sup>

Most commonly, they are found within the middle cranial fossa with an incidence of 42% followed by retrocerebellar and convexity locations. About 60%–90% of all patients with developmental arachnoid cysts are children with a male-to-female predominance of approximately 2:1.<sup>[4]</sup>

### Case Report

We report a case of 39-year-old gentleman presented to the emergency room (ER) with acute onset headache of 3 weeks' duration complicated with vomiting and fits. He had a surgical history of previous incomplete resection of right medial sphenoid wing meningioma, 3 years ago. Surgery report justified incomplete resection due to intraoperative severe hypotension.

Clinically, the patient was conscious. He had complete right 3<sup>rd</sup> nerve palsy with optic atrophy and no perception of light with associated corneal opacity developed after the previous surgery as quoted by patient and relatives. He can count fingers by the left eye, and there is severe papilledema on the left side.

Computed tomography (CT) brain and then magnetic resonance imaging (MRI) brain with contrast showed right-sided big temporal cyst with severe mass effect and impending uncal herniation associated with increasing size of the right medial sphenoid wing Space occupying lesion [Figure 1].

The patient was admitted from ER and received dexamethasone and loading dose of phenytoin and then maintenance dose. After patient stabilized, it was decided to treat the symptomatizing big right temporal cyst by cystoperitoneal shunt as a first stage [Figure 2]. The cyst seems to be progressively enlarging postoperative acquired arachnoid cyst as evidenced on F/U MRI brain study; preoperative [Figure 3] and postoperative. Pathological examination of cyst fluid ruled-out malignant or inflammatory cells [Figure 4].

Later on, the patient needs surgical intervention for debulking of the medial sphenoid meningioma with or without radiosurgery if needed.

**Address for correspondence:**  
Dr. Mostafa Osman,  
Dr. Soliman Fakeeh Hospital,  
Jeddah, Saudi Arabia.  
E-mail: drmostafaosman@gmail.com

#### Access this article online

**Website:** www.asianjns.org

**DOI:** 10.4103/ajns.AJNS\_68\_18

#### Quick Response Code:



**How to cite this article:** Osman M, Diraz A. Secondary arachnoid cyst – A late complication of craniotomy: A case report and review of literature. Asian J Neurosurg 2018;13:1273-5.

This is an open access journal, and articles are distributed under the terms of the Creative Commons Attribution-NonCommercial-ShareAlike 4.0 License, which allows others to remix, tweak, and build upon the work non-commercially, as long as appropriate credit is given and the new creations are licensed under the identical terms.

**For reprints contact:** reprints@medknow.com

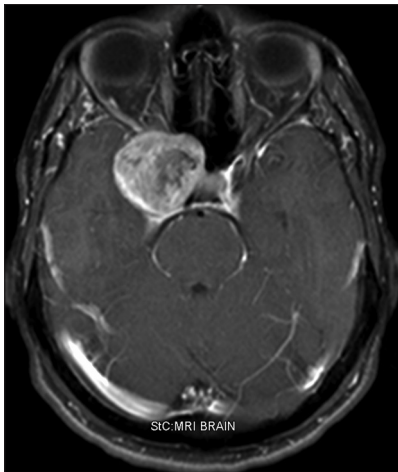

Figure 1: Axial magnetic resonance imaging brain with contrast before the first surgery, showing extra-axial heterogenous mass (meningioma) is seen in the right para-sellar region

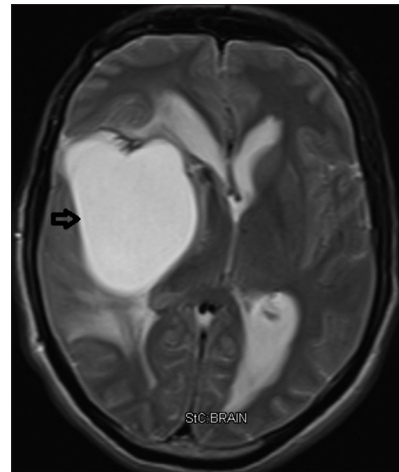


Figure 2: MRI Brain with contrast, 3 years after the first surgery, showing interval development of large cyst (black arrow), causing mass effect with midline shift

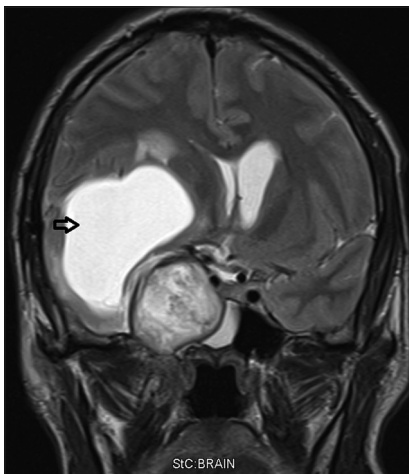


Figure 3: Coronal magnetic resonance imaging brain with contrast showing extra-axial heterogenous mass in the right parasellar region bounded medially by the internal carotid artery and cavernous sinus, Superiorly by the middle cerebral artery laterally by the temporal lobe and a newly formed cyst (arrow) in the previously dissected surgical corridor.

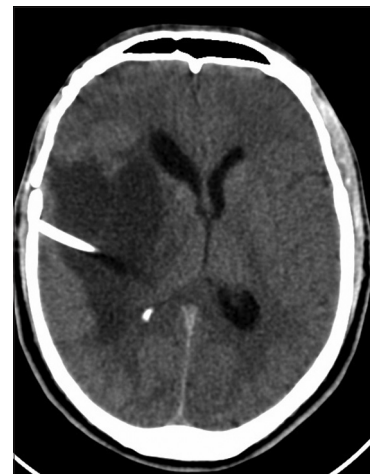

Figure 4: Axial CT Brain showing Interval insertion of the right-sided ventriculoperitoneal shunt with mild interval improvement in the hydrocephalus and midline shift Stable amount of surrounding vasogenic edema with decrease in the size of cystic

## Discussion

Arachnoid cysts are extra-axial, nonneoplastic CSF collection, localized to the arachnoid membrane within the central nervous system. Arachnoid cysts may be spinal, or intracranial (most common locations are the middle fossa), the suprasellar region (near the third ventricle) and the posterior fossa, where they may be associated with headache and seizures, with focal neurologic signs occurring less frequently.<sup>[5]</sup>

Secondary type of arachnoid cyst occurs as a sequel of arachnoidal tissue injury following direct irritation of the arachnoid matter by the inflammatory mediators; whether endogenous from the blood product or exogenous endotoxins from bacterial infections, come in contact with the leptomeninges. Adhesive arachnoiditis with CSF accumulation through a slit-valve mechanism with no

exchange with CSF circulation leads to cyst formation. Sometimes, cyst size increases with time causing pressure symptoms and marked increase in the intracranial pressure.<sup>[6]</sup>

They usually follow CSF density and intensity in CT and MRI, respectively. They do not enhance with contrast. Diffusion-weighted imaging fails to reveal restriction of water diffusion, which helps differentiate arachnoid cysts from epidermoid tumors.<sup>[7]</sup>

Grossly, arachnoid cysts have thin translucent to thicker, more opaque membranes. The cyst contents are composed of clear fluid, with occasional xanthochromic discoloration if there has been prior hemorrhage.<sup>[4]</sup>

However, it has been hypothesized that these cysts may also occur after events that produce an inflammatory process in the arachnoid membranes, such as surgical

manipulation and the presence of blood in the subarachnoid space. This leptomeningeal inflammation may result in adhesive arachnoiditis with impairment of CSF dynamics, circulation, and CSF loculation.<sup>[8]</sup>

Fujimura *et al.*<sup>[9]</sup> reported a case of visual disturbance due to optochiasmal arachnoiditis and foreign body granuloma 9 months after surgery for aneurysm in which cotton wrapping was used. The authors recommended the avoidance of the use of the cotton sheet close to the optic nerve. This foreign material may induce a granulomatous reaction known as a “muslinoma” or “gauzoma” (Muslin-induced arachnoiditis). Many cases reported following bleeding issues, whether post coiled ruptured aneurysm or post evacuation of subdural bleeding raise the possibility of arachnoid matter irritation from direct contact with blood product.<sup>[10,11]</sup>

In patients with symptomatic arachnoid cysts, treatment may lead to relief of focal neurological deficits; treatment modalities involve endoscopic or open fenestration and shunt placement.<sup>[12]</sup>

## Conclusion

However, arachnoiditis seems to be unavoidable issue, meticulous deal with the arachnoid matter with trial of bloodless field would decrease the possibility of such a problem.

## Financial support and sponsorship

Nil.

## Conflicts of interest

There are no conflicts of interest.

## References

- Bright R. Serous cysts in the arachnoid. Reports of Medical Cases Selected with a View of Illustrating the Symptoms and Cure of Diseases by a Reference to Morbid Anatomy: Diseases of the Brain and Nervous System. Part I. Vol. 2. Highley, London: Longman; 1831. p. 437-9.
- Starkman SP, Brown TC, Linell SA. Cerebral arachnoid cysts. *J Neuropathol Exp Neurol* 1958;17:484-500.
- Schwarz E. Syphilitische myelomeningitis mit hollenbildung in ruchenmarke and besodneren degenerativen eranderum. (Preparations of a case of syphilitic myelomeningitis with fouling and special Degeneration.) *Wien Klin Wochenschr* 1897;10:177.
- Fuller GN, Perry A. Epithelial, neuroendocrine, and metastatic lesions. In: *Practical Surgical Neuropathology: A Diagnostic Approach*. Churchill Livingstone Elsevier, Philadelphia, PA : 2010. p. 287-313.
- Pradilla G, Jallo G. Arachnoid cysts: Case series and review of the literature. *Neurosurg Focus* 2007;22:E7.
- Smith S. Adhesive Arachnoiditis. Knowsley (UK), USA, New Zealand, Australia: COFWA, ASAMS, CIAASA, Patron of the Arachnoiditis Support Group; 2003.
- Omay SB, Baehring JM. Nonneoplastic mass lesions of the central nervous system. In: *Handbook of Neuro-Oncology Neuroimaging*. 2<sup>nd</sup> ed., Academic Press; 2016. p. 653-665.
- Kouyialis AT, Stranjalis G, Boviatsis EJ, Ziaka DS, Bouras TI, Sakas DE, *et al.* Recurrence of trigeminal neuralgia due to an acquired arachnoid cyst. *J Clin Neurosci* 2008;15:1409-11.
- Fujimura M, Nishijima M, Umezawa K, Hayashi T, Mino Y, Sakuraba T, *et al.* Optochiasmal arachnoiditis following cotton wrapping of anterior communicating artery aneurysm treated by surgical removal of granuloma. *J Clin Neurosci* 2003;10:254-7.
- Marcoux J, Roy D, Bojanowski MW. Acquired arachnoid cyst after a coil-ruptured aneurysm. Case illustration. *J Neurosurg* 2002;97:722.
- Sonnet MH, Joud A, Marchal JC, Klein O. Suprasellar arachnoid cyst after subdural haemorrhage in an infant. A case based update. *Neurochirurgie* 2014;60:55-8.
- Johnson A, Ryan MD, Roche J. Depo-medrol and myelographic arachnoiditis. *Med J Aust* 1991;155:18-20.