

Evaluation of crestal bone resorption around cylindrical and conical implants following 6 months of loading: A randomized clinical trial

Naser Sargolzaie¹, Hamid Reza Arab¹, Marzieh Mohammadi Moghaddam¹

Correspondence: Dr. Marzieh Mohammadi Moghaddam,
Email: mohamadi_moghaddam@yahoo.com

¹Department of Periodontology, Faculty of Dentistry,
Mashhad University of Medical Sciences, Mashhad,
Iran

ABSTRACT

Objective: The purpose of this clinical study was to evaluate the effect of implant body form (cylindrical and conical implants) on crestal bone levels during 6 months' follow-up after loading. **Materials and Methods:** A total of 32 SPI implants (19 conical implants/13 cylindrical implants) were randomly placed in 12 male patients using a submerged approach. None of the patients had compromising medical conditions or parafunctional habits. Periapical radiographs using the parallel technique were taken after clinical loading and 6 months later. Clinical indices including pocket depth and bleeding on probing (BOP) were recorded on 6-month follow-up. Data were analyzed by independent samples *t*-test and Chi-square test with a significance level of 0.05. **Results:** Six months after loading, crestal bone loss was 0.84 (± 0.29) mm around the cylindrical implants and 0.73 (± 0.62) mm around the conical types, which was not significantly different ($P = 0.54$). Pocket depth around the cylindrical and conical implants was 2.61 (± 0.45) mm and 2.36 (± 0.44) mm, respectively ($P = 0.13$). BOP was observed among 53.8% and 47.4% of the cylindrical implants and conical ($P = 0.13$). Bone loss and pocket depth in the maxilla and mandible had no significant difference ($P = 0.46$ and $P = 0.09$, respectively). **Conclusion:** In this study, although bone loss and clinical parameters were slightly higher in the cylindrical implants, there was no significant difference between the conical- and cylindrical-shaped implants.

Key words: Alveolar bone loss, conical implant, cylindrical implant, dental implants

INTRODUCTION

Tooth loss could cause unaesthetic appearance and may deteriorate mastication and speech. Nowadays, dental implants are common treatment modality for restoring missing or extracted teeth. The aim of implant therapy in dentistry is to restore tissue contour, function, comfort, esthetic, and speech. Dental implants are the only treatment that can reach these goals without causing alveolar bone loss.^[1,2] However, marginal bone loss is a common complication of dental implants.^[3,4]

It has been demonstrated that dental implant osseointegration could be achieved when implants are placed in correct position using atraumatic surgical approach.^[5] Implants should have primary stability, and most of the times need a healing period before loading.^[6]

Previous studies have reported acceptable amount of alveolar bone loss in the 1st year should be <1 mm.^[7,8]

This is an open access article distributed under the terms of the Creative Commons Attribution-NonCommercial-ShareAlike 3.0 License, which allows others to remix, tweak, and build upon the work non-commercially, as long as the author is credited and the new creations are licensed under the identical terms.

For reprints contact: reprints@medknow.com

How to cite this article: Sargolzaie N, Arab HR, Moghaddam MM. Evaluation of crestal bone resorption around cylindrical and conical implants following 6 months of loading: A randomized clinical trial. Eur J Dent 2017;11:317-22.

DOI: 10.4103/ejd.ejd_38_17

Access this article online	
Quick Response Code: 	Website: www.eurjdent.com

Several attempts have been done to prevent alveolar bone loss and increase dental implant success rate. These attempts include implant surface modification (acid etch, sandblast, and hydroxyapatite coating),^[9] implant geometry alteration (conical and cylindrical fixtures),^[10] and changing in implant threads (type, shape, and depth of threads).^[1,11]

Several studies have investigated the effect of implant design on survival and success rate of implant therapy.^[12-21] Among them, some have compared conical and cylindrical implants.^[15-21] Comparison of the success rate of conical implants versus cylindrical implants in some studies showed that there was no significant difference.^[16-20] However, other studies showed that their cylindrical implants might be more successful.^[15,21]

Regarding the lack of clinical evidence in this matter, the aim of the current study was to compare crestal bone loss, pocket depth, and bleeding on probing between conical and cylindrical dental implants at a 6-month period.

MATERIALS AND METHODS

Patients

This randomized clinical study was performed prospectively during 2014–2015 in a private implant therapy clinic in Mashhad, west of the Iran. Informed consent was taken from the included patients, and study protocol was approved by Ethical Committee of Mashhad University of Medical Sciences. In addition, no alteration to the conventional implant therapy protocol was done. A total of 43 SPI dental implants (SPI®, Thommen Medical AG, Waldenburg, Switzerland) were inserted in alveolar bone of 19 patients.

Inclusion criteria were male patients who with the American Society of Anesthesiologists I and II (good health condition) who needed single implant placement in posterior regions (patients who needed single implants in separate sites were also included). Furthermore, at least 2 mm of the attached gingiva should have been present at implant site. Patients with a history of systemic diseases and conditions including diabetes, cardiovascular diseases, autoimmune diseases, malignancies, blood-related diseases, and osteoporosis were excluded from the study. Other exclusion criteria were smoking, drug addition, alcohol consumption, parafunctional habits (clenching and bruxism), and lack of cooperation. In addition, patients who needed alveolar bone augmentation,

sinus lift, gingival graft, or vestibuloplasty were also excluded from the study.

Implant site criteria

The distance between implant platform and adjacent teeth and implant was at least 2.5 mm and 3 mm, respectively. The interocclusal space (from implant site crest to the occlusal surface of the opposed arch teeth) was at least 6 mm. The preoperative cone-beam computed tomography images of the implant site were assessed to evaluate the quality and the quantity of the available bone. All the included patients had proper bone quality and quantity at the implant site.

Surgical procedure

All surgical procedures were performed by an experienced periodontist. Implant insertion was done according to the standard protocols. Two types of submerged implants of SPI (SPI®, Thommen Medical AG, Waldenburg, Switzerland), one of the conical (contact) and the other one cylindrical (element) with 4 mm diameter and 12 mm length, were used in this study. Both implant types were made of pure titanium and had a self-cutting thread, machined collar, and a thermally acid-etched sandblasted and rough surface.^[22] The implant/abutment connection was internal hexagonal. The implant selection was done randomly for each patient using coin toss.

Following local anesthesia, a crestal incision was made by blade (#15) at most occlusal surface of the alveolar crest. The periosteal flap was retracted by periosteal elevator. Drilling was performed following manufacturer's guidelines. Implants were inserted in a way that at least 0.5 mm of the machined surface of each implant was infracrestal. The patients were instructed to take 500 mg of amoxicillin three times a day for 7 days, 500 mg of acetaminophen four times a day for 3 days, and to use chlorhexidine (0.2%) mouthwash for 2 weeks.

Implants inserted in the mandible and maxilla were uncovered after 2 and 3 months, respectively. At the time of implant exposure, amount of attached gingiva was assessed, and in case of reduced attached gingiva, apically positioned flap was used to maintain at least 1 mm of attached gingiva on the buccal wall of the implant.

Final restorations (porcelain fused to metal) were fabricated after 2–4 weeks of healing period by and experienced prosthodontist. All the patients were recalled after 6 months and underwent radiographic and clinical examinations.

Bone level

At the time of final restoration loading (baseline measurement) and after 6 months, radiographic evaluations were taken [Figures 1 and 2]. Both baseline and follow-up radiograph taking and measurements were done by one calibrated examiner who was blind to the type of implant.

Alveolar bone loss was measured using baseline and follow-up periapical radiographs. All periapical radiographs were taken by parallel technique by same X-ray machine (Planmeca, Helsinki, Finland, with 64 Kvp and 8 mA and 0.2–0.32 s), same F-speed film (Agfa-Gevaert, Mortsel, Belgium), same film holder (Kerr, Orange, CA), and processed by the same automatic film processor (Peri-pro, Air Maintenance Techniques, EUA).

To assess bone level in the periapical radiographs, distance between distal and mesial bone margins and implant shoulder was measured by digital caliper and their mean value was recorded. Measurements of baseline and follow-up were subtracted and negative values were considered as bone loss and positive values showed bone gain.

To reduce possible bias due to shortening or elongation, implant length and diameter was also recorded, and in case of mismatching values among baseline and follow-up radiographs, it was considered as distorted radiograph, and the patient was excluded from the study.

Pocket depth

Probing depth at four points around each implant (mesiobuccal, buccal, distobuccal, and palatal or lingual) was measured using Williams probe, and the mean value was calculated. Pocket depth was measured after 6-month follow-up.

Bleeding on probing

The presence of BOP during the first 30 s was recorded after 6-month follow-up.

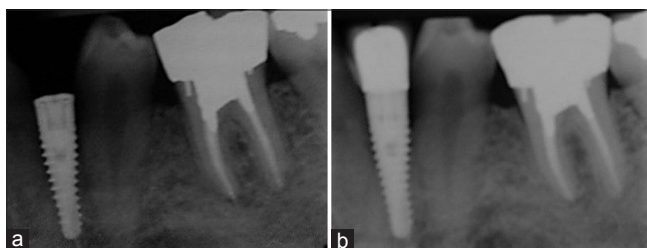


Figure 1: Radiographic image of conical implants (a) at the baseline and (b) 6 months later

Statistical analysis

Data were analyzed by SPSS Version 22 software (SPSS, Chicago, IL, USA) with significance level of 0.05. As Kolmogorov–Smirnov test showed normal distribution of the data ($P > 0.05$), to compare measurement between two types of implants and between two jaws, independent samples *t*-test was applied. For comparison of BOP, Chi-square was used.

RESULTS

All patients were males with a mean age of 38.61 ± 6.31 years. There was no significant difference between mean age of two groups ($P = 0.472$).

Among 19 included patients, three were dropped out due to distorted radiographs and four were withdrawn from the study as they did not participate on the follow-up session. Hence, 12 patients including 32 dental implants (19 conical implants and 13 cylindrical implants) were left. Among conical implants, 6 (31.57%) were inserted in the posterior maxilla and 13 (68.42%) in the posterior mandible. For cylindrical implants, the corresponding numbers were 6 (46.15%) and 7 (53.84%), respectively.

As demonstrated in Tables 1 and 2, there was no significant difference between two forms of implants regarding alveolar bone loss, pocket depth, and BOP. Further investigation was done to assess difference of bone loss and pocket depth between implants inserted in the upper and lower jaws [Table 3]. The results, however, showed no statistically significant difference.

DISCUSSION

As dental implants can effectively substitute natural tooth, they have received a great deal of attention. Several studies have shown relatively high success rate of dental implants.^[17,23] To keep the implant

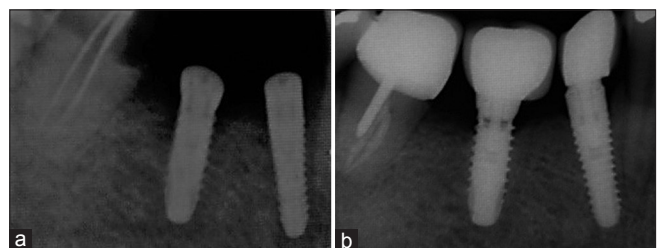


Figure 2: Radiographic image of cylindrical implants (a) at the baseline and (b) 6 months later

Table 1: Difference between conical and cylindrical implants during 6-month follow-up

Measurement	Type of implant	Mean±SD	P
Alveolar bone level change (mm)	Conical	-0.73±0.62	0.54
	Cylindrical	-0.084±0.29	
Pocket depth (mm)	Conical	2.36±0.44	0.13
	Cylindrical	2.61±0.45	

SD: Standard deviation

Table 2: Difference between conical and cylindrical implants regarding bleeding of probing prevalence during 6-month follow-up

Type of implant	BOP		Total
	Present	Not present	
Conical			
Count	9	10	19
Percentage	47.4	52.6	100.0
Cylindrical			
Count	7	6	13
Percentage	53.8	46.2	100.0
Total			
Count	16	16	32
Percentage	50.0	50.0	100.0

 $\chi^2=0.13$, $P=0.71$. BOP: Bleeding of probing**Table 3: Difference between implants inserted in the maxilla and mandible during 6-month follow-up**

Measurement	Jaw	Mean±SD	P
Alveolar bone level change (mm)	Maxilla	-0.86±0.61	0.46
	Mandible	-0.72±0.45	
Pocket depth (mm)	Maxilla	2.64±0.40	0.09
	Mandible	2.36±0.46	

SD: Standard deviation

healthy and functional, periodic follow-ups are necessary. During these follow-ups, clinical and radiographic examinations should be performed which would reveal valuable information comparable to the histologic evaluations.^[24]

The aim of the current study was to investigate the effect of implant design on crestal bone change and clinical indices at 6-month follow-up. The results revealed that although conical implants were slightly more successful, there was no statistically difference between cylindrical and conical SPI dental implants.

Previous studies have shown that conical implant design could reinforce implant primary stability and play an efficient role in implant osseointegration.^[25-27] In study of Kim *et al.*,^[19] conical implants had higher primary stability and tighter contact with adjacent bone compared to cylindrical implants. Although

some studies suggested that taper would not cause negative bone reaction,^[26,27] conical design might alter bone remodeling around implant due to stress distribution.^[28] Hence, the pattern of their stress distribution should be considered. Finite element analyses (FEA) could be helpful to investigate stress distribution pattern in dental implants. Cruz *et al.*^[29] using FEA reported that there is no significant difference in stress distribution between conical and cylindrical dental implants. However, other investigations by FEA method showed superiority of tapered implants in stress reduction and transmission compared to parallel implants.^[30,31] On the other hand, Baggi *et al.*^[32] showed that tapered implants exert higher stress on marginal bone, especially in thinner and shorter implants. Another FEA study also showed the priority of cylindrical implants and proposed that tapered implants are contraindicated in low-density bone regions.^[33]

Similar to the current study, Kim *et al.*^[19,20] investigated alveolar bone change around tapered and parallel dental implants and reported no significant difference between these two designs during 1-year follow-ups. Other clinical studies also revealed that conical implants could preserve marginal bone and are not prone to bone loss during 3-year^[16] and 5-year follow-ups.^[17] Two-year survival rate of multithread tapered dental implants which were nonsubmerged was similar to the survival rate of single-thread parallel implants.^[18] Other studies revealed that there is no difference in the stability of conical and cylindrical dental implants after 2 months and 1 year.^[34,35] However, Andersson^[15] showed higher amount of marginal bone loss after using tapered Branemark dental implants. Kadkhodazadeh *et al.*^[21] also showed that marginal bone loss around conical dental implants compared to parallel ones is higher.

Another noteworthy finding of the current study was slightly better although not significant outcome of implant therapy in the mandible compared to the maxilla. Similarly, previous studies have shown no significant difference between success rate of dental implants in the mandible and the maxilla.^[18] However, a systematic review reported that implants inserted in the mandible have relatively higher survival rate compared to those in the maxilla.^[36]

One of the limitations of the current study was limited number of participants participated in this clinical trial. In the current study, the patients were only healthy nonsmoker male participants, and there was

no significant difference between their mean ages in both groups. Another limitation was the short-term follow-up of 6 months. More clinical studies with larger sample size and longer follow-up in necessary to further investigate this issue.

CONCLUSION

Considering the limitations of the current randomized controlled trial, it was demonstrated that crestal bone loss, pocket depth, and BOP were slightly higher in cylindrical SPI implants compared to tapered ones; however, the difference was not significant. Furthermore, bone loss and pocket depth were higher for implants inserted in the maxilla compared to the mandible with no significant difference.

Financial support and sponsorship

Nil.

Conflicts of interest

There are no conflicts of interest.

REFERENCES

- Jokstad A, Braegger U, Brunski JB, Carr AB, Naert I, Wennerberg A. Quality of dental implants. *Int Dent J* 2003;53 6 Suppl 2:409-43.
- Behnia H, Motamedian SR, Kiani MT, Morad G, Khojasteh A. Accuracy and reliability of cone beam computed tomographic measurements of the bone labial and palatal to the maxillary anterior teeth. *Int J Oral Maxillofac Implants* 2015;30:1249-55.
- Morad G, Behnia H, Motamedian SR, Shahab S, Gholamin P, Khosraviani K, *et al.* Thickness of labial alveolar bone overlying healthy maxillary and mandibular anterior teeth. *J Craniofac Surg* 2014;25:1985-91.
- Vohra F, Al-Kheraif AA, Almas K, Javed F. Comparison of crestal bone loss around dental implants placed in healed sites using flapped and flapless techniques: A systematic review. *J Periodontol* 2015;86:185-91.
- Sutter F, Krekeler G, Schwammberger AE, Sutter FJ. Atraumatic surgical technique and implant bed preparation. *Quintessence Int* 1992;23:811-6.
- Kuchler U, Chappuis V, Bornstein MM, Siewczyk M, Gruber R, Maestre L, *et al.* Development of implant stability quotient values of implants placed with simultaneous sinus floor elevation - Results of a prospective study with 109 implants. *Clin Oral Implants Res* 2017;28:109-15.
- Sanz M, Ivanoff CJ, Weingart D, Wiltfang J, Gahlert M, Cordaro L, *et al.* Clinical and radiologic outcomes after submerged and transmucosal implant placement with two-piece implants in the anterior maxilla and mandible: 3-year results of a randomized controlled clinical trial. *Clin Implant Dent Relat Res* 2015;17:234-46.
- Albrektsson T, Zarb G, Worthington P, Eriksson AR. The long-term efficacy of currently used dental implants: A review and proposed criteria of success. *Int J Oral Maxillofac Implants* 1986;1:11-25.
- Eroglu CN, Ertugrul AS, Eskitascioglu M, Eskitascioglu G. Changes in the surface of bone and acid-etched and sandblasted implants following implantation and removal. *Eur J Dent* 2016;10:77-81.
- Cecchinato D, Lops D, Salvi GE, Sanz M. A prospective, randomized, controlled study using OsseoSpeed™ implants placed in maxillary fresh extraction socket: Soft tissues response. *Clin Oral Implants Res* 2015;26:20-7.
- Khorsand A, Rasouli-Ghahroudi AA, Naddafpour N, Shayesteh YS, Khojasteh A. Effect of microthread design on marginal bone level around dental implants placed in fresh extraction sockets. *Implant Dent* 2016;25:90-6.
- Karoussis IK, Brägger U, Salvi GE, Bürgin W, Lang NP. Effect of implant design on survival and success rates of titanium oral implants: A 10-year prospective cohort study of the ITI Dental Implant System. *Clin Oral Implants Res* 2004;15:8-17.
- Renouard F, Nisand D. Impact of implant length and diameter on survival rates. *Clin Oral Implants Res* 2006;17 Suppl 2:35-51.
- Moraschini V, Poubel LA, Ferreira VF, Barboza Edos S. Evaluation of survival and success rates of dental implants reported in longitudinal studies with a follow-up period of at least 10 years: A systematic review. *Int J Oral Maxillofac Surg* 2015;44:377-88.
- Andersson B. Implants for single-tooth replacement. A clinical and experimental study on the Brånemark CeraOne System. *Swed Dent J Suppl* 1995;108:1-41.
- Engquist B, Astrand P, Dahlgren S, Engquist E, Feldmann H, Gröndahl K. Marginal bone reaction to oral implants: A prospective comparative study of Astra Tech and Brånemark System implants. *Clin Oral Implants Res* 2002;13:30-7.
- Ormianer Z, Palti A. Long-term clinical evaluation of tapered multi-threaded implants: Results and influences of potential risk factors. *J Oral Implantol* 2006;32:300-7.
- Khayat PG, Milliez SN. Prospective clinical evaluation of 835 multithreaded tapered screw-vent implants: Results after two years of functional loading. *J Oral Implantol* 2007;33:225-31.
- Kim JW, Baek SH, Kim TW, Chang YI. Comparison of stability between cylindrical and conical type mini-implants. Mechanical and histological properties. *Angle Orthod* 2008;78:692-8.
- Kim JJ, Lee DW, Kim CK, Park KH, Moon IS. Effect of conical configuration of fixture on the maintenance of marginal bone level: Preliminary results at 1 year of function. *Clin Oral Implants Res* 2010;21:439-44.
- Kadkhodazadeh M, Heidari B, Abdi Z, Mollaverdi F, Amid R. Radiographic evaluation of marginal bone levels around dental implants with different designs after 1 year. *Acta Odontol Scand* 2013;71:92-5.
- Shin SI, Yun JH, Kim SG, Park B, Herr Y, Chung JH. Survival of 352 titanium implants placed in 181 patients: A 4-year multicenter field study. *J Periodontal Implant Sci* 2014;44:8-12.
- Motamedian SR, Khojaste M, Khojasteh A. Success rate of implants placed in autogenous bone blocks versus allogenic bone blocks: A systematic literature review. *Ann Maxillofac Surg* 2016;6:78-90.
- Akagawa Y, Takata T, Matsumoto T, Nikai H, Tsuru H. Correlation between clinical and histological evaluations of the peri-implant gingiva around the single-crystal sapphire endosseous implant. *J Oral Rehabil* 1989;16:581-7.
- Friberg B, Sennerby L, Roos J, Johansson P, Strid CG, Lekholm U. Evaluation of bone density using cutting resistance measurements and microradiography: An *in vitro* study in pig ribs. *Clin Oral Implants Res* 1995;6:164-71.
- O'Sullivan D, Sennerby L, Meredith N. Measurements comparing the initial stability of five designs of dental implants: A human cadaver study. *Clin Implant Dent Relat Res* 2000;2:85-92.
- O'Sullivan D, Sennerby L, Meredith N. Influence of implant taper on the primary and secondary stability of osseointegrated titanium implants. *Clin Oral Implants Res* 2004;15:474-80.
- Vandeweghe S, Cosyn J, Thevissen E, Teerlinck J, De Bruyn H. The influence of implant design on bone remodeling around surface-modified Southern Implants®. *Clin Implant Dent Relat Res* 2012;14:655-62.
- Cruz M, Lourenço AF, Toledo EM, da Silva Barra LP, de Castro Lemonge AC, Wassall T. Finite element stress analysis of conical and cylindrical threaded implant geometries. *Technol Health Care* 2006;14:421-38.
- Huang HL, Chang CH, Hsu JT, Fallgatter AM, Ko CC. Comparison of implant body designs and threaded designs of dental implants: A 3-dimensional finite element analysis. *Int J Oral Maxillofac Implants* 2007;22:551-62.
- Rieger MR, Mayberry M, Brose MO. Finite element analysis of six endosseous implants. *J Prosthet Dent* 1990;63:671-6.
- Baggi L, Cappelloni I, Di Girolamo M, Maceri F, Vairo G. The influence of implant diameter and length on stress distribution of osseointegrated implants related to crestal bone geometry: A three-dimensional finite element analysis. *J Prosthet Dent* 2008;100:422-31.
- Petrie CS, Williams JL. Comparative evaluation of implant designs: Influence of diameter, length, and taper on strains in the alveolar crest.

Sargolzaie, *et al.*: Conical vs. cylindrical dental implants

- A three-dimensional finite-element analysis. *Clin Oral Implants Res* 2005;16:486-94.
34. Friberg B, Jisander S, Widmark G, Lundgren A, Ivanoff CJ, Sennerby L, *et al.* One-year prospective three-center study comparing the outcome of a "soft bone implant" (prototype Mk IV) and the standard Brånemark implant. *Clin Implant Dent Relat Res* 2003;5:71-7.
 35. Rokn A, Ghahroudi AR, Mesgarzadeh A, Miremadi A, Yaghoobi S. Evaluation of stability changes in tapered and parallel wall implants: A human clinical trial. *J Dent (Tehran)* 2011;8:186-200.
 36. Lang NP, Pun L, Lau KY, Li KY, Wong MC. A systematic review on survival and success rates of implants placed immediately into fresh extraction sockets after at least 1 year. *Clin Oral Implants Res* 2012;23 Suppl 5:39-66.