

# Cone beam computed tomographic evaluation of styloid process: A retrospective study of 1000 patients

Merve Donmez<sup>1</sup>, Ozlem Okumus<sup>2</sup>, Filiz Namdar Pekiner<sup>1</sup>

**Correspondence:** Dr. Filiz Namdar Pekiner  
Email: fpekiner@gmail.com

<sup>1</sup>Department of Oral Diagnosis and Radiology, Faculty of Dentistry, Marmara University, Istanbul, Turkiye,  
<sup>2</sup>Department of Oral Diagnosis and Radiology, Faculty of Dentistry, Istanbul Kemerburgaz University, Istanbul, Turkiye

## ABSTRACT

**Objective:** The styloid process (SP) is a bony projection, located just anterior to the stylomastoid foramen, the normal length of which is approximately 20–30 mm. The length of SP when exceeds 30 mm it is said to “elongated.” The purpose of this retrospective study was to assess the prevalence of elongated SP (ESP) by cone beam computed tomography (CBCT) examination in Turkish subpopulation and its relation to gender and age. **Materials and Methods:** This study analyzed CBCT of 1000 patients who were randomly selected to participate and were aged from 14 to 78 years. Any radiograph with questionable SP was excluded from the study. The apparent length and thickness of the SP were measured by two dental and maxillofacial radiologists. The ESP was classified with radiographic appearance-based morphology of elongation. The data were analyzed with the IBM SPSS Statistics 20.0. **Results:** The mean age of patients was  $42.49 \pm 14.83$  years. The length of SP was measured over 30 mm in 151 patients (15.1%). A total of 151 CBCT showed ESP, of which 87 (57.6%) were noticed in males and 64 (42.4%) in female patients. The length of right-sided SP ranged from 30.05 to 85.49 mm and left-sided SP from 30.14 to 83.72 mm. **Conclusion:** CBCT is a valuable diagnostic imaging tool which makes accurate length measurements. It is important for the clinicians to be aware of natural variations of the SP whose clinical importance is not well understood.

**Key words:** Cone beam computed tomography, elongated, styloid process

## INTRODUCTION

The name styloid process (SP) was derived from the Greek word “stylos” meaning a pillar. The SP is a cylindrical, thin, slender bony projection which arises from the posterior part of the lower surface of the petrous part of the temporal bone immediately in front of the stylomastoid foramen.<sup>[1,2]</sup> The process is directed downward to the front and slightly medially. The ligament represents from embryological view the continuation of the apex of SP. All the above the entire previous mentioned features

constitute the stylohyoid chain. The whole chain derives embryologically from four cartilages: tympanohyale, stylohyale, ceratohyale, and hypohyale. The SP originates from the second branchial arch.<sup>[3-6]</sup>

Eagle’s syndrome is determined as the symptomatic elongation of the SP or calcification of the stylohyoid ligament complex. This syndrome was first described by Watt W. Eagle, an otorhinolaryngologist.<sup>[1,7-9]</sup>

This is an open access article distributed under the terms of the Creative Commons Attribution-NonCommercial-ShareAlike 3.0 License, which allows others to remix, tweak, and build upon the work non-commercially, as long as the author is credited and the new creations are licensed under the identical terms.

**For reprints contact:** reprints@medknow.com

**How to cite this article:** Donmez M, Okumus O, Pekiner FN. Cone beam computed tomographic evaluation of styloid process: A retrospective study of 1000 patients. *Eur J Dent* 2017;11:210-5.

**DOI:** 10.4103/ejd.ejd\_56\_17

Access this article online	
<p>Quick Response Code:</p> 	<p>Website: www.eurjdent.com</p>

There are different classifications for morphology and size of the SP. It is divided into two types, normal and elongated. The normal length of SP estimates 20–25 mm. Length of SP when exceeds 30 mm it is said to “elongated.”<sup>[6,10-12]</sup>

Elongated SP (ESP) may be one of the causes annoying orofacial pain. Eagle’s syndrome develops unilaterally or bilaterally, and more uncommonly when an ESP or calcified stylohyoid ligament causes recurrent throat pain, dysphagia, pain on opening the mouth and during chewing, or facial pain.<sup>[6,13]</sup>

The ESP was classified into three types with radiographic appearance-based morphology of elongation by Langlais *et al.* Type I: elongated, Type II: pseudoarticulated, and Type III: segmented.<sup>[14-16]</sup>

It requires exact clinical and radiological examination of the maxillofacial region. Diagnosis can usually be made during a physical examination by digital palpation of the SP in the tonsillar fossa. Anterior-posterior, lateral skull, panoramic radiography, or three-dimensional (3-D) computed tomography (CT) is used to diagnose ESP. Image magnification and distortion ultimately limit dimensional accuracy in panoramic radiography; therefore, it cannot be assessed clearly due to superimposition of adjacent structures. However, 3-D cone beam CT (CBCT) is introduced as a new technique which can precisely measure the length of the anatomical structures of maxillofacial region. This radiological technique allows images to be acquired with low dose of radiation and shorter patient examination time. There are a lot of reports on SP prevalence and type of elongation by panoramic radiography, but we could find only one retrospective study on CBCT examination to assess the length of SP with ESP patients.<sup>[16-21]</sup>

Therefore, the purpose of this retrospective study was to evaluate the prevalence of ESP and type of elongation by CBCT examination in Turkish subpopulation and its relation to gender and age.

## MATERIALS AND METHODS

In this retrospective study, 1000 CBCT images of patients who were randomly selected and aged from 14 to 78 years were analyzed. The study was carried out in Department of Oral Diagnosis and Radiology of Marmara University of Faculty of Dentistry. All the CBCT examinations were acquired with Planmeca

ProMax 3D Mid (Planmeca Oy, Helsinki, Finland) at 90 kV, 12 mA, and 36 s exposure time and by positioning the reference points on the face of patients recommended by the producing company. Only high-quality images were included in the study. Any radiograph with questionable SP was excluded from the study. The study protocol numbered as 70737436–050.06.04 was approved by Noninvasive Clinical Research Ethics Committee, Marmara University Faculty of Medicine.

All projections were taken with the same radiographic equipment (Planmeca ProMax SD Mid CBCT device, Helsinki, Finland, with 90 kVp and 12 mA). All tomographic images were carried out by the same technician. Romexis 2.92 software program (Planmeca Oy, Helsinki, Finland) was used for reconstruction and evaluation of all projections. The images were exported and saved as a single frame DICOM files. The assessment of images was fulfilled directly on monitor screen (Monitor 23 inch Acer 1920 × 1080 pixel HP Reconstruction).

To ensure a professional and efficient evaluation, oral diagnosis and radiology clinician and specialist (MD and ÖO) who had been working in the Department of Oral Diagnosis and Radiology evaluated the clinical images. During meetings for the pilot study, the clinician and radiology specialist trained to evaluate tomographic images by specialist (FNP) who had been working in oral diagnosis and radiology for 15 years or more, and an agreement on the objective criteria for the qualitative evaluation of the images was forged among the evaluators.

The length and type of elongation of SP were measured and recorded separately for each side by two dental and maxillofacial radiologists. The length of the SP was measured bilaterally in the CBCT sagittal plane. The bilateral outline of external auditory canal was drawn with the aid of the brightness and contrast adjustments. The lowest point of the contour of the acoustic meatus was traced under a horizontal line. Length of SP >30 mm was recorded as unilateral or bilateral elongation [Figures 1 and 2a, b].

Furthermore, the ESP was evaluated according to radiographic appearance based on the morphology of elongation according to the classification of Langlais *et al.*<sup>[14]</sup> [Figure 3]:

- Type I – elongated: SP is characterized by uninterrupted integrity of the image [Figure 4]
- Type II – pseudoarticulated: The portions

of SP are apparently joined to each other by a pseudoarticulation [Figure 5]

- Type III - segmented: This type is formed by discontinuous portions of the SP [Figure 6].

### Statistical analysis

The data were analyzed with the IBM SPSS Statistics (IBM SPSS, Turkey) version 22.0 (SPSS Inc., Chicago, IL, USA). Descriptive statistical methods (mean, standard deviation, and frequency) were used for

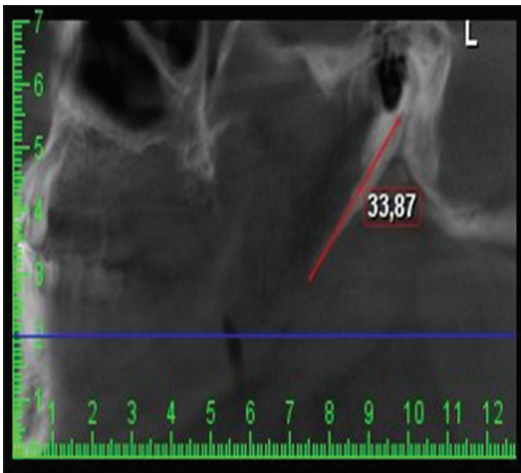


Figure 1: The length distance between the styloid process extended from the temporal bone to the apex

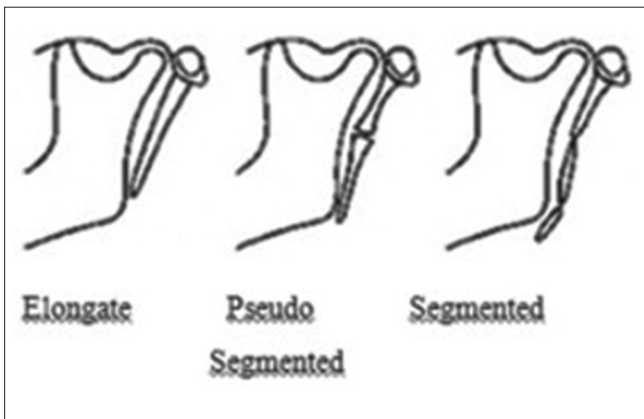


Figure 3: Morphological classification of Langlais

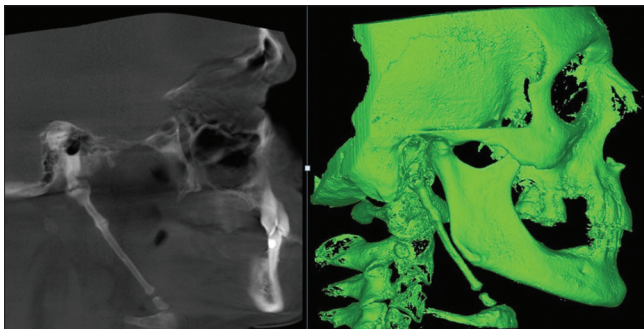


Figure 5: Type II elongated styloid process

evaluation of the data. Chi-square test was used to compare qualitative data. One-way ANOVA test was used to compare quantitative data and age groups. Values of  $P < 0.05$  were interpreted as significant.

### RESULTS

A total of 1000 CBCT images were evaluated, and the length of SP  $>30$  mm was detected in 151 (15.1%) participants who were 87 (57.6%) males and 64 (42.4%) females. The mean ages of patients were  $42.49 \pm 14.83$  years. ESP was observed bilaterally in 92.1% of patients and unilaterally in 7.9%. In the present study, the length of SP ranged from 30.0 to 85.49 mm for the right sides and from 30.14 to 83.72 mm for the left sides in males, respectively. In addition, the length of SP ranged from 30.05 to 66.17 mm for the right sides and from 30.0 to 66.16 mm for the left sides in females,

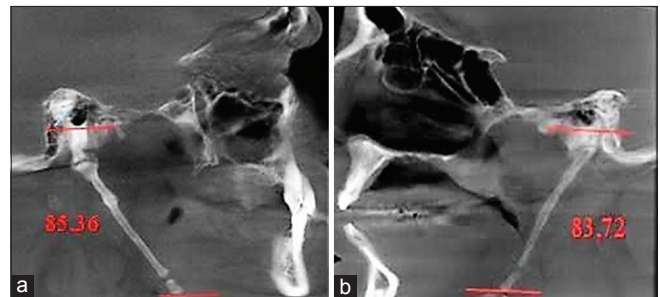


Figure 2: (a and b) The length of the styloid process was measured bilaterally in the cone beam computed tomography sagittal plane

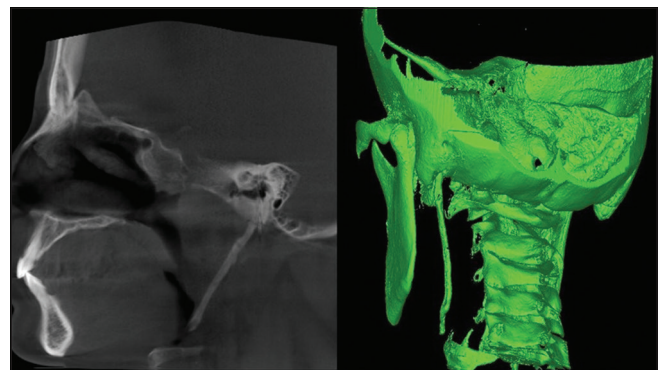


Figure 4: Type I elongated styloid process

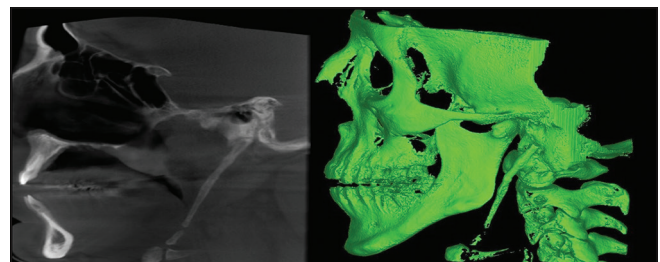


Figure 6: Type III elongated styloid process (2 segmented)



respectively. Among the ESPs, Type I was the most frequent type of SP on both sides whereas Type II was the least common type on both sides [Table 1].

No statistically significant differences were found between the SP types and gender [Table 2].

No statistically significant differences were found between the SP types and age groups on the right side. In the left side, Type III percentage was significantly higher in the age of 25 and under than the other age groups whereas Type I and II percentage was significantly lower. Totally, in age of 25 and under Type III percentage was significantly higher than the other age groups [Table 3].

Totally, the mean age of Type III percentage was significantly lower than the mean ages of Type II and Type I percentage [Table 4].

## DISCUSSION

In the present study, the prevalence and type of ESP by CBCT examination in Turkish subpopulation were evaluated retrospectively.

During the development, the hyoid smaller horn, SP, and the stylohyoid ligament are developed

Table 1: The distribution of elongation types	
	n (%)
Right (n=151)	
Type I	67 (44.4)
Type II	23 (15.2)
Type III	61 (40.4)
Left (n=149)	
Type I	85 (57.0)
Type II	17 (11.4)
Type III	47 (31.5)

Table 2: The distribution of the types according to gender				
Gender	Type I, n (%)	Type II, n (%)	Type III, n (%)	P
Right				
Male	41 (47.1)	10 (11.5)	36 (41.4)	0.319
Female	26 (40.6)	13 (20.3)	25 (39.1)	
Left				
Male	52 (59.8)	8 (9.2)	27 (31)	0.552
Female	33 (53.2)	9 (14.5)	20 (32.3)	
Total				
Male	93 (53.4)	18 (10.3)	63 (36.2)	0.182
Female	59 (46.8)	22 (17.5)	45 (35.7)	

Chi-square test. P<0.05

from the cartilage of second pharyngeal arch (Reichert’s cartilage). On some occasions, the stylohyoid ligament goes for ossification and will lead to the formation of ESP.<sup>[22,23]</sup>

The length of SP of temporal bone varies from population to population. Jung *et al.*<sup>[24]</sup> suggested that a SP of only more than 45 mm length should be considered to be elongated. However, Keur *et al.*<sup>[22]</sup> suggested that the SP length and its mineralized stylohyoid ligament, if appears more than 30 mm in a radiograph film, is considered as a significant predisposing factor. Vadgaonkar *et al.*<sup>[23]</sup> observed that the length of SP ranged from 18 to 50 mm and the mean length of the SP was 17.8 ± 9.3 mm and 18.2 ± 5.6 mm for the right and left sides, respectively. In addition, these researchers reported that the SP elongation was observed more commonly on the left. In our study, the length of SP ranged from 30.0 to 85.49 mm for the right sides and from 30.14 to 83.72 mm for the left sides in males, respectively. Furthermore, the length of SP ranged from 30.05 to 66.17 mm for the right

Table 3: The distribution of the types according to age groups				
Age	Type I, n (%)	Type II, n (%)	Type III, n (%)	P
Right				
≤25	6 (26.1)	2 (8.7)	15 (65.2)	0.063
26-35	18 (58.1)	2 (6.5)	11 (35.5)	
36-45	12 (35.3)	7 (20.6)	15 (44.1)	
46-55	15 (48.4)	8 (25.8)	8 (25.8)	
≥56	16 (50)	4 (12.5)	12 (37.5)	
Left				
≤25	7 (30.4)	0	16 (69.6)	0.001**
26-35	19 (63.3)	1 (3.3)	10 (33.3)	
36-45	19 (55.9)	6 (17.6)	9 (26.5)	
46-55	21 (67.7)	3 (9.7)	7 (22.6)	
≥56	19 (61.3)	7 (22.6)	5 (16.1)	
Total				
≤25	13 (28.3)	2 (4.3)	31 (67.4)	0.001**
26-35	37 (60.7)	3 (4.9)	21 (34.4)	
36-45	31 (45.6)	13 (19.1)	24 (35.3)	
46-55	36 (58.1)	11 (17.7)	15 (24.2)	
≥56	35 (55.6)	11 (17.5)	17 (27)	

Chi-square test. \*\*P<0.01

Table 4: Evaluation of the mean age according to type				
Age	Mean±SD			P
	Type I	Type II	Type III	
Right	43.54±13.91	45.48±11.74	40.21±16.65	0.260
Left	43.88±13.61	51.12±12.59	36.66±15.67	0.001**
Total	43.73±13.69	47.88±12.28	38.67±16.25	0.001**

One-way ANOVA. \*\*P<0.01. SD: Standard deviation

sides and from 30.0 to 66.16 mm for the left sides in females, respectively.

Langlais *et al.*<sup>[14]</sup> proposed a classification of the radiographic appearance of elongated and mineralized ESP based on three types of complexes including Type I, Type II, and Type III. This classification was used in a few studies. Ilgüy *et al.*<sup>[16]</sup> evaluated 860 panoramic radiographs and they observed that 32 patients (3.7%) have ESP. Among of 32 patients, Type I (elongated) was found the most frequent type of SP on both sides. In another study, the panoramic radiographs of 55 adults were analyzed by Kursoglu *et al.*<sup>[17]</sup> Type I was observed most frequently in the study. Similarly, our report confirms that Type I (elongated, SP is characterized by uninterrupted integrity of the image) was the most frequent type. Oztunç *et al.*<sup>[20]</sup> was evaluated CBCT records of 208 patients, and out of 208 patients, 112 (54%) had ESP. Contrary, Type II was observed the most frequently in that study.

The variation in the data from population samples may be because the difference in the method which was used to measure. Vieira *et al.*<sup>[25]</sup> evaluated that digital panoramic radiographs of 736 patients (412 female and 324 male) were consecutively selected from a private radiology clinic's secondary database, and in this study, the researchers revealed a high prevalence (43.89%) of ESP in a Brazilian population. Their prevalence is higher than those recorded by Rizzatti-Barbosa *et al.*<sup>[26]</sup> (20%) and Leite *et al.*<sup>[27]</sup> (19.56%) and lower than the one recorded by de Andrade *et al.*<sup>[28]</sup> (76%). In our study, a prevalence of 15.1% elongation of the SP was observed in all the samples. The wide variation in the prevalence of ESP observed in studies conducted in different locations can be explained by the variations in the diagnostic and image interpretation criteria, geographical location, and local population particularities.<sup>[21,29,30]</sup>

The full length of SP must be visualized for its measurement. The ESP can be clinically detected by palpating the tonsillar fossa and is diagnosed by taking the X-ray lateral view of the neck, orthopantomogram, or CT.<sup>[23]</sup>

Panoramic radiography frequently was selected because it is a routine examination requested by the dentist that offers the possibility of extensive visualization of the structures of the maxillofacial complex including the full length of SP. However, caution is recommended when analyzing and performing absolute measurements and relative comparisons for this type of examination because

of the possible overlapping of anatomical structures (mandibular bone and teeth) and the occurrence of distortions and magnifications.<sup>[11,20,31]</sup> Therefore, advanced imaging techniques are required to overcome this issue. In 3-D CT reconstruction, there is no geometric error due to magnification effects. The true character of bilaterally asymmetrical malformations may be evaluated since overlap of structures is not encountered. Operator-related error is also minimized in 3-D CT. However, 3-D CT imaging has some limitations such as a slight movement may result in degradation of images and higher radiation dose is required, depending on the number of sections taken. CBCT may be recommended as a dose-sparing technique compared with standard medical CT scans for common oral and maxillofacial radiographic imaging tasks. The advantages of CBCT imaging are the following: lower radiation dose than conventional CT, the possibility of individualized overlap-free reconstructions, and DICOM data can be imported and exported for other applications. In the literature, panoramic radiograph and CT were used as a diagnostic tool in most of the studies evaluating the structural characteristics of ESP;<sup>[32-34]</sup> however, there is a few studies based on CBCT examination for the evaluation of structural characteristics of ESP.<sup>[20]</sup> Therefore, in this retrospective study, we evaluate the prevalence of ESP and type of elongation by CBCT examination.

## CONCLUSION

The full length of SP must be visualized for its measurement, but the visualization is not easy on conventional radiographs. The mandibular bone and the teeth superimpose on SP and reduce the quality of the image on conventional radiographs. CBCT is a valuable diagnostic imaging tool which makes accurate length measurements. It is important for the clinicians to be aware of natural variations of the SP whose clinical importance is not well understood.

## Acknowledgments

This study was presented at Oral Diagnosis and Maxillofacial Radiology Society VI. National Symposium and I. International Congress, İzmir, April 17-19, 2015.

## Financial support and sponsorship

Nil.

## Conflicts of interest

There are no conflicts of interest.

## REFERENCES

1. Shaik MA, Naheeda, Kaleem SM, Wahab A, Hameed S. Prevalence of elongated styloid process in Saudi population of Aseer region. *Eur J Dent* 2013;7:449-54.
2. Roopashri G, Vaishali MR, David MP, Baig M. Evaluation of elongated styloid process on digital panoramic radiographs. *J Contemp Dent Pract* 2012;13:618-22.
3. Standring S. Skull and Mandible. In: *Gray's Anatomy: The Anatomical Basis of Clinical Practice*. 39<sup>th</sup> ed. Edinburgh: Elsevier; 2005. p. 470.
4. Rathee M, Hooda A, Yadav S, Gulia J. Bilateral elongated styloid process: A case report and review of literature. *Internet J Otorhinolaryngol* 2009;12:1.
5. Alpoz E, Akar GC, Celik S, Govsa F, Lomcali G. Prevalence and pattern of stylohyoid chain complex patterns detected by panoramic radiographs among Turkish population. *Surg Radiol Anat* 2014;36:39-46.
6. Sekerci AE, Soyly E, Arikian MP, Aglarci OS. Is there a relationship between the presence of ponticulus posticus and elongated styloid process? *Clin Imaging* 2015;39:220-4.
7. Eagle WW. Symptomatic elongated styloid process; report of two cases of styloid process-carotid artery syndrome with operation. *Arch Otolaryngol* 1949;49:490-503.
8. Ghosh LM, Dubey SP. The syndrome of elongated styloid process. *Auris Nasus Larynx* 1999;26:169-75.
9. Moffat DA, Ramsden RT, Shaw HJ. The styloid process syndrome: Aetiological factors and surgical management. *J Laryngol Otol* 1977;91:279-94.
10. Murtagh RD, Caracciolo JT, Fernandez G. CT findings associated with Eagle syndrome. *AJNR Am J Neuroradiol* 2001;22:1401-2.
11. Anbiaee N, Javadzadeh A. Elongated styloid process: Is it a pathologic condition? *Indian J Dent Res* 2011;22:673-7.
12. Prasad KC, Kamath MP, Reddy KJ, Raju K, Agarwal S. Elongated styloid process (Eagle's syndrome): A clinical study. *J Oral Maxillofac Surg* 2002;60:171-5.
13. Slavin KV. Eagle syndrome: Entrapment of the glossopharyngeal nerve? Case report and review of the literature. *J Neurosurg* 2002;97:216-8.
14. Langlais RP, Miles DA, Van Dis ML. Elongated and mineralized stylohyoid ligament complex: A proposed classification and report of a case of Eagle's syndrome. *Oral Surg Oral Med Oral Pathol* 1986;61:527-32.
15. Yavuz H, Caylakli F, Erkan AN, Ozluoglu LN. Modified intraoral approach for removal of an elongated styloid process. *J Otolaryngol Head Neck Surg* 2011;40:86-90.
16. Ilgüy M, Ilgüy D, Güler N, Bayirli G. Incidence of the type and calcification patterns in patients with elongated styloid process. *J Int Med Res* 2005;33:96-102.
17. Kursoglu P, Unalan F, Erdem T. Radiological evaluation of the styloid process in young adults resident in Turkey's Yeditepe University faculty of dentistry. *Oral Surg Oral Med Oral Pathol Oral Radiol Endod* 2005;100:491-4.
18. Scaf G, Freitas DQ, Loffredo Lde C. Diagnostic reproducibility of the elongated styloid process. *J Appl Oral Sci* 2003;11:120-4.
19. Sudhakara Reddy R, Sai Kiran Ch, Sai Madhavi N, Raghavendra MN, Satish A. Prevalence of elongation and calcification patterns of elongated styloid process in south India. *J Clin Exp Dent* 2013;5:e30-5.
20. Oztunç H, Evlice B, Tatli U, Evlice A. Cone-beam computed tomographic evaluation of styloid process: A retrospective study of 208 patients with orofacial pain. *Head Face Med* 2014;10:5.
21. Basekim CC, Mutlu H, Güngör A, Silit E, Pekkaflali Z, Kutlay M, *et al.* Evaluation of styloid process by three-dimensional computed tomography. *Eur Radiol* 2005;15:134-9.
22. Keur JJ, Campbell JP, McCarthy JF, Ralph WJ. The clinical significance of the elongated styloid process. *Oral Surg Oral Med Oral Pathol* 1986;61:399-404.
23. Vadgaonkar R, Murlimanju BV, Prabhu LV, Rai R, Pai MM, Tonse M, *et al.* Morphological study of styloid process of the temporal bone and its clinical implications. *Anat Cell Biol* 2015;48:195-200.
24. Jung T, Tschernitschek H, Hippen H, Schneider B, Borchers L. Elongated styloid process: When is it really elongated? *Dentomaxillofac Radiol* 2004;33:119-24.
25. Vieira EM, Guedes OA, Morais SD, Musis CR, Albuquerque PA, Borges ÁH. Prevalence of elongated styloid process in a central Brazilian population. *J Clin Diagn Res* 2015;9:ZC90-2.
26. Rizzatti-Barbosa CM, Ribeiro MC, Silva-Concilio LR, Di Hipolito O, Ambrosano GM. Is an elongated stylohyoid process prevalent in the elderly? A radiographic study in a Brazilian population. *Gerodontology* 2005;22:112-5.
27. Leite HF, Niccoli-Filho WD, Liberti EA, Madeira MC, Simões S. Prevalence of elongated stylohyoid ligament complex in human skulls. *Rev Odontol UNESP* 1988;17:145-51.
28. de Andrade KM, Rodrigues CA, Watanabe PC, Mazzetto MO. Styloid process elongation and calcification in subjects with TMD: Clinical and radiographic aspects. *Braz Dent J* 2012;23:443-50.
29. Andrei F, Motoc AG, Didilescu AC, Rusu MC. A 3D cone beam computed tomography study of the styloid process of the temporal bone. *Folia Morphol (Warsz)* 2013;72:29-35.
30. Cullu N, Deveer M, Sahan M, Tetiker H, Yilmaz M. Radiological evaluation of the styloid process length in the normal population. *Folia Morphol (Warsz)* 2013;72:318-21.
31. Ekici F, Tekbas G, Hamidi C, Onder H, Goya C, Cetincakmak MG, *et al.* The distribution of stylohyoid chain anatomic variations by age groups and gender: An analysis using MDCT. *Eur Arch Otorhinolaryngol* 2013;270:1715-20.
32. Ludlow JB, Ivanovic M. Comparative dosimetry of dental CBCT devices and 64-slice CT for oral and maxillofacial radiology. *Oral Surg Oral Med Oral Pathol Oral Radiol Endod* 2008;106:106-14.
33. Orhan K, Sakul BU, Oz U, Bilecenoglu B. Evaluation of the pterygoid hamulus morphology using cone beam computed tomography. *Oral Surg Oral Med Oral Pathol Oral Radiol Endod* 2011;112:e48-55.
34. Moreira CR, Sales MA, Lopes PM, Cavalcanti MG. Assessment of linear and angular measurements on three-dimensional cone-beam computed tomographic images. *Oral Surg Oral Med Oral Pathol Oral Radiol Endod* 2009;108:430-6.