

# Open Bite, Root Resorptions, Midline Deviation, and Bilateral Crossbite Malocclusion

Oscar Mario Antelo<sup>1,2</sup>, Thiago Martins Meira<sup>2</sup>, Laís Cristina Giacobbo<sup>2</sup>, Ariel Adriano Reyes Pacheco<sup>2,3</sup>, Orlando Motohiro Tanaka<sup>2,4</sup>

<sup>1</sup>Department of Orthodontics, Universidad Intercontinental, Cidade de México, México, <sup>2</sup>Pontifícia Universidade Católica do Paraná, School of Life Sciences, Curitiba, Brazil, <sup>3</sup>Pontifícia Universidade Católica Madre and Maestra, RSTA, School of Stomatology, <sup>4</sup>Fellow in The Center for Advanced Dental Education at SLU, MO, USA

## Abstract

There has been a progressive increase in demand for orthodontic treatment for adult patients. A 40-year-old female came to the orthodontic clinic complaining of overcrowding and midline deviation. Clinical examination showed facial asymmetry and midline deviation due to the extraction of the maxillary and mandibular first premolars of the right side. A periapical radiograph showed a severe root resorption in the maxillary central and lateral incisors. The treatment objectives were to correct the midline deviation, close the open bite, correct the bilateral posterior crossbite, and obtain a Class I relationship for the molars and canines on both sides. This case report shows a treatment approach that was effective in correcting all problems of malocclusion that the adult patient presented. The treatment results have established a new functional and stable occlusion with improvement of facial esthetics, and the roots were no shorter than before treatment.

**Keywords:** Midline, openbite, orthodontics, short root

## INTRODUCTION

Adult patient seeks orthodontic treatment mainly for esthetic reasons and to a lesser extent, as adjunctive therapy or to improve functionality.<sup>[1,2]</sup> Some patients did not receive orthodontic treatment during adolescence or early adulthood due to financial reasons or lack of information while others received treatment but found unsatisfactory results.<sup>[3]</sup>

Open bite is a type of malocclusion that is difficult to treat and presents a high incidence of posttreatment relapse; it can be due dental or skeletal in origin.<sup>[4]</sup> In patients with anterior open bite, it is common to observe a lack of transverse development of the maxilla, manifested by unilateral or bilateral crossbite, depending on its severity and etiology.<sup>[5]</sup> The literature also mentions that there is a relation between root resorption in the area of the upper incisors in patients presenting with anterior open bite.<sup>[6]</sup>

The appropriate treatment plan for adult patients usually requires not only conventional appliances but also auxiliary appliances and procedures. Miniscrews provide temporary skeletal anchorage and should be limited to cases that cannot be treated with conventional appliances alone. The role of miniscrews is to expand the range of orthodontic treatment correction.<sup>[7]</sup>

In this case report, comprehensive orthodontic treatment with miniscrew anchorage was applied to distalize the maxillary dentition, correct the midline deviation, close the anterior open bite, correct the posterior crossbite, and the maintenance the roots no shorter than before treatment.

## DIAGNOSIS AND ETIOLOGY

A 40-year-old female came to the orthodontic clinic with chief complaints of overcrowding and midline deviation. She had received previous orthodontic treatment during adolescence. Clinical examination showed facial asymmetry and midline deviation due to extractions of the upper and lower first premolars of the right side [Figure 1]. No clinical temporomandibular joint symptomatology or limitations were noted. The panoramic and periapical radiographs showed a significant root resorption in the upper central and lateral incisors [Figure 2].

**Address for correspondence:** Dr. Orlando Motohiro Tanaka, Pontifícia Universidade Católica Do Paraná, Graduate Dentistry Program In Orthodontics, PUCPR, R. Imaculada Conceição, 1155, Curitiba, Brazil. E-mail: tanakaom@gmail.com

This is an open access article distributed under the terms of the Creative Commons Attribution-NonCommercial-ShareAlike 3.0 License, which allows others to remix, tweak, and build upon the work non-commercially, as long as the author is credited and the new creations are licensed under the identical terms.

**For reprints contact:** reprints@medknow.com

**How to cite this article:** Antelo OM, Meira TM, Giacobbo LC, Reyes Pacheco AA, Tanaka OM. Open bite, root resorptions, midline deviation, and bilateral crossbite malocclusion. *Eur J Gen Dent* 2018;7:19-24.

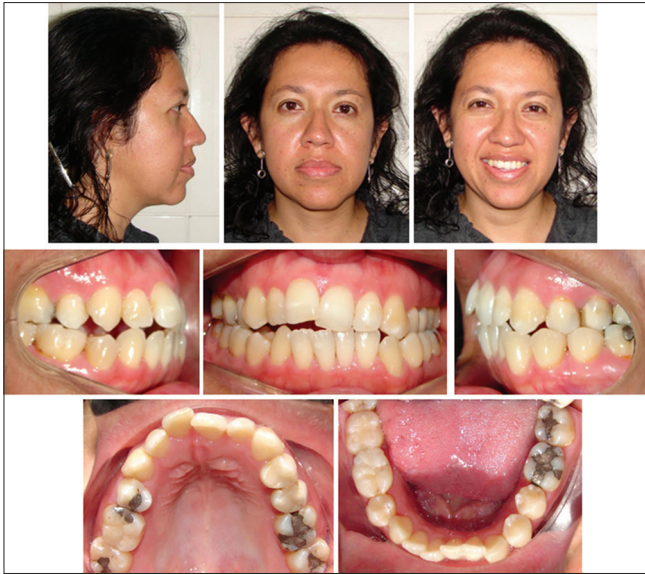### Access this article online

#### Quick Response Code:



**Website:**  
www.ejgd.org

**DOI:**  
10.4103/ejgd.ejgd\_102\_17



**Figure 1:** Pretreatment extraoral and intraoral photographs

The patient was diagnosed with a skeletal Class II malocclusion (SNA 4.5°), a vertical growth pattern (FMA 32°) and a bilateral posterior crossbite. She had a Class I molar and canine on the left side and a Class III molar and canine on the right side, a 2 mm open bite and a 5 mm overjet and midline deviation [Figure 3]. Despite her skeletal measures, she had a good profile but denoted a marked asymmetry of the mandible to the left side [Figure 1 and Table 1].

**Treatment objectives**

The treatment objectives were to correct the midline deviation, close the open bite, correct the bilateral posterior crossbite, and obtain a Class I molar and canine relationship on both sides.

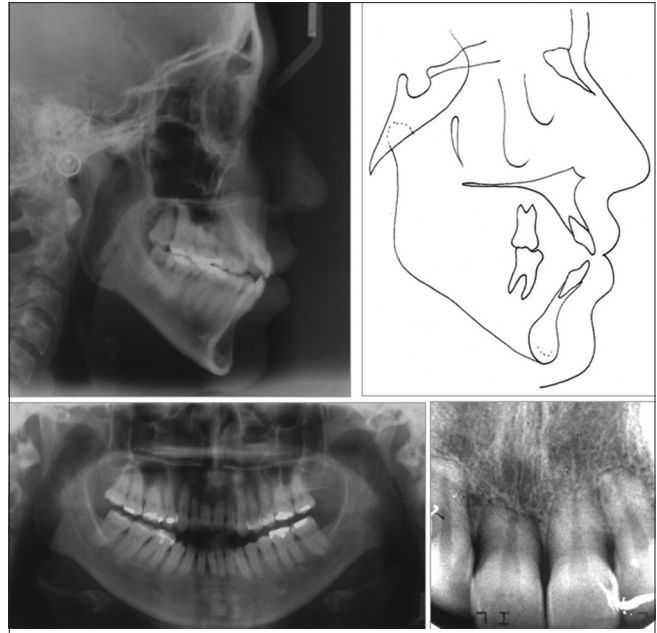
**Treatment alternatives**

We had considered a LeFort osteotomy with posterior maxillary impaction for the correction of the open bite tendency and high mandibular plane angle (FMA 32°) with a surgical maxillary expansion for the bilateral posterior crossbite.<sup>[8,9]</sup>

The patient did not agree with the surgical approach. To correct the midline deviation, we planned extractions of the upper first and lower first premolars on the left side, but instead of we extracted the upper second premolar on the left side due to its invasive restoration.

**Treatment plan**

The selected treatment did not require orthognathic surgery. Treatment began with the placement of a transpalatal anchorage and was followed by extractions of the second upper left and the first lower left premolars. The maxillary arch was bonded first, and the mandibular arch was bonded 3 weeks later. To correct the maxillary midline, a miniscrew was placed in the region of the tuberosity 3 mm distal to the upper left second molar. For space closure, sliding mechanics were performed.



**Figure 2:** Pretreatment panoramic and periapical radiograph, cephalogram, and tracing

**Table 1: Cephalometric measurement**

Measurements	Initial	Final	Follow-up
SNA angle (°)	79	79	79,5
SNB angle (°)	74,5	74,5	75
ANB angle (°)	4,5	4,5	4,5
AO-BO (mm)	-6	-2	-2
Facial angle (°)	88	88	87
Convexity (°)	8	8	8
GoGn-SN (°)	46	45	45
FMA (°)	32	32	33
Y Axis (°)	64	63	63
1-NA (mm)	8	6	6
1-NA (°)	30	24	23
1-NB (mm)	11	10	11
1-NB (°)	34	31	31
IMPA (°)	93,5	91,5	61
Interincisal angle (°)	110	120	121
Z angle (°)	73	70	70

**Treatment progress**

The TPA prevented molar anchorage loss on the left side during alignment and leveling. The maxillary arch was bonded first, and the mandibular arch was bonded 3 weeks later. Self-ligating brackets 0.022 inch MBT (Smartclip, 3M Unitek) were used. The archwires sequence consisted of nickel-titanium heat-activated wires (3M Unitek), 0.014 inch initial alignment, 0.014 + 0.016 inch (Tandem) alignment completed, 0.017 × 0.019 inch initial leveling, and 0.019 × 0.025 inch leveling completed. After leveling, the TPA was taken off, and a miniscrew was placed in the region of the tuberosity, 3 mm distal to the second upper left molar to correct

the upper midline deviation and to perform a space closure without anchorage loose [Figure 4]. For space closure, sliding mechanics were performed, using 0.019 inch × 0.025 inch SS wires and active tiebacks [Figure 5]. Once the spaces were closed, the 0.019 inch × 0.025 inch SS maxillary wire was expanded, and the lower arch was constricted. Class III elastics were used on the right side, and Class II elastics were used on the left; these elastics were used to achieve proper occlusion and midline coincidence.

Once the objectives of the treatment were achieved, fixed appliances were in place for an extra period of 90 days with criss-cross elastics to maintain the posterior crossbite correction and potentiate the long-term stability of results.

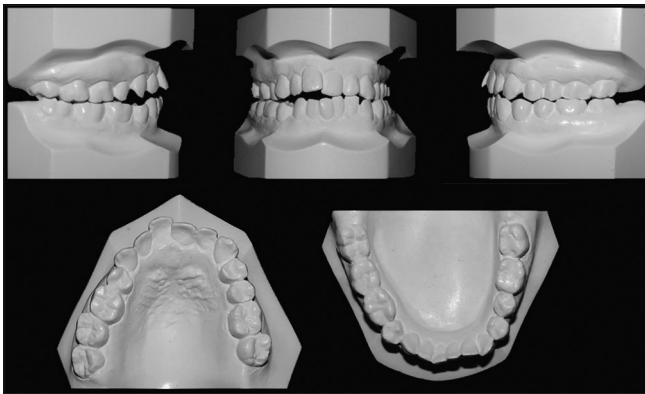


Figure 3: Pretreatment dental casts

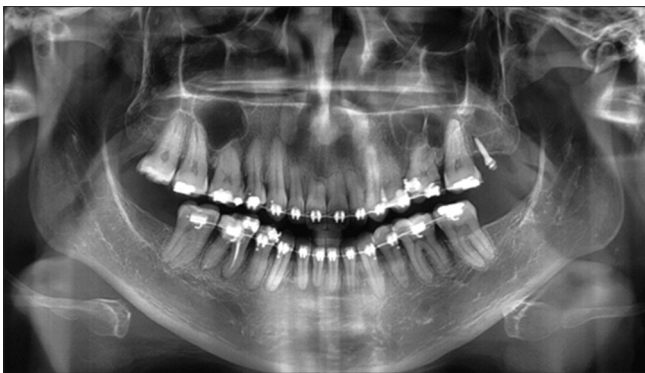

Figure 4: Progress panoramic radiograph

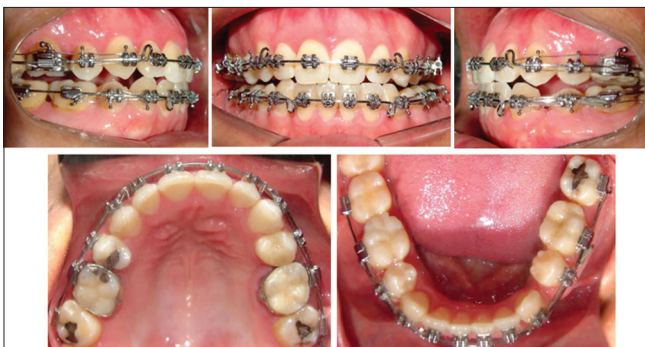

Figure 5: Progress intraoral photographs

At the final seating of the occlusion was placed in a 0.016 inch SS segmented arch from lateral to lateral in the upper teeth and in a 0.016 inch SS complete arch in the lower teeth; then vertical elastics were placed to achieve proper intercuspitation.

**Treatment results**

After 2 years and 10 months of treatment, fixed appliances were removed and a removable Hawley type retainer was placed in the maxillary arch. A fixed retainer from canine to canine was placed in the mandibular arch, and a fixed buccal retainer extended from canine to the second premolar on the left side to prevent further opening of the space. The posttreatment records showed minor modification in the facial profile. Dental crowding in both arches was aligned; midline deviation, openbite, and crossbite were corrected [Figure 6]. The occlusion was improved to achieve Class I molar and canine relationships on both sides [Figures 6 and 7]. Incisal guidance in anterior excursion and canine guidance in lateral movement were achieved [Figure 8].

The posttreatment panoramic and periapical radiographs showed that the roots were no shorter than before treatment [Figure 9]. From the cephalometric analysis, the wits appraisal value has decreased because the occlusal plane rotated counterclockwise. The maxillary and mandibular incisors were slightly uprighted allowing to close the anterior openbite [Table 1].

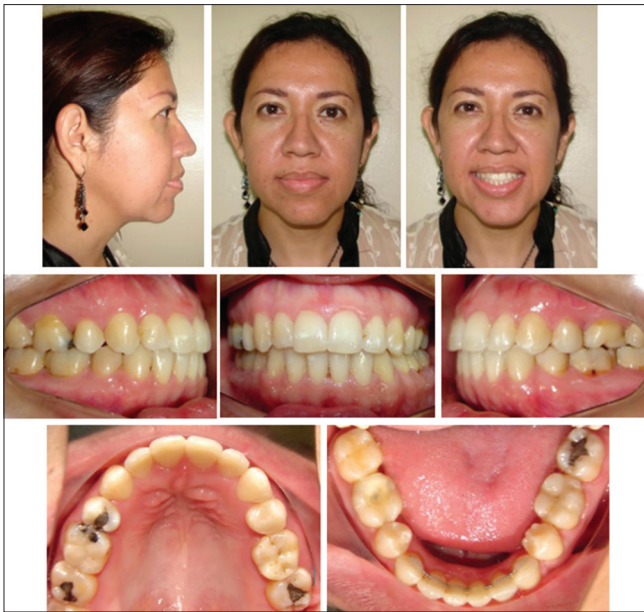After 18 months or retention, the occlusion, overjet, overbite, canine, and molar relationships were stable, as well as the cephalometric measurements and superimpositions. The maxillary incisors roots showed no further shortening after prolonged and significant tooth movement [Figures 10-13 and Table 1].

**DISCUSSION**

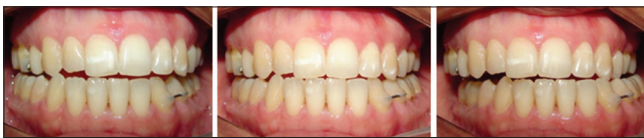The patient presented a complex malocclusion; she had undergone a previous orthodontic treatment, but she was not satisfied with the results. She wanted another orthodontic treatment to improve her appearance and self-esteem.

The patient in this case study was motivated and cooperative throughout the orthodontic treatment showing punctuality during adjustment appointments, taking care of the appliances, and practicing good oral hygiene. She paid attention to the progress of treatment and wanted to be informed. According to Breece *et al.*,<sup>[10]</sup> adult patients have a personal stake in the decision to seek treatment because they are aware of its benefits. In addition, they are much more engaged than children and adolescents, need to understand each procedure, and like to note the progress. Thus, at every appointment, the treatment progress was explained to our patient.

Before starting an orthodontic treatment, it is necessary to control any active pathology that is present, either periodontal or dental cavities. In this case report, the patient presented previous root resorption of maxillary incisors; she underwent a prior orthodontic treatment during adolescence and had no incidents of trauma. The



**Figure 6:** Final extraoral and intraoral photographs



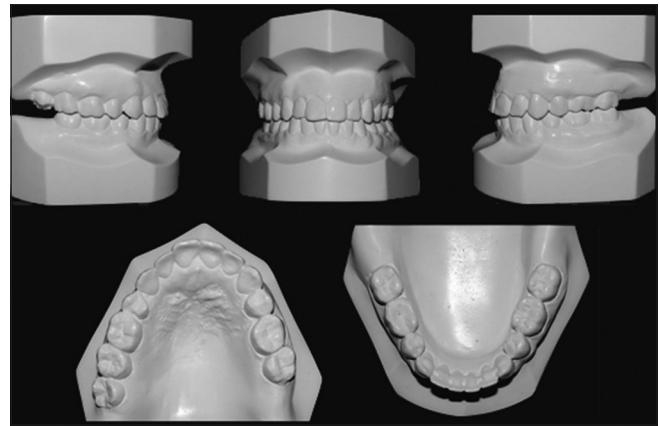
**Figure 8:** Functional movements (protrusive and lateral guidance)

etiology of root resorption is complex and multifactorial, but it seems that apical root resorption results from a combination of the genetic predisposition, individual biologic variability, and effect of mechanical factors.<sup>[11]</sup> According to Mirabella,<sup>[12]</sup> there is no association between type of initial malocclusion and development of root resorption. Vertical tooth movement is not a risk factor to develop root resorption, but it should be evaluated with care because the sample used was small.

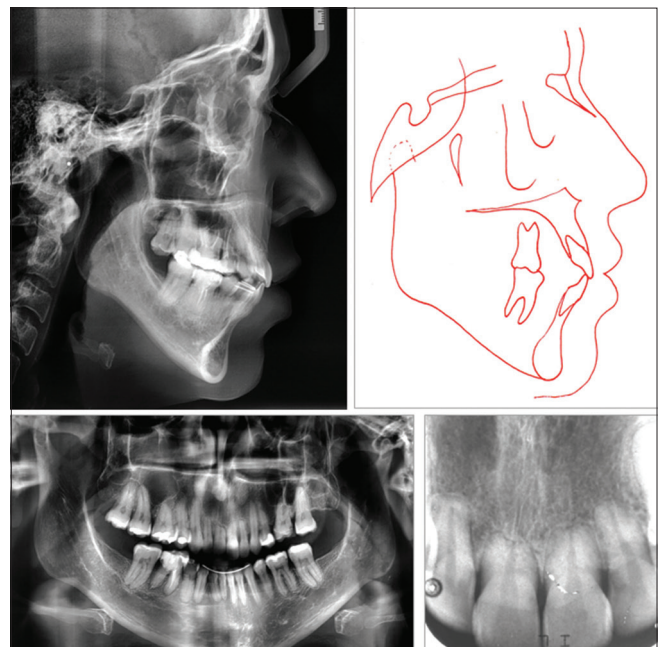
Care must be taken in orthodontic treatment involving extractions, great retraction of maxillary incisors as suggested by Maués *et al.*<sup>[13]</sup> Despite prior root resorption, the patient underwent this orthodontic treatment with success; at the end of treatment, the resorption did not increase considerably, and there were no signs of tooth mobility even with 34 months of treatment.

Light forces were used on this patient from the start of treatment to the end, and follow-up control visits were scheduled every 6–8 weeks to obtain efficient tooth movement with the mechanics applied. Tooth movement response to orthodontic forces in adults tend to be somewhat slower than in adolescents and children; however, similar tooth movement can be performed at any age.<sup>[14]</sup>

A miniscrew was placed on the patient in the area of the maxillary tuberosity, 3 mm distal to the second left maxillary molar to close the space and correct the midline deviation. Miniscrews were loaded immediately after being placed with primary stability was obtained.



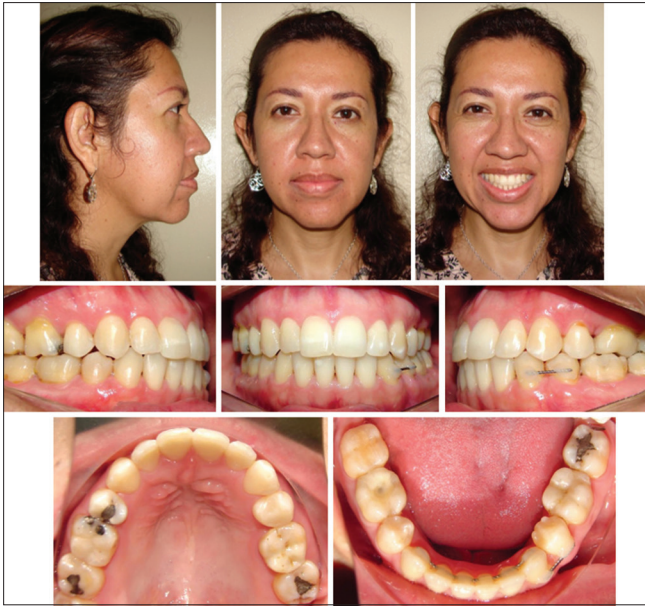**Figure 7:** Posttreatment dental casts



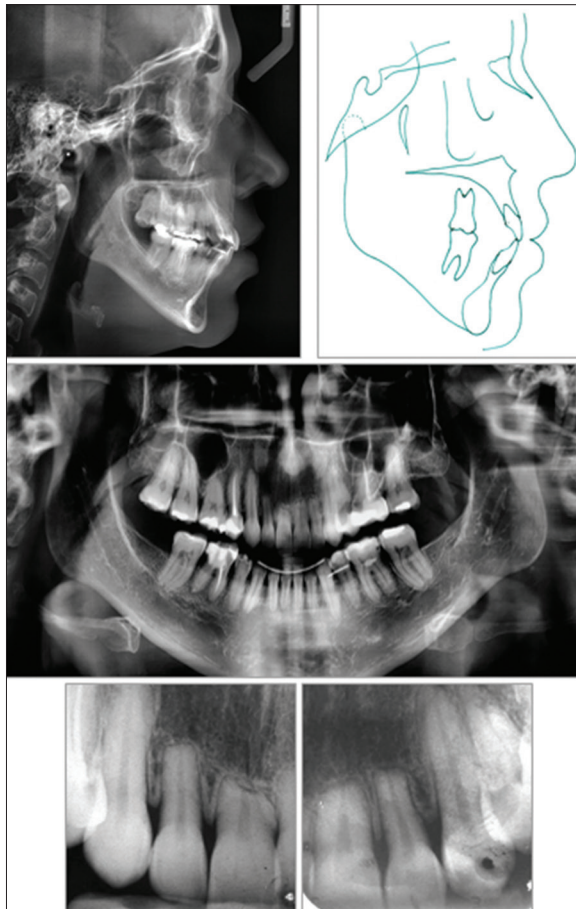
**Figure 9:** Posttreatment panoramic and periapical radiograph, cephalogram, and tracing

Extensive orthodontic treatments can be successful with adult patients. Adults cooperate throughout the treatment, are careful with the appliances and practice oral hygiene. The stability of the long-term results is high because the adult patient is aware of using retainers and continues attending appointments in the retention phase and follow-up.

The esthetic and functional improvement often justifies the risks of orthodontic treatment in a patient with shortened roots, but these risks must be clearly conveyed to the patient and family before treatment begins.<sup>[15]</sup> The improvement of occlusion, facial esthetics, oral hygiene, and adult psychological aspect is remarkable during orthodontic treatment and even more at the end of treatment. To perform tooth movement in patients, it is essential that the periodontium, although diminished, is healthy, as in the present clinical case.



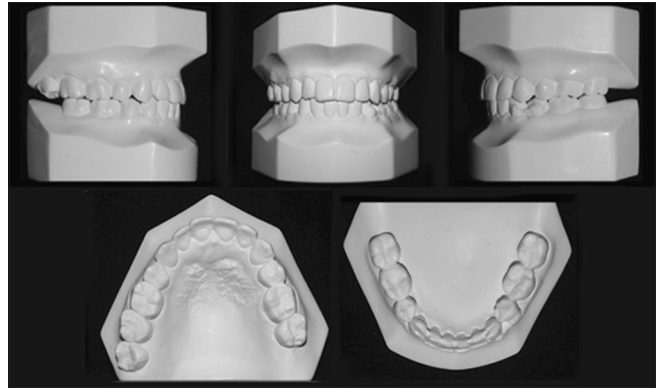
**Figure 10:** Follow-up extraoral and intraoral photographs at 18 months



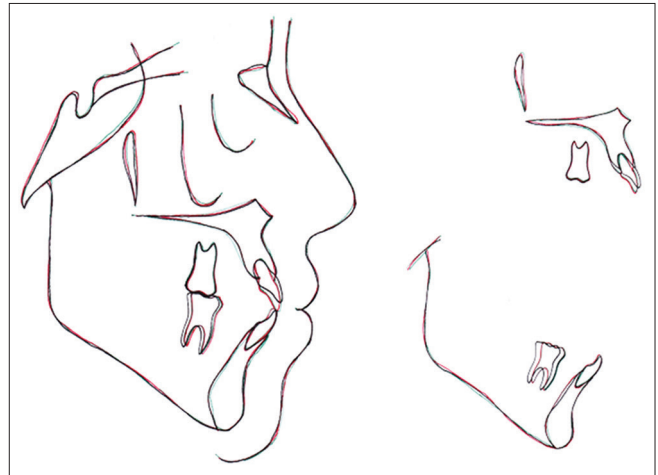
**Figure 12:** Follow-up panoramic and periapical radiograph, cephalogram, and tracing at 18 months

## CONCLUSIONS

This case report shows a treatment approach that was effective in correcting all problems of malocclusion that the adult



**Figure 11:** Follow-up dental casts at 18 months



**Figure 13:** Superimposition of the cephalometric tracings before, after treatment, and follow-up

patient presented. The treatment results have established a new functional and stable occlusion with improvement of facial esthetics, and the roots were no shorter than before treatment.

## Declaration of patient consent

The authors certify that they have obtained all appropriate patient consent forms. In the form the patient(s) has/have given his/her/their consent for his/her/their images and other clinical information to be reported in the journal. The patients understand that their names and initials will not be published and due efforts will be made to conceal their identity, but anonymity cannot be guaranteed.

## Financial support and sponsorship

Nil.

## Conflicts of interest

There are no conflicts of interest.

## REFERENCES

1. Faber J. Elderly people, quality of life, and orthodontics. *J World Fed Orthod* 2016;1:1.
2. Simon JS. Adult lingual orthodontics: A shift in our everyday routine. *Int Orthod* 2012;10:54-65.
3. Fastlicht J. Adult orthodontics. *J Clin Orthod* 1982;16:606-18.
4. Smithpeter J, Covell D Jr. Relapse of anterior open bites treated with orthodontic appliances with and without orofacial myofunctional

- therapy. *Am J Orthod Dentofacial Orthop* 2010;137:605-14.
5. Germa A, Clément C, Weissenbach M, Heude B, Forhan A, Martin-Marchand L, *et al.* Early risk factors for posterior crossbite and anterior open bite in the primary dentition. *Angle Orthod* 2016;86:832-8.
  6. Harris EF, Butler ML. Patterns of incisor root resorption before and after orthodontic correction in cases with anterior open bites. *Am J Orthod Dentofacial Orthop* 1992;101:112-9.
  7. Reynders R, Ronchi L, Bipat S. Mini-implants in orthodontics: A systematic review of the literature. *Am J Orthod Dentofacial Orthop* 2009;135:564.e1-19.
  8. Tulloch JF, Lenz BE, Phillips C. Surgical versus orthodontic correction for class II patients: Age and severity in treatment planning and treatment outcome. *Semin Orthod* 1999;5:231-40.
  9. Tucker MR. Orthognathic surgery versus orthodontic camouflage in the treatment of mandibular deficiency. *J Oral Maxillofac Surg* 1995;53:572-8.
  10. Breece GL, Nieberg LG. Motivations for adult orthodontic treatment. *J Clin Orthod* 1986;20:166-71.
  11. Weltman B, Vig KW, Fields HW, Shanker S, Kaizar EE. Root resorption associated with orthodontic tooth movement: A systematic review. *Am J Orthod Dentofacial Orthop* 2010;137:462-76.
  12. Mirabella AD, Artun J. Risk factors for apical root resorption of maxillary anterior teeth in adult orthodontic patients. *Am J Orthod Dentofacial Orthop* 1995;108:48-55.
  13. Maués CP, do Nascimento RR, Vilella Ode V. Severe root resorption resulting from orthodontic treatment: Prevalence and risk factors. *Dental Press J Orthod* 2015;20:52-8.
  14. Ong MM, Wang HL. Periodontic and orthodontic treatment in adults. *Am J Orthod Dentofacial Orthop* 2002;122:420-8.
  15. Tanaka OM, Knop LH, Shintcovsk RL, Hirata TM. Treatment of a patient with severely shortened maxillary central incisor roots. *J Clin Orthod* 2008;42:729-31.

### Author Help: Reference checking facility

The manuscript system ([www.journalonweb.com](http://www.journalonweb.com)) allows the authors to check and verify the accuracy and style of references. The tool checks the references with PubMed as per a predefined style. Authors are encouraged to use this facility, before submitting articles to the journal.

- The style as well as bibliographic elements should be 100% accurate, to help get the references verified from the system. Even a single spelling error or addition of issue number/month of publication will lead to an error when verifying the reference.
- Example of a correct style  
Sheahan P, O'leary G, Lee G, Fitzgibbon J. Cystic cervical metastases: Incidence and diagnosis using fine needle aspiration biopsy. *Otolaryngol Head Neck Surg* 2002;127:294-8.
- Only the references from journals indexed in PubMed will be checked.
- Enter each reference in new line, without a serial number.
- Add up to a maximum of 15 references at a time.
- If the reference is correct for its bibliographic elements and punctuations, it will be shown as CORRECT and a link to the correct article in PubMed will be given.
- If any of the bibliographic elements are missing, incorrect or extra (such as issue number), it will be shown as INCORRECT and link to possible articles in PubMed will be given.