

Gemcitabine-Associated Pseudocellulitis: A Great Mimicker

Sir,

Gemcitabine is a fluorine-substituted deoxycytidine analog used for different types of malignancies such as locally advanced or metastatic adenocarcinoma of pancreas, nonsmall cell lung cancer, breast cancer, epithelial ovarian cancer, and pancreatic cancer. We report a case of 64-year-old male, diagnosed case of adenocarcinoma head of pancreas, who presented to our outpatient department with acute onset of painful confluent erythematous swelling of both lower extremities extending from toes to knees [Figure 1] 2 days after receiving first cycle of gemcitabine-based chemotherapy. There was no history of recent trauma to his legs, travel in recent past, insect or tick bite, pruritus, previous similar episodes, chronic edema of lower extremities, fever with chills, and rigor which can suggest thrombotic and/or infectious cause. On examination, the patient was afebrile, local warmth and mild tenderness were present over erythematous lower extremity swellings, and dorsalis pedis pulsations were felt equally in both lower limbs. We considered infectious cellulitis, lymphedema, deep vein thrombosis (DVT), radiation recall dermatitis, and gemcitabine-induced pseudocellulitis as differential diagnosis of present clinical condition. Infectious cellulitis was excluded as systemic manifestations were absent and counts were within normal limits. Doppler ultrasound of venous system of both lower extremities was negative for DVT. Lymph edema was excluded as there was no history of swelling in the past and present swelling was sudden in onset. Since he had not received radiotherapy, radiation recall dermatitis was ruled out. Consequently, diagnosis of gemcitabine-induced pseudocellulitis was made.

Although areas of impaired lymphatic drainage lead to drug permeation into interstitial fluid, drug accumulating in subcutaneous tissue and inadequate drug inactivation in the subcutaneous tissue leading to nonnecrotizing inflammation of dermis and hypodermis from a noninfectious etiology has been hypothesized as pathophysiology behind gemcitabine-related pseudocellulitis.^[1] However, it can develop even in the absence of pre-existing lymphedema in that specific area. These reactions usually occur within 12–24 h following gemcitabine exposure,^[2] and bilateral lower extremity symptoms are seen. It is a self-limiting condition with most cases showing full resolution within 48 h to 1 week.^[2] Conservative management was planned and the patient was advised bed rest and nonsteroidal anti-inflammatory drugs. Other treatment options such as diphenhydramine^[2] and 0.1% triamcinolone acetonide cream under occlusion and compression stockings^[3] have been used for symptomatic management of this toxic effect of gemcitabine. No further investigations including biopsy specimen for histopathological examination and tissue culture were done as part of diagnostic workup as done earlier.^[3] Antibiotics including oral cephalosporins,

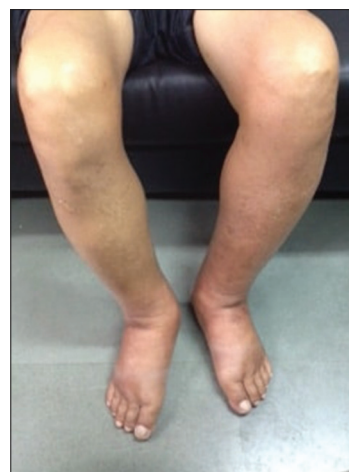


Figure 1: Patient with confluent erythema and edema on bilateral lower extremities

clindamycin, and even intravenous vancomycin were not administered as the patient did not manifest any clinical feature of infection like fever or raised total leukocyte count as done in previous reported cases.^[3] The swelling gradually subsided over the next 3 days and the patient was discharged in stable condition. Later, when the patient was followed up in outpatient clinic, pain and swelling had subsided, and there were no further complaints. Thus, we propose that triad of temporal relationship between administration of gemcitabine and appearance of lesions, absence of fever, normal total leukocyte is sufficient for diagnosis of pseudocellulitis. Knowledge, awareness, and recognition by keeping high suspicion of this adverse effect will help clinicians to make a correct diagnosis and prevent unwarranted diagnostic tests. Conservative management but not the withdrawal of gemcitabine-based chemotherapy is only required rather than administration of antibiotics.

Declaration of patient consent

The authors certify that they have obtained all appropriate patient consent forms. In the form the patient(s) has/have given his/her/their consent for his/her/their images and other clinical information to be reported in the journal. The patients understand that their names and initials will not be published and due efforts will be made to conceal their identity, but anonymity cannot be guaranteed.

Financial support and sponsorship

Nil.

Conflicts of interest

There are no conflicts of interest.

Deepti Ahuja, Sachidanand Jee Bharati

*Department of Onco-Anesthesia and Palliative Medicine,
Dr. B.R.A IRCH, All India Institute of Medical Sciences,
New Delhi, India*

Address for correspondence:
 Dr. Sachidanand Jee Bharati,
 Dr. B.R.A IRCH, All India Institute of Medical Sciences,
 New Delhi - 110 029, India.
 E-mail: sachidadr@yahoo.co.in

References

1. Tan DH, Bunce PE, Liles WC, Gold WL. Gemcitabine-related “pseudocellulitis”: Report of 2 cases and review of the literature. *Clin Infect Dis* 2007;45:e72-6.
2. Strouse C, Epperla N. A rash diagnosis: Gemcitabine-associated pseudocellulitis. *J Oncol Pharm Pract* 2017;23:157-60.
3. Asemota E, Reid E, Kovarik C. Gemcitabine-induced pseudocellulitis in a patient with non-small cell lung carcinoma. *JAAD Case Rep* 2015;1:178-81.

This is an open access journal, and articles are distributed under the terms of the Creative Commons Attribution-NonCommercial-ShareAlike 4.0 License, which allows others to remix, tweak, and build upon the work non-commercially, as long as appropriate credit is given and the new creations are licensed under the identical terms.

Access this article online	
Quick Response Code: 	Website: www.ijmpo.org
	DOI: 10.4103/ijmpo.ijmpo_119_17

How to cite this article: Ahuja D, Bharati SJ. Gemcitabine-associated pseudocellulitis: A great mimicker. *Indian J Med Paediatr Oncol* 2018;39:553-4.

© 2018 Indian Journal of Medical and Paediatric Oncology | Published by Wolters Kluwer - Medknow