

A Man with Headache

A 49-year-old male presented with intermittent headache and fever. He is a diagnosed case of acute myeloid leukemia posthaploidentical allogenic stem cell transplantation with graft-versus-host disease, cytomegalovirus infection, and pancytopenia secondary to gancyclovir and ruxolitinib. There was tenderness over right maxillary, frontal, and ethmoidal regions. Magnetic resonance imaging showed enhancing soft tissue thickening along medial wall of right orbit with thinning of medial wall of right orbit and right cribriform plate. Black crust was found in nasal cavity and sinuses.

Figure 1 shows hematoxylin and eosin-stained section of the crust with $\times 100$ magnification.

What Is the Diagnosis?

Answer

For answer to the above question, please refer to page no. 317.

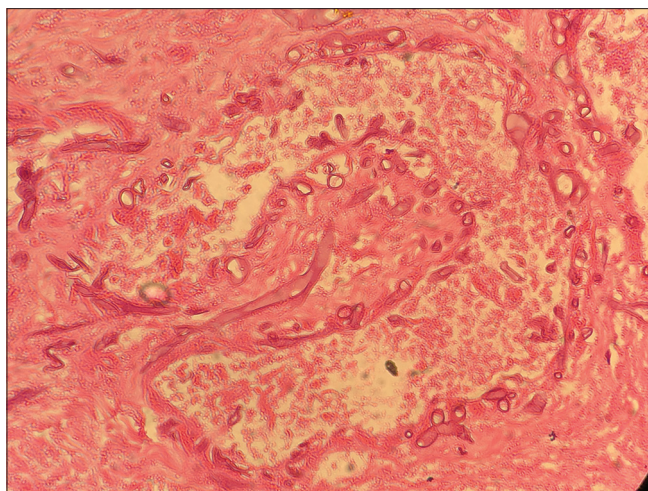


Figure 1: Histology H and E stain

Financial support and sponsorship

Nil.

Conflicts of interest

There are no conflicts of interest.

**Padmaj Kulkarni, Mahesh Mandolkar¹,
Rashmi Agarwal¹, Nilanjan Bhowmick²,
Sameer Melinkeri³**

*Departments of Medical Oncology, ¹Pathology, ²ENT and
³Clinical Hematology, Deenanath Mangeshkar Hospital,
Pune, Maharashtra, India*

Address for correspondence:

*Dr. Padmaj Kulkarni,
Department of Medical Oncology, Deenanath Mangeshkar Hospital,
Pune, Maharashtra, India.
E-mail: padmaj.kulkarni@gmail.com*

This is an open access journal, and articles are distributed under the terms of the Creative Commons Attribution-NonCommercial-ShareAlike 4.0 License, which allows others to remix, tweak, and build upon the work non-commercially, as long as appropriate credit is given and the new creations are licensed under the identical terms.

Access this article online

Quick Response Code:



Website:

www.ijmpo.org

DOI:

10.4103/ijmpo.ijmpo_169_19

How to cite this article: Kulkarni P, Mandolkar M, Agarwal R, Bhowmick N, Melinkeri S. A man with headache. Indian J Med Paediatr Oncol 2019;40:282.