

A Lady with Hypogastric Mass

A 56-year-old woman presented with bleeding from a mass in the hypogastric region of 2 months' duration. Clinical evaluation revealed a round, polypoid, irregular, friable mass in the hypogastric region [Figure 1], which also affected the clitoris and the labia majora. The lesion bled on palpation.

Vagina and the external cervical os were recognized, though the external urethral meatus could not be clearly visualized. The left ureteral opening was clearly seen, but the right ureteral opening could not be well identified. Bilateral inguinal lymph nodes were not palpable.

Contrast-enhanced computed tomography of the abdomen and pelvis demonstrated marked widening of pubic symphysis with a lesion of 6.7 cm × 6.1 cm × 4 cm involving the undersurface (anteroinferior) of the urinary bladder extending up to the introitus [Figure 2]. Anterior vaginal wall appeared thickened with the involvement

of its lower third with loss of fat plane with the anterior cervical wall as well. Both the ureters were well opacified in the delayed images and appeared dilated and tortuous throughout the entire course with inferiorly located ureterovesical junctions. The excreted contrast leaked through the posteroinferior and anterior aspects of the bladder [Figure 3].

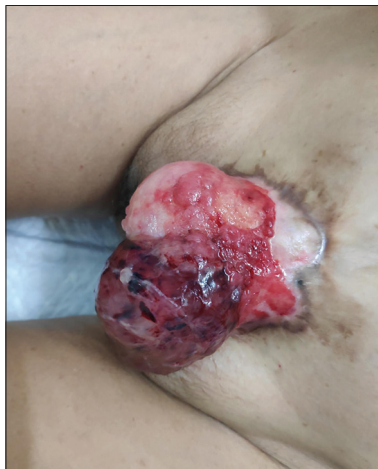

Figure 1: Clinical photograph

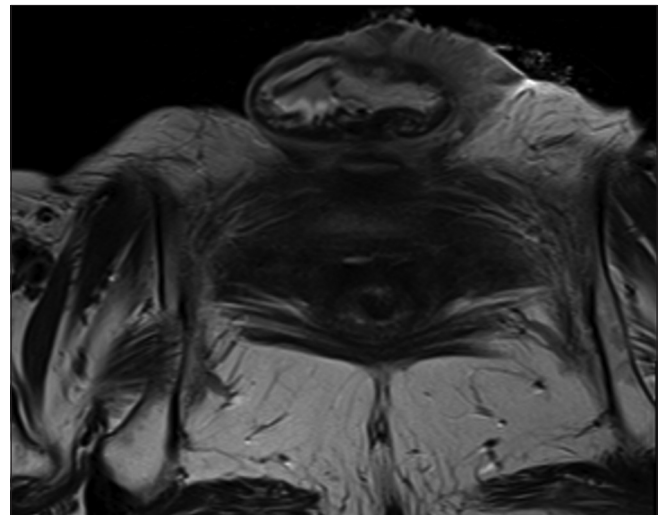


Figure 2: MRI

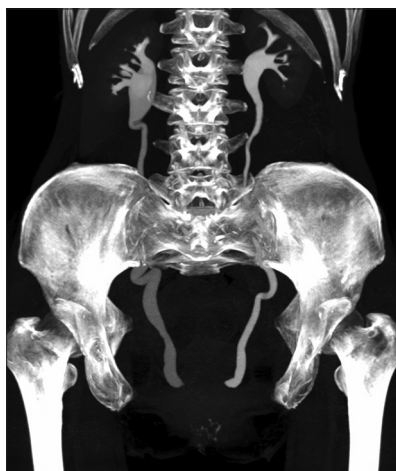

Figure 3: Excretion of contrast

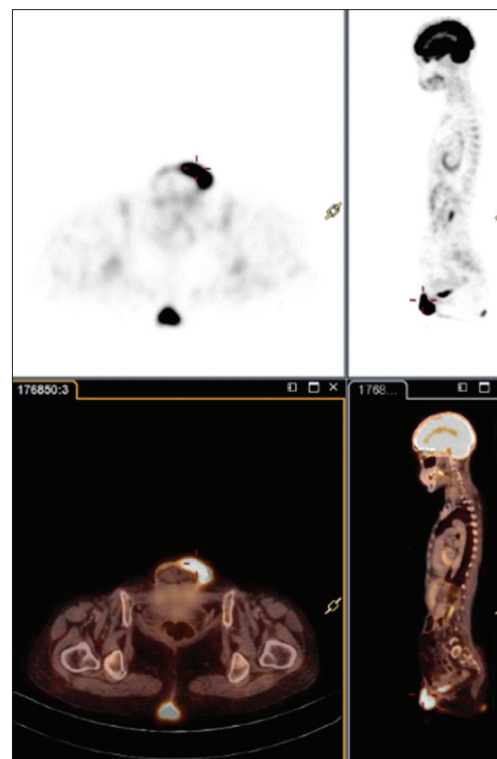


Figure 4: PET-CT

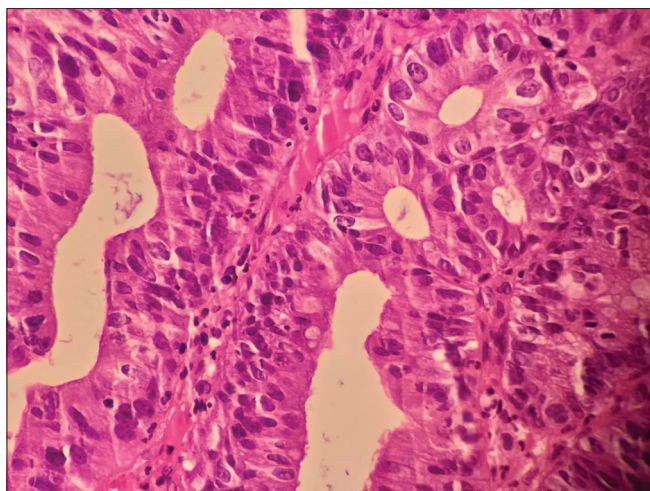


Figure 5: Histology H and E

Positron emission tomography demonstrated a 4.8 cm × 2.5 cm lesion with standard uptake value of 29.57 in the region of urinary bladder. Hydroureter was noted on either side in lower part with no distal metastases [Figure 4].

Biopsy of the mass showed well-differentiated adenocarcinoma. The tumor cells showed positivity for CK-7, CK-20, and CDX-2 and were negative for GATA3 and p63 [Figure 5]. Routine laboratory investigations were within normal limits.

1. What is the diagnosis?
2. What is the primary treatment?
3. What should be the adjuvant treatment?

Answers

For answers to the above questions, please refer to page no. 316.

Financial support and sponsorship

Nil.

Conflicts of interest

There are no conflicts of interest.

**Padmaj Kulkarni, Shruti Gandhi,
Asha Gokhale¹, Subodh Shivde²,
Bhalchandra Kashyapi², Shefali Purandare³,
Sujit Nilegaonkar⁴, Sanjay Desai⁵**

*Departments of Medical Oncology, ¹Obstetrics and Gynaecology,
²Urology, ³Pathology, ⁴Nuclear Medicine and ⁵Radiodiagnosis, Deenanath
Mangeshkar Hospital, Pune, Maharashtra, India*

*Address for correspondence: Dr. Padmaj Kulkarni,
Department of Medical Oncology, Deenanath Mangeshkar Hospital,
Pune, Maharashtra, India.*

E-mail: padmaj.kulkarni@gmail.com

This is an open access journal, and articles are distributed under the terms of the Creative Commons Attribution-NonCommercial-ShareAlike 4.0 License, which allows others to remix, tweak, and build upon the work non-commercially, as long as appropriate credit is given and the new creations are licensed under the identical terms.

Access this article online	
Quick Response Code: 	Website: www.ijmpo.org
	DOI: 10.4103/ijmpo.ijmpo_170_19

How to cite this article: Kulkarni P, Gandhi S, Gokhale A, Shivde S, Kashyapi B, Purandare S, et al. A lady with hypogastric mass. Indian J Med Paediatr Oncol 2019;40:277-8.