

## Clinico-radiological and Pathological Characteristics of Inflammatory Myofibroblastic Tumors in Children: A Retrospective Study

### Abstract

**Purpose:** Inflammatory myofibroblastic tumors (IMTs) are rare, benign lesions most often seen in the lung of young adults but can occur in children, in various sites. They mimic, clinically and radiologically, malignant tumors – especially sarcomas and lymphomas. The aim was to review the clinical, radiological, and pathological data of children with a diagnosis of IMT referred to our department. **Materials and Methods:** This retrospective study was conducted at the Department of Medical and Paediatric Oncology, Regional Cancer Centre, Sher-I-Kashmir Institute of Medical Sciences, Srinagar, Jammu and Kashmir, India from January 2014 to December 2015. **Results:** Among 288 pediatric tumors registered during the study, 5 (1.73%) had the diagnosis of IMTs. The main symptoms were abdominal distension and pain in 60% (three cases), breathlessness and cough in 20% (one case), and right axillary area swelling in 20% (one case). In three patients, complete surgical excision was done, whereas another patient with retroperitoneal mass had the residual disease and received chemotherapy followed by complete second surgery. In the case of mediastinal IMT, surgery was followed by local radiotherapy. At present, four patients are disease-free and one patient with mediastinal IMT has the residual progressive disease. **Conclusion:** On presentation, IMT can constitute a formidable challenge, from diagnosis through to treatment.

**Keywords:** Inflammatory myofibroblastic tumors, macrolides, pseudotumors, steroids, tyrosine kinase

### Introduction

Inflammatory myofibroblastic tumor (IMT) is a rare clinical entity that encompasses a wide spectrum of myofibroblastic proliferation along with a varied amount of inflammatory infiltrate. First described by Brunn *et al.* in 1939 as a primary lung tumor, IMT can occur in nearly any body organ.<sup>[1]</sup> Previously called by many names such as inflammatory pseudotumor, fibrous xanthoma, pseudosarcoma, lymphoid hamartoma, and inflammatory myofibrohistiocytic proliferation the diverse nomenclature is mostly descriptive and reflects the uncertainty regarding true biologic nature of these lesions.<sup>[2]</sup> The term “inflammatory pseudotumor” was coined by Umiker *et al.* in 1954 who described four inflammatory tumors of the lung simulating xanthoma, fibroma, or plasma cell tumor. IMTs predominantly occur in children and young adults, but any age group can be affected.<sup>[3]</sup> IMTs occur more commonly in women. Although considered as benign tumors, IMTs have a propensity

toward recurrence and persistent local growth.

The pathologically IMT is composed of cytologically bland spindle myofibroblasts with admixed inflammatory cells.<sup>[4]</sup> The spindle cells contain large vesicular oval nuclei with no hyperchromasia and small nucleoli. Variable amounts of pale eosinophilic cytoplasm and variable number of mitotic figures may be seen. Inflammatory cells are predominantly lymphocytes and plasma cells but may include neutrophils and eosinophils also. These cells may form germinal centers. Foamy histiocytes are occasionally present.<sup>[5]</sup> The patterns of cell mixtures may either take the form of loose or myxoid stroma with prominent vascularity or compact spindle cells or densely collagenous with fewer spindle cells and inflammatory cells.<sup>[6,7]</sup> Immunohistochemistry reveals reactivity of IMTs to actin in the majority of the cases and to vimentin in all cases reflecting the myofibroblastic nature of the cells.<sup>[8-10]</sup> Cytokeratin and desmin may be reactive in some cases.

**Mohamad Hussain Mir,  
Waseem Dar,  
Sheikh Aejaz Aziz,  
Gul Mohamad,  
Burhan Wani**

Department of Medical  
Oncology, Sher-I-Kashmir  
Institute of Medical Sciences,  
Srinagar, Jammu and Kashmir,  
India

### Address for correspondence:

Dr. Waseem Dar,  
Department of Medicine,  
Oncology Division,  
Sher-I-Kashmir Institute  
of Medical Sciences,  
Soura, Srinagar - 190 011,  
Jammu and Kashmir, India.  
E-mail: drwaseem.mw@gmail.  
com

### Access this article online

Website: [www.ijmpo.org](http://www.ijmpo.org)

DOI: 10.4103/ijmpo.ijmpo\_178\_16

### Quick Response Code:



**How to cite this article:** Mir MH, Dar W, AejazAziz S, Mohamad G, Wani B. Clinico-radiological and pathological characteristics of inflammatory myofibroblastic tumors in children: A retrospective study. Indian J Med Paediatr Oncol 2017;38:261-5.

This is an open access article distributed under the terms of the Creative Commons Attribution-NonCommercial-ShareAlike 3.0 license, which allows others to remix, tweak, and build upon the work non-commercially, as long as the author is credited and the new creations are licensed under the identical terms.

For reprints contact: [reprints@medknow.com](mailto:reprints@medknow.com)

## Aims and objectives

1. To describe the prevalence and clinical, radiological, and pathological characteristics of inflammatory fibroblastic tumors in children.

## Materials and Methods

This study was carried out in the Department of Medical Oncology Sher-I-Kashmir Institute of Medical Sciences, Srinagar, India, which is one of the astute tertiary care centers in North India with a dedicated Regional Cancer Centre (RCC) catering to the needs of more than 13 million people. In this study, all the pediatric cancer patients registered with RCC from January 2014 to December 2015 were included in the study. All the clinical signs and symptoms and relevant diagnostic methods and their results of patients with a diagnosis of the inflammatory fibroblastic tumor were documented, and their treatment details noted.

## Results

Among 288 pediatric tumors registered during the study, 5 (1.73%) had the diagnosis of IMTs. There were three male and two female children (M:f ratio 1.5:1). The mean age was 5.32 years (range: 2–9 years). The main symptoms were abdominal distension and pain in 60% (three cases), breathlessness and cough in 20% (one case), and right axillary area swelling in 20% (one case). On computed tomography of chest and abdomen, one patient had mediastinal widening with the impression of lymphoma, two patients were labeled as having retroperitoneal sarcoma, and one patient had an ileal growth with the impression of Burkitt lymphoma [Figures 1-3].

In one patient with right axillary swelling, lymphoma was suspected. In only one patient (20%), initial histopathology was reported as IMT (retroperitoneal lesion), whereas in rest of the cases, it was only after review with immunohistochemistry from an oncopathologist that diagnosis of IMT was made. On immunohistochemistry, in all patients, tumor cells were strongly positive for smooth muscle actin, desmin, and anaplastic lymphoma kinase (ALK)-1 and negative for CD-34, CD-117, discovered on GIST and S100. In three patients, complete surgical excision was done (one with axillary mass and two with abdominal disease). One patient with retroperitoneal mass had residual disease and received chemotherapy followed by complete second surgery. In the case of mediastinal IMT, surgery was followed by local radiotherapy. At present, four patients are disease-free and one patient with mediastinal IMT has residual progressive disease. The summary of this study is given in Table 1.

## Discussion

IMT is a rare tumor of childhood and adolescence. Although they occur predominantly in lung, they may occur in any organ. Extrapulmonary IMT occurs commonly in the abdomen or in soft tissues but may occur anywhere.

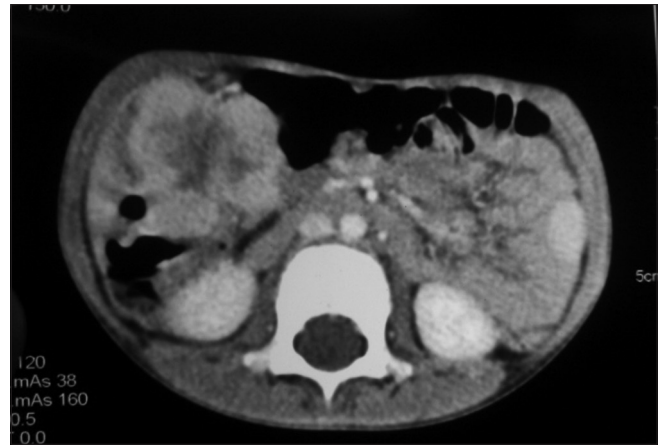


Figure 1: Contrast-enhanced computed tomography of abdomen and pelvis revealed a 7 cm × 5 cm × 5 cm lobulated hyper enhancing mass lesion with central necrosis arising from bowel wall extraluminally in ileocecal area suggestive of gut lymphoma

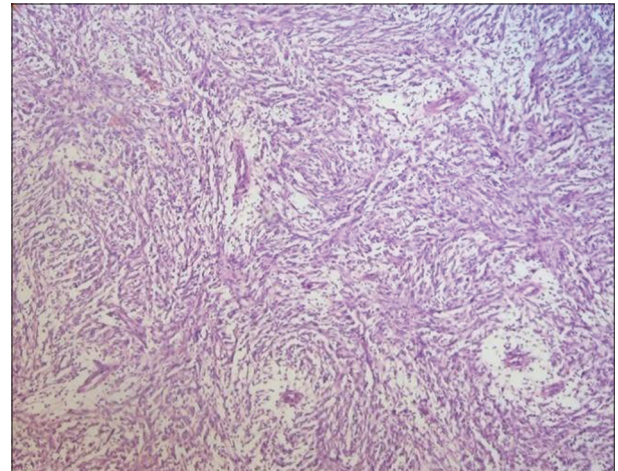


Figure 2: Low power view of Histopathological examination (HPE) showing spindle cells with inflammatory background of plasma cells, lymphocytes, and neutrophils

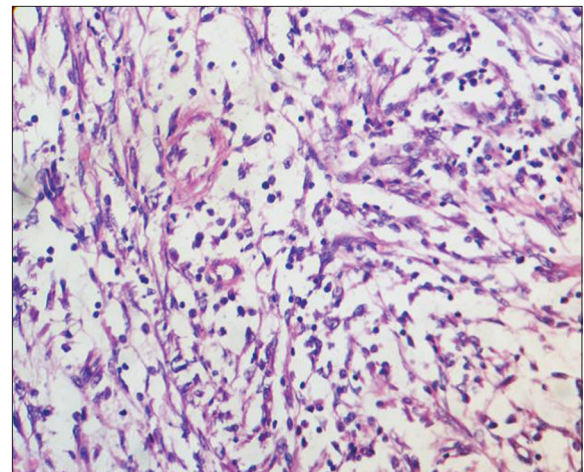


Figure 3: High power view of HPE showing spindle cells with inflammatory background of plasma cells lymphocytes and neutrophils

Surprisingly, in our study, there was no pulmonary IMT; instead, there was one mediastinal IMT, two retroperitoneal,

**Table 1: Clinico-radiological characteristics of inflammatory myofibroblastic tumor patients in our study**

Patients characteristic	Case 1	Case 2	Case 3	Case 4	Case 5
Sex	Male	Male	Female	Male	Female
Signs and symptoms	Abdominal distension pain	Breathlessness cough	Abdominal distension pain	Abdominal distension pain	Right axillary area swelling
Radiology	Retroperitoneal mass	Mediastinal Widening with CT suggestive of lymphoma	Retroperitoneal mass	Ileocecal growth	
Immunohistochemistry	Strongly positive for SMA, desmin, and ALK-1 and negative for CD-34, CD-117, DOG-1 and S100	Strongly positive for SMA, desmin, and ALK-1 and negative for CD-34, CD-117, DOG-1 and S100	Strongly positive for SMA, desmin, and ALK-1 and negative for CD-34, CD-117, DOG-1 and S100	Strongly positive for SMA, desmin, and ALK-1 and negative for CD-34, CD-117, DOG-1 and S100	Strongly positive for SMA, desmin, and ALK-1 and negative for CD-34, CD-117, DOG-1 and S100
Treatment	Complete surgical excision	Surgery followed by local radiotherapy	Surgery followed by chemotherapy and then second surgery	Complete surgical excision	Complete surgical excision
Follow up	Disease free	Residual disease	Disease free	Disease free	Disease free

CT – Computed tomography; SMA – Smooth muscle actin; ALK – Anaplastic lymphoma kinase; DOG – Discovered on GIST

one axillary, and one ileocecal. This may be due to overall low prevalence of IMTs. These lesions are great mimickers and may escape diagnosis.<sup>[11]</sup> Oeconomopoulou *et al.* reported a young child who was initially diagnosed to have acute appendicitis but on laparotomy was found to have a tumor that was histology and immunohistochemistry was found to be IMT. Similarly, in our case, none of the patients was initially suspected to have IMT. In fact, ileal IMT in our study was reported as lymphoma initially and only on review histopathology and immunohistochemistry was found to be IMT.<sup>[12]</sup> Yang *et al.* reported a 56-year-old man with IMT at the left carotid bifurcation accompanied by recurrent syncope and falls. The patient underwent surgery after which corticosteroids and antibiotics were administered for a short-term. No recurrence was observed during the 2-year follow-up.<sup>[13-16]</sup> Other unusual presentations include breast lumps, maxillary sinus tumors, renal masses, pemphigus, etc.<sup>[17-19]</sup> Sometimes, they may occur with another clinical condition like sclerosing cholangitis or as a part of double malignancy such as Hodgkin's lymphoma, small cell lung cancer, Wilms tumor, and many others.

The signs and symptoms of IMTs largely depend on the site of involvement.<sup>[20,21]</sup> Occasionally, they may be completely silent, discovered incidentally on routine imaging or on the evaluation of an inflammatory response at laboratory examination. Grossly, the tumors are circumscribed but not encapsulated and appear as white tan masses with whorled fleshy or myxoid cut surface and may have focal hemorrhage, necrosis, or calcification. Average size is 6 cm. Microscopically these tumors comprise myofibroblastic and fibroblastic spindle cells with inflammatory infiltrate of lymphocytes, plasma cells, eosinophils, and histiocytes against a background of abundant blood vessels. Three patterns have been described. In one pattern, there are

elongated myofibroblasts containing abundant eosinophilic cytoplasm and vesicular nuclei, loose myxoid stroma with neutrophils, lymphocytes, and eosinophils, but few plasma cells. Another pattern comprises spindled myofibroblasts and fibroblasts in more compact stroma, arranged as islands surrounded by fibromyxoid stroma with prominent plasma cells and mitotic figures. The third pattern has a densely hyalinized stroma with a few spindle cells; a few plasma cells or lymphocytes. All three patterns have no nuclear pleomorphism and no atypical mitotic figures. Malignant behavior is associated with highly atypical polygonal cells with oval nuclei, prominent nucleoli, Reed–Sternberg-like cells and atypical mitotic figures.<sup>[22,23]</sup> Approximately 50%–70% of the tumors harbor an ALK gene rearrangement, leading to the formation of a chimeric fusion protein, which is detectable by immunohistochemistry or FISH. ALK is a receptor-type protein tyrosine kinase, which is rendered oncogenic either as a result of a gene fusion, such as in anaplastic large cell lymphoma, lung cancer, and IMT or due to a missense mutation as seen in neuroblastoma and anaplastic thyroid cancer.<sup>[24]</sup> ALK expression and/or ALK gene rearrangement was previously described as a good prognostic marker in IMT, with positive cases showing a better outcome, whereas ALK-negative IMTs being more aggressive with a higher frequency of metastasis compared with ALK-positive IMT. Previously, due to its markedly variable phenotype and lack of objective immunoprofile, the diagnosis of ALK-negative IMTs has been often a diagnosis of exclusion. In a recent study using next generation sequencing, six of nine ALK-negative IMT tumors showed the presence of fusions in ALK, ROS1, or PDGFRB, suggesting that IMT is largely a kinase fusion – driven neoplasm. The study was initiated by the dramatic response to the ROS1 inhibitor crizotinib in an index case of a treatment-refractory ALK-negative IMT pediatric patient.

There are no clear guidelines regarding the treatment of IMTs. The heterogeneity of these tumors is reflected by the number of treatment options employed by physicians worldwide ranging from surgery to steroids to immunomodulators. Since IMTs usually mimic other tumors in presentation, surgery is usually employed initially with further treatment options followings histopathological diagnosis and immunohistochemistry and cytogenetics. Chemotherapy is recommended when IMT is multifocal, invasive or shows local recurrence.<sup>[25-28]</sup> It is often a combination of agents including methotrexate, cisplatin, vinorelbine, Adriamycin, carboplatin, and paclitaxel given with a view of achieving complete remission. Since IMTs involve an inflammatory response, several clinicians have employed nonsteroidal anti-inflammatory agents in their management and found good results.<sup>[29]</sup> Chaves *et al.* investigated the anti-inflammatory action of nonsteroidal anti-inflammatory drugs (NSAIDs). The authors analyzed reports of ALK-negative cases receiving NSAID therapy and reported the striking result that NSAIDs were effective in treating ten of 11 cases of IMT. Besides several cases of IMTs have been treated with antibiotics alone. Since Macrolide antibiotics are known to possess unique anti-inflammatory activities, they have been used as a treatment option in the management of IMTs.<sup>[30]</sup> Watanabe *et al.* reported a 73-year-old female patient with ALK-negative primary pulmonary IMT who went into remission on treatment with clarithromycin.<sup>[31]</sup> Similarly, Alezra *et al.* reported a case of an 8-year-old girl with documented bladder IMT that resolved completely after antibiotic therapy. Since tyrosine kinase mutations are found in IMTs crizotinib has been used by some physicians in the treatment of chemotherapy-resistant disease.

## Conclusion

IMT is a unique clinical condition that has confused clinicians and pathologists alike. The disease has a significant diversity in clinical presentation, behavior, histopathology, and treatment options. Although in some cases, the disease may even regress spontaneously, in majority treatment in the form of surgery, chemotherapy, steroids, or immunomodulators is employed; the latter options employed when disease shows local recurrence or distant metastasis.

## Financial support and sponsorship

Nil.

## Conflicts of interest

There are no conflicts of interest.

## References

1. Brunn H. Two interesting benign lung tumors of contradictory histopathology. *J Thorac Surg* 1939;9:119-31.
2. Umiker WO, Iverson L. Postinflammatory tumors of the lung; report of four cases simulating xanthoma, fibroma, or plasma cell tumor. *J Thorac Surg* 1954;28:55-63.
3. Hojo H, Newton WA Jr., Hamoudi AB, Qualman SJ, Wakasa H, Suzuki S, *et al.* Pseudosarcomatous myofibroblastic tumor of the urinary bladder in children: A study of 11 cases with review of the literature. An Intergroup Rhabdomyosarcoma Study. *Am J Surg Pathol* 1995;19:1224-36.
4. Kenneth A, Jonathan H, Virgil G, Liang C, Edward C, Roxann N, *et al.* Inflammatory pseudotumor and sarcoma of urinary bladder: Differential diagnosis and outcome in thirty-eight spindle cell neoplasms. *Mod Pathol* 2001;14:1043-51.
5. Coffin CM, Watterson J, Priest JR, Dehner LP. Extrapulmonary inflammatory myofibroblastic tumor (inflammatory pseudotumor). A clinicopathologic and immunohistochemical study of 84 cases. *Am J Surg Pathol* 1995;19:859-72.
6. Horn LC, Reuter S, Biesold M. Inflammatory pseudotumor of the ureter and the urinary bladder. *Pathol Res Pract* 1997;193:607-12.
7. Ro JY, el-Naggar AK, Amin MB, Sahin AA, Ordonez NG, Ayala AG. Pseudosarcomatous fibromyxoid tumor of the urinary bladder and prostate: Immunohistochemical, ultrastructural, and DNA flow cytometric analyses of nine cases. *Hum Pathol* 1993;24:1203-10.
8. Roth JA. Reactive pseudosarcomatous response in urinary bladder. *Urology* 1980;16:635-7.
9. Sonobe H, Okada Y, Sudo S, Iwata J, Ohtsuki Y. Inflammatory pseudotumor of the urinary bladder with aberrant expression of cytokeratin. Report of a case with cytologic, immunocytochemical and cytogenetic findings. *Acta Cytol* 1999;43:257-62.
10. Huang WL, Ro JY, Grignon DJ, Swanson D, Ordonez NG, Ayala AG. Postoperative spindle cell nodule of the prostate and bladder. *J Urol* 1990;143:824-6.
11. Oeconomopoulou A, de Verney Y, Kanavaki K, Stefanaki K, Pavlakis K, Salakos C. Inflammatory myofibroblastic tumor of the small intestine mimicking acute appendicitis: A case report and review of the literature. *J Med Case Rep* 2016;10:100.
12. Yang L, Li W, Zhang H. Inflammatory myofibroblastic tumor of carotid artery resulting in recurrent syncope: A case report. *Head Neck* 2016;38:E2461-3.
13. Zhang X, Miao Y, Zhou WW, Xing RG. Inflammatory myofibroblastic tumor in breast: A clinicopathologic study of 2 cases. *Zhonghua Bing Li Xue Za Zhi* 2016;45:260-1.
14. Kim JS, Hong KH, Kim JS, Song JH. Medical therapy of maxillary sinus inflammatory myofibroblastic tumors. *Am J Otolaryngol* 2016;37:376-8.
15. Halpert E, Figueroa JL, Rojas A, Ortiz CI, Chaparro D, Galindo M, *et al.* Inflammatory myofibroblastic tumor presenting as paraneoplastic pemphigus in a 7-year-old girl. *JAAD Case Rep* 2016;2:37-40.
16. Kapusta LR, Weiss MA, Ramsay J, Lopez-Beltran A, Srigley JR. Inflammatory myofibroblastic tumors of the kidney: A clinicopathologic and immunohistochemical study of 12 cases. *Am J Surg Pathol* 2003;27:658-66.
17. Gough J, Chakrabarti S. Inflammatory pseudotumor of the liver in a patient with chronic sclerosing cholangitis. *Am J Gastroenterol* 1993;88:1452-3.
18. Thomas RM, Jaffe ES, Zarate-Osorno A, Medeiros LJ. Inflammatory pseudotumor of the spleen. A clinicopathologic and immunophenotypic study of eight cases. *Arch Pathol Lab Med* 1993;117:921-6.
19. Newbould MJ, Kelsey A, Lendon M, Gururangan S. Inflammatory pseudotumor of the liver masquerading as a metastasis in a child treated for neuroblastoma. *Med Pediatr Oncol* 1992;20:172-5.
20. Johnson K, Notrica DM, Carpentieri D, Jaroszewski D,

- Henry MM. Successful treatment of recurrent pediatric inflammatory myofibroblastic tumor in a single patient with a novel chemotherapeutic regimen containing celecoxib. *J Pediatr Hematol Oncol* 2013;35:414-6.
21. Salameh M, Sultan I, Barbar M, Al Hussaini M, Jameel A, Ghandour K, *et al.* yor causing unexplained anemia in a toddler: A case report. *J Med Case Rep* 2011;5:69.
  22. Coffin CM, Hornick JL, Fletcher CD. Inflammatory myofibroblastic tumor: Comparison of clinicopathologic, histologic, and immunohistochemical features including ALK expression in atypical and aggressive cases. *Am J Surg Pathol* 2007;31:509-20.
  23. Chan JK, Cheuk W, Shimizu M. Anaplastic lymphoma kinase expression in inflammatory pseudotumors. *Am J Surg Pathol* 2001;25:761-8.
  24. Lovly CM, Gupta A, Lipson D, Otto G, Brennan T, Chung CT, *et al.* Inflammatory myofibroblastic tumors harbor multiple potentially actionable kinase fusions. *Cancer Discov* 2014;4:889-95.
  25. Choe JY, Go H, Jeon YK, Yun JY, Kim YA, Kim HJ, *et al.* Inflammatory pseudotumor-like follicular dendritic cell sarcoma of the spleen: A report of six cases with increased IgG4-positive plasma cells. *Pathol Int* 2013;63:245-51.
  26. Bosse K, Ott C, Biegner T, Fend F, Siegmann-Luz K, Wallwiener D, *et al.* 23-year-old female with an inflammatory myofibroblastic tumour of the breast: A case report and a review of the literature. *Geburtshilfe Frauenheilkd* 2014;74:167-70.
  27. Bhagat P, Bal A, Das A, Singh N, Singh H. Pulmonary inflammatory myofibroblastic tumor and IgG4-related inflammatory pseudotumor: A diagnostic dilemma. *Virchows Arch* 2013;463:743-7.
  28. Tao YL, Wang ZI, Han JG, Wei P. Inflammatory myofibroblastic tumor successfully treated with chemotherapy and nonsteroidals: A case report. *World J Gastroenterol* 2012;18:7100-3.
  29. Chavez C, Hoffman MA. Complete remission of ALK-negative plasma cell granuloma (inflammatory myofibroblastic tumor) of the lung induced by celecoxib: A case report and review of the literature. *Oncol Lett* 2013;5:1672-6.
  30. Watanabe H, Uruma T, Tazaki G, Tajiri T, Kikuchi R, Itoh M, *et al.* Remission of ALK-negative primary pulmonary inflammatory myofibroblastic tumor on treatment with clarithromycin: A case report and review of the literature. *Oncol Lett* 2016;11:1757-61.
  31. Alezra E, Delforge X, Buisson P, Gourmel A, Cordonnier C, Ricard J, *et al.* Complete resolution of inflammatory myofibroblastic tumor of the bladder after antibiotic therapy. *Arch Pediatr* 2016;23:612-5.