

Unusual Renal and Colonic Mass: Description of a Rare Case

Abstract

Seminoma is a germ cell tumor which accounts for approximately 40% of all germ cell tumors. Testicular seminoma is usually localized to the testis, and in 25% of cases, lymph node metastasis is seen. However, rarely, it can metastasize to viscera. We report a rare case of metastatic seminoma in a 40-year-old male who presented with renal and intestinal mass 2 years after orchidectomy.

Keywords: *Intestinal, metastasis, renal, seminoma, testis*

Introduction

Visceral metastases of seminoma at presentation can be seen in <5% of patients and in general occur late in the course of the disease. Seminoma can rarely metastasize to the kidney and metastasize to the gastrointestinal tract (GIT) is least likely with an incidence of <1%.^[1] We report a rare case of metastatic seminoma in a 40-year-old male who presented with renal and intestinal mass 2 years after orchidectomy for seminoma.

Case Report

A 40-year-old male was admitted with chief complaints of swelling in the left flank and abdominal discomfort for 2 years. The swelling was gradually increasing in size and was not associated with fever, hematuria, or constipation. The patient was a chronic smoker. Hematological and biochemical investigations were within normal limits. X-ray chest was normal. Ultrasonography abdomen suggested a left renal mass with tumor emboli in the left renal vein and inferior vena cava lumen. Computed tomography abdomen was done and showed left renal mass at the lower pole with complete encasement of ipsilateral ureter, renal artery, and vein. Tumor was extending medially up to the aorta with mild paravertebral extension at L2 into the para-aortic lymph nodes and infiltration of the psoas muscle and colon [Figure 1]. Fine needle aspiration cytology was done from outside which showed single

This is an open access journal, and articles are distributed under the terms of the Creative Commons Attribution-NonCommercial-ShareAlike 4.0 License, which allows others to remix, tweak, and build upon the work non-commercially, as long as appropriate credit is given and the new creations are licensed under the identical terms.

For reprints contact: reprints@medknow.com

and small groups of atypical cells with eccentric hyperchromatic nuclei and focally appreciable vacuolated cytoplasm against a hemorrhagic background. Cytological diagnosis was malignant tumor with a possibility of clear cell renal carcinoma.

The patient underwent nephrectomy, adherent segmental colectomy along with left ureteric and para-aortic lymph node excision.

Histopathological Examination

The kidney measured 8.5 cm × 5 cm × 3 cm with adherent 9.5 cm of the colon. External surface of the kidney appeared gray-white and encapsulated except for the area where the segment of the intestine was adherent. Serial slicing revealed a poorly circumscribed firm white nodular lesion toward the lateral surface. Pelvicalyceal system was dilated with a clot in the hilar area. Two para-aortic lymph nodes were also identified measuring 3 cm × 2 cm × 1 cm and 2 cm × 1 cm × 1 cm. The tumor was infiltrating into the adherent large intestine.

On microscopy, multiple sections from the renal mass showed prominent fibrohistiocytic proliferation [Figure 2a], confluent epithelioid cell granulomas, lymphocytic infiltrate, and giant cells. Intervening areas and the pelvis were infiltrated by single as well as nests of tumor cells. The cells were showed moderate nuclear pleomorphism, vesicular chromatin, prominent nucleoli, and scant-to-moderate amount of clear cytoplasm [Figure 2b]. Large areas of necrosis were also noted. The tumor

How to cite this article: Khare M, Ahuja A, Bhardwaj M, Khattar N. Unusual renal and colonic mass: Description of a rare case. *Indian J Med Paediatr Oncol* 2019;40:S154-6.

**Manika Khare,
Arvind Ahuja,
Minakshi Bhardwaj,
Nikhil Khattar¹**

*Departments of Pathology
and ¹Urology, Post Graduate
Institute of Medical Education
and Research, Dr RML
Hospital, New Delhi, India*

Address for correspondence:

*Dr. Arvind Ahuja,
Department of Pathology,
Post Graduate Institute
of Medical Education and
Research, Dr RML Hospital,
New Delhi - 110 001, India.
E-mail: drarvindahuja@gmail.
com*

Access this article online

Website: www.ijmpo.org

DOI: 10.4103/ijmpo.ijmpo_190_17

Quick Response Code:



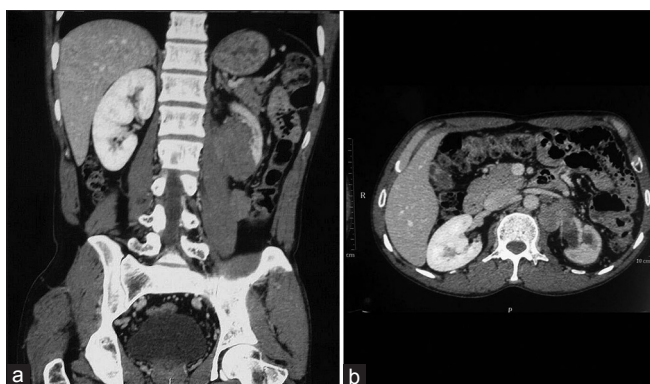


Figure 1: (a) Magnetic resonance imaging showing a large relatively well-defined irregular shape, heterogeneously enhancing mass lesion with delayed filling seen in the perinephric and renal capsular region at the lower pole of the left kidney. (b) Mass is causing complete encasement of renal artery and vein

was infiltrating the renal capsule. Ten para-aortic lymph nodes were identified, out of which five showed tumor deposits; however, the ureter was free of tumor. Multiple sections from the large intestine showed infiltration by the tumor [Figure 2c].

Considering the morphological features, differential diagnosis of clear cell renal carcinoma, lymphoma, and metastatic seminoma was kept, and immunohistochemical (IHC) panel was applied [Table 1]. Based on the histomorphology and IHC IHC [Figure 2a-d], a diagnosis of metastatic seminoma with florid granulomatous reaction in the kidney, colon, and para-aortic lymph nodes was made.

The patient was then interrogated for surgical history which revealed that he had undergone left orchidectomy with left-sided hernioplasty 2 years back at some other hospital. Histopathological examination report showed a diagnosis of seminoma of the left testis with exuberant granulomatous reaction. Spermatic cord also showed infiltration by the tumor. However, the patient did not receive any therapy after orchidectomy.

Discussion

Seminoma accounts for half of all germ cell tumors, whereas nonseminomatous germ cell tumors account for the remaining half. Metastatic spread of these tumors typically occurs via retroperitoneal lymphatics, and the most common sites include retroperitoneal lymph nodes, lungs, liver, brain, and bone. Extranodal metastasis of pure seminoma is very uncommon. Metastasis to GIT is even rarer. In a study by Chait *et al.*, which included postmortem data, metastases to the GIT were documented in 25 of 487 (5%) patients with testicular cancer.^[2] However, GIT metastasis by pure seminoma was not documented in this series. In a study by Husband and Bellamy, 20 out of 650 patients (3%) had unusual extranodal metastases in sites such as the kidney,

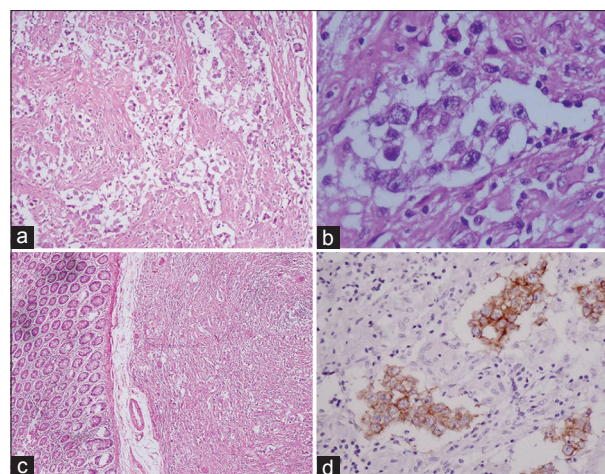


Figure 2: (a) Nests of tumor cells with intervening fibroblastic and histiocytic proliferation and infiltration by lymphocytes (H and E, ×100), (b) tumor cells showing moderate nuclear pleomorphism, vesicular chromatin, prominent nucleoli, and scant-to-moderate amount of cytoplasm with cytoplasmic clearance (H and E, ×400), (c) photomicrograph showing metastasis to the intestine (H and E, ×40), (d) CD117-positive tumor cells (IHC, ×400)

Table 1: List of Immunohistochemistry panel and results

IHC marker	Result
Pancytokeratin	Focal positive
EMA	Negative
Vimentin	Negative
CD10	Negative
CD117	Positive
S100	Negative
LCA	Negative
PLAP	Negative
CK 7	Negative

adrenal gland, spleen, and stomach at presentation.^[3] In a series by Sweetenham *et al.*, three cases of seminoma metastasizing to the duodenum and stomach were described.^[4] Only few cases of renal metastasis of seminoma have been reported. Castelán-Maldonado *et al.* reported a case of 24-year-old male with metastatic seminoma of the left kidney, 11 months after the orchidectomy done for seminoma.^[5] Similarly, our patient presented with metastasis to kidney and colon 2 years after orchidectomy.

However, placental alkaline phosphatase (PLAP) positivity is seen in 85%–98% cases. Studies have demonstrated that PLAP is neither a specific nor a sensitive marker for seminoma. The expression of PLAP may decrease in extragonadal or metastatic seminoma as compared to primary seminoma.

It is important to diagnose seminoma early because tumor stage is the most important prognostic factor. Seminomas are extremely sensitive to radiation and chemotherapy, and these modalities are usually incorporated in the treatment following orchidectomy. Cure rates exceeding 95% can

be expected for these patients. For metastatic seminoma, treatment by platinum-based combined chemotherapy is preferred.

Conclusions

This is a rare case of pure seminoma with metastasis to para-aortic lymph node, kidney, and colon 2 years after orchidectomy. There was striking granulomatous reaction, and PLAP stain was negative. To conclude, proper clinical history along with the histomorphological and IHC correlation can aid in the definitive diagnosis of metastatic seminoma, and negative PLAP staining does not exclude it.

Declaration of patient consent

The authors certify that they have obtained all appropriate patient consent forms. In the form the patient(s) has/have given his/her/their consent for his/her/their images and other clinical information to be reported in the journal. The patients understand that their names and initials will not be published and due efforts will be made to conceal their identity, but anonymity cannot be guaranteed.

Financial support and sponsorship

Nil.

Conflicts of interest

There are no conflicts of interest.

References

1. Senadhi V, Dutta S. Testicular seminoma metastasis to the gastrointestinal tract and the necessity of surgery. *J Gastrointest Cancer* 2012;43:499-501.
2. Chait MM, Kurtz RC, Hajdu SI. Gastrointestinal tract metastasis in patients with germ-cell tumor of the testis. *Am J Dig Dis* 1978;23:925-8.
3. Husband JE, Bellamy EA. Unusual thoracoabdominal sites of metastases in testicular tumors. *AJR Am J Roentgenol* 1985;145:1165-71.
4. Sweetenham JW, Whitehouse JM, Williams CJ, Mead GM. Involvement of the gastrointestinal tract by metastases from germ cell tumors of the testis. *Cancer* 1988;61:2566-70.
5. Castelán-Maldonado EE, Peña-Ruelas CI, Ignacio-Morales CV, Romero-Martínez SA, Sánchez-Arbea PC. Classic renal metastatic seminoma. *Cir Cir* 2013;81:142-5.