Article published online: 2021-06-03

Original Article

Comparison of Efficacy of Positron Emission Tomography/Computed Tomography with Contrast-Enhanced Computed Tomography in Pretreatment Evaluation of Head and Neck Cancers: An Institutional Experience

Mayuri Jain, Arti Sarin, V Suhag, GPS Gahlot[1], Anurag Jain[2], A Bandhopadhya[3]

Departments of Radiation Oncology, [1]Pathology, [2]Nuclear Medicine and [3]Surgical Oncology, Army Hospital RnR, New Delhi, India

Abstract

Introduction: Head and neck squamous cell carcinomas (SCCs) constitute 5.4% of all cancers worldwide, and 23% of all cancers in males and 6% of all cancers in females diagnosed in India. Lots of ambiguity exists in primary, nodal, and metastatic workup of these patients, especially in developing countries. **Aim:** The study was designed to compare the accuracy of whole-body positron emission tomography/computed tomography (WBPET/CT) scan with contrast-enhanced CT (CECT) face and neck as pretreatment evaluation for staging workup and management decision and to confirm the nodal findings on imaging with fine-needle aspiration cytology (FNAC). **Design:** It was a single-institute, prospective, observational, interventional study over a 2-year period. All cases of SCC of upper aerodigestive tract who were scheduled for definitive treatment concurrent chemoradiotherapy or radiotherapy were evaluated with routine investigations followed by imaging in the form of CECT face and neck and 18F-fluorodeoxyglucose (FDG) WBPET/CT. **Results:** In the 40 enrolled patients, all underwent CECT face and neck and WBPET/CT. During initial workup, biopsy was taken from primary site and FNAC was done from neck nodes for diagnosis and for staging. In 40 patients, CECT neck showed nodal metastasis in 39 patients; however, FNAC came positive in 38 cases. PET/CT showed nodal metastasis in 38 patients; however, FNAC came positive in 38 cases. Any node with Standardized uptake value (SUV) >2.5 was taken as suspicious lesion and FNAC was done. Sensitivity of CECT and PET/CT was 97.36% and 100%, respectively, while the specificity was 0% and 100%, respectively. Positive predictive value calculated for CECT and WBPET was 94.87% and 100%, respectively, while the negative predictive value for CECT and WBPET was 0% and 100%, respectively. **Conclusion:** In head and neck SCC, FDG-PET/CT is more accurate than CECT in staging of the neck.

Keywords: *Computed tomography scan, fine-needle aspiration cytology, Head and Neck Cancers, positron emission tomography scan*

Introduction

Extracranial head and neck carcinomas constitute 5.4% of all cancers worldwide,[1] and 23% of all cancers in males and 6% of all cancers in females diagnosed in India.[2] Most head and neck cancers are squamous cell carcinomas (SCCs) of the oral cavity, oropharynx, larynx, or nasopharynx. The head and neck region is a region of considerable anatomical and functional complexity, making the accurate staging of head and neck neoplasm a challenging task. Imaging constitutes a vital component of the primary and metastatic workup of these lesions. The current radiological modalities provide a reliable visualization of head and neck structure to an unprecedented level of detail. Imaging techniques such as multidetector computed tomography (CT), magnetic resonance imaging (MRI), positron emission tomography (PET)-CT are now available and allow detailed morphological display of the extent of disease in head and neck region.

PET has been utilized since the 1970s for clinical imaging. PET scanning with 18-fluorodeoxyglucose (18-FDG) can be used for staging and evaluation of recurrence for primary head and neck tumors. The principle for PET is based on the metabolism of the neoplasm, primary or recurrent, and is more sensitive than CT or

This is an open access journal, and articles are distributed under the terms of the Creative Commons Attribution-NonCommercial-ShareAlike 4.0 License, which allows others to remix, tweak, and build upon the work non-commercially, as long as appropriate credit is given and the new creations are licensed under the identical terms.

For reprints contact: reprints@medknow.com

How to cite this article: Jain M, Sarin A, Suhag V, Gahlot GP, Jain A, Bandhopadhya A. Comparison of efficacy of positron emission tomography/computed tomography with contrast-enhanced computed tomography in pretreatment evaluation of head and neck cancers: An institutional experience. Indian J Med Paediatr Oncol 2019;40:217-21.

Address for correspondence:
Dr. Mayuri Jain, Department of Radiation Oncology, Army Hospital (R and R), Delhi Cantonment, New Delhi - 110 010, India.
E-mail: mayurisonu@gmail.com

Access this article online

Website: www.ijmpo.org

DOI: 10.4103/ijmpo.ijmpo_226_17

Quick Response Code:

MRI for T1-staged lesions.[3] The most recent innovation in PET systems is the hybrid PET/CT scanners. Integration of PET with CT scan in 2000 was a great leap forward and enhanced the clinical information from PET.

The purpose of this study was to evaluate the PET-CT and CT scan of the head and neck region in the primary staging of patients with cancers of the head and neck region and to establish a protocol comprising the choice of the initial diagnostic modality to be used in the imaging of head and neck cancer at our tertiary care government center.

Materials and Methods

It was a prospective, observational study conducted in the radiotherapy department of a tertiary care multispecialty government hospital. The study included 40 consecutive patients with carcinoma of the head and neck region presenting in the department of ENT and oncology center. All the patients were subjected to a detailed clinical examination and endoscopic evaluation of the extent of the disease. Fine-needle aspiration or biopsy of the lesion and lymph node was accepted for histopathological confirmation. All the patients were evaluated with CT and PET/CT scan, and the findings were correlated with clinical findings. The patients were treated with concurrent chemoradiotherapy or radiotherapy as per the standard of care. This study was completed over a period of 22 months from April 1, 2014, to February 28, 2016.

The inclusion criteria were clinical suspicion of malignancy in the oral cavity, oropharyngeal, or laryngopharyngeal region; histopathological confirmation by biopsy; Karnofsky Performance Score (KPS) ≥70% at time of screening; life expectancy of >6 months; no major comorbid medical conditions; and hemogram and biochemical parameters within normal limits.

The major exclusion criteria were patients under 18 years of age, pregnant or lactating females, failure to obtain informed consent, patients with dual malignancy, patients already treated cases of head and neck malignancy, patients with KPS <60%, and patients with major medical comorbidities.

The study was conducted in the department of radiation oncology in collaboration with the department of nuclear medicine and department of radiodiagnosis. After detailed history and general physical examination, the patients underwent baseline CT and PET scan. All CT and PET scan images were analyzed a by a radiologist and a nuclear medicine physician. Any area of focal greater than background muscle uptake was considered pathological (malignant lesion) and correlated with signs, symptoms, and clinical examination findings. Positive PET scan and CT scan findings were correlated with clinical findings and histopathological findings. Any discordant findings were investigated by subjecting the positive lesion to biopsy and histopathological examination after clinical examination. In case of positive findings, histopathology of the same lesion was taken as gold standard in describing it malignant or nonmalignant.

The patients were treated with concurrent chemotherapy with radiotherapy. The radiation therapy was delivered at this institute. Patients treated with a total dose of 70 Gy/35# (2 Gy/5 #/week), with weekly concurrent chemo-injection cisplatin. The study was carried out after taking written consent from all patients and clearance from ethical committee.

Results

The analysis of data was done using SPSS software version 15.0 (Chicago, IL). Chi-square test and Fisher's exact test were applied to find the association between two qualitative variables. The inferences were drawn at 5% level of significance, and hence, $P < 0.05$ was considered statistically significant. Sensitivity, specificity, positive predictive value, negative predictive value (NPV), and diagnostic accuracy with its statistical significance were also calculated to see the agreement with histopathology (biopsy/fine-needle aspiration cytology [FNAC]).

In our study, male to female ratio is 9:1. The most common decade of presentation was 50–60 years. The youngest patient was 28 years old while the Eldest was 74 years old; mean age was 57, while the age distribution is as shown in Table 1. Smokers: nonsmoker ratio was 9:1. Most common histology was SCC seen in 39 out of 40 cases. The Commonest site was oropharynx as seen in 45% of cases [Table 2] and the most common subsite was base of tongue [Table 3]. The most common stage of presentation was Stage IV as seen in 62.5% of cases.

CECT scan of the face and neck and whole-body PET-CT scan were done in all patients before treatment. There was no difference in detecting primary site of tumor, and T-staging in both CECT and PET/CT groups detected the same result [Table 4 and Figure 1]. In detecting N-stage of tumor in the study cases, diagnostic accuracy of CECT was 92.5% and of PET-CT was 100% [Table 5 and Figure 2].

During initial workup, biopsy was taken from primary site and FNAC was done from neck nodes for diagnosis and for staging. The results of CECT and PET-CT for detecting nodal status before treatment are tabulated in Tables 6 and 7, respectively. In 40 patients, CECT neck showed nodal metastasis in 39 patients; however, FNAC came positive in 38 cases. Sensitivity of CECT for detecting nodal status was 97.37%, specificity was 0%, predictive value of positive test was 94.87%, predictive value of negative test was 0, and diagnostic accuracy was 92.5%; *P* value (Fisher's exact test) being 1.000. In 40 patients, PET-CT neck showed nodal metastasis in 38 patients, and the FNAC came positive in all 38 cases. Sensitivity of PET/CT for detecting nodal status was 100%, specificity was 100%, predictive value of

Table 1: Age distribution of cases

Age interval	Frequency (%)
≤30	1 (2.5)
30-40	1 (2.5)
40-50	6 (15)
50-60	20 (50)
60-70	10 (25)
>70	2 (5)
Total	40 (100)
Mean	57.4
SD	9.057650117

SD – Standard deviation

Table 2: Site of primary tumor in patients

Disease	Frequency (%)
Nasopharynx	1 (2.5)
Larynx	7 (17.5)
Oropharynx	18 (45)
Hypopharynx	11 (27.5)
Oral cavity	3 (7.5)
Total	40 (100)

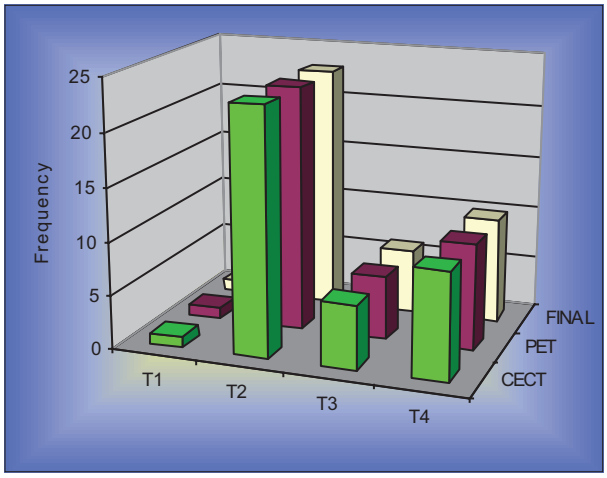

Figure 1: Pretreatment comparison in contrast-enhanced computed tomography and positron emission tomography/computed tomography in detecting T-stage

positive test was 100%, predictive value of negative test was 100%, and diagnostic accuracy is 100%; *P* value (Fisher's exact test) being 0.001 [Table 7].

Discussion

Cancer of the oral cavity comprises approximately 30% of head and neck region tumors and 3% of all cancers in the United States. Head and neck cancers are common in India and account for about 30% of cancers in males and about 13% in females. In males, oral cavity and pharynx are the commonly affected sites, followed by larynx. In females, oral cavity is the preponderant site.[4] Despite advances in the treatment of head and neck cancer, 15%–50% of the patients will develop recurrent disease.[5]

Table 3: Subsite of tumor in patients

Tumor Site	Subsite	Number of cases (*n*=40)
Nasopharynx		1
Larynx	Epiglottis	4
	Aryepiglottic folds	3
	Arytenoids	0
	False cord	0
	Ventricle	0
	Glottis	0
	Subglottis	0
Oropharynx	Base of tongue	12
	Tonsil	6
	Soft palate	0
	Uvula	0
	Pharyngeal wall	0
Hypopharynx	Pyriform sinus	10
	Postcricod region	1
	Posterior pharyngeal wall	0
Oral cavity	Lip	0
	Buccal mucosa	0
	Lower alveolus	0
	Retromolar trigone	1
	Anterior 2/3rd of tongue	2
	Floor of mouth	0
	Alveolar ridge	0
	Hard palate	0

Table 4: Pretreatment comparison of T-stage by contrast-enhanced computed tomography and positron emission tomography-computed tomography (no discrepancy noted)

T-stage	Frequency (%)		
	CECT	PET	Final
T1	1 (2.5)	1 (2.5)	1 (2.5)
T2	23 (57.5)	23 (57.5)	23 (57.5)
T3	6 (15)	6 (15)	6 (15)
T4	10 (25)	10 (25)	10 (25)
Total	40 (100)	40 (100)	40 (100)

CECT – Contrast-enhanced computed tomography; PET – Positron emission tomography

For initial workup routine investigations, chest X-ray, CECT, or MRI face and neck are recommended. PET scan is recommended only in advanced cases (Stage III and IV).

In our study, initial CECT and PET/CT both detected primary tumor in all patients (sensitivity 100%). This does not match with sensitivities and specificities quoted in the literature,[6-8] which quotes better sensitivity of PET/CT than CT alone. Lower sensitivity of CECT is related to the fact that early of submucosal lesion may be difficult to detect and differentiate from adjacent soft tissue on anatomical imaging. However, in our study, all cases were Stage III and beyond only one Stage II case. According to tumor/node/metastasis staging, T1 – 2.5%, T2 – 57.5%,

Table 5: Diagnostic accuracy of contrast-enhanced computed tomography in detecting N-stage of tumor (92.5% for contrast-enhanced computed tomography and 100% for positron emission tomography-computed tomography)

N-stage	Frequency (%)		
	CECT	PET	Final (HPR)
N0	1 (2.5)	2 (5)	2 (5)
N1	16 (40)	16 (40)	16 (40)
N2	20 (50)	19 (47.5)	19 (47.5)
N3	3 (7.5)	3 (7.5)	3 (7.5)
Total	40 (100)	40 (100)	40 (100)

CECT – Contrast-enhanced computed tomography; PET – Positron emission tomography; HPR – Histopathological response

Table 6: Result of contrast-enhanced computed tomography for detecting nodal status before treatment

CECT	HPR		Total
	Positive	Negative	
Positive	37	2	39
Negative	1	0	1
Total	38	2	40
Sensitivity		97.36842105	
Specificity		0	
Predictive value of positive test		94.87179487	
Predictive value of negative test		0	
Percentage of false negative		2.631578947	
Percentage of false positive		100	
Diagnostic accuracy		92.5	

P (Fisher's exact test) =1.000. CECT – Contrast-enhanced computed tomography; HPR – Histopathological response

Table 7: Result of positron emission tomography-computed tomography scan for detecting nodal status before treatment

PET	HPR		Total
	Positive	Negative	
Positive	38	0	38
Negative	0	2	2
Total	38	2	40
Sensitivity		100	
Specificity		100	
Predictive value of positive test		100	
Predictive value of negative test		100	
Percentage of false negative		0	
Percentage of false positive		0	
Diagnostic accuracy		100	

P (Fisher's exact test) =0.001. In 40 patients, PET CT showed nodal metastasis in 38 patients; however, FNAC came positive in 38 cases. HPR – Histopathological response; PET – Positron emission tomography; FNAC – Fine needle aspiration cytology; PET-CT – Positron emission tomography-computed tomography

T3 – 15%, and T4 – 25%. Same sensitivity of PET/CT and CECT in our study could be attributed to late presentation.

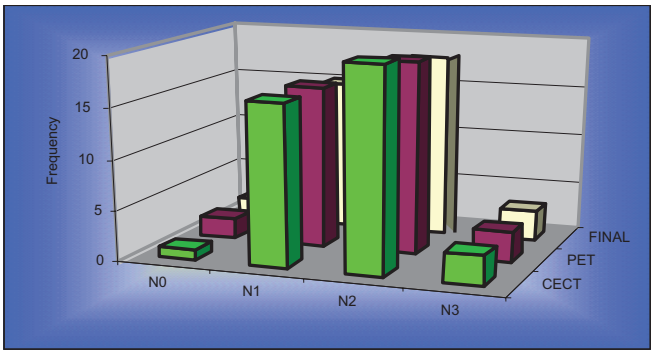

Figure 2: Pretreatment comparison in contrast-enhanced computed tomography and positron emission tomography/computed tomography in detecting N-stage according to tumor/node/metastasis staging

According to the study done by Hannah *et al*.,[9] sensitivity and specificity for the presence of metastatic neck disease on FDG-PET were 82% and 100%, respectively; those for CT were 81% and 81%, respectively, in our study. The sensitivity and specificity for the presence of metastatic neck disease on FDG-PET were 100% and 100%, those for CT 97.36% sensitive, accuracy of CECT was 92.5%. FDG-PET was true positive for metastatic neck disease in two of the three CT false-negative patients.

According to a study done by Schmid *et al*., for evaluating metastatic disease in the cervical lymph nodes, PET-CT was superior to conventional imaging. An average sensitivity of 87%–90% and a specificity of 80%–93% were reported for PET/CT, compared with a sensitivity of 61%–97% for CECT/MRI.[10]

The accuracy of 18F-FDG-PET, CT/MRI, and their visual correlation for the identification of primary tumors was 98.4%, 87.1%, and 99.2%, respectively. The sensitivity of 18F-FDG-PET for the identification of nodal metastases on a level-by-level basis was 22.1% higher than that of CT/MRI (74.7% vs. 52.6%, $P < 0.001$), whereas the specificity of 18F-FDG-PET was 1.5% lower than that of CT/MRI (93.0% vs. 94.5%, $P = 0.345$). The sensitivity and specificity of the visual correlation of 18F-FDG-PET and CT/MRI were 3.2% and 1.5% higher than those of 18F-FDG-PET alone (77.9% vs. 74.7%, $P = 0.25$; 94.5% vs. 93.0%, $P = 0.18$; respectively). The area under the curve obtained from the receiver operating characteristic curve showed that 18F-FDG-PET was significantly superior to CT/MRI for total nodal detection (0.896 vs. 0.801, $P = 0.002$), whereas the visual correlation of 18F-FDG-PET and CT/MRI was modestly superior to 18F-FDG-PET alone (0.913 vs. 0.896, $P = 0.28$).[11]

Conclusion

The purpose of this study was to evaluate the PET/CT scan and CT scan of the head and neck region in the primary staging and posttreatment assessment of patients with cancers of the head and neck region. We infer that FDG-PET/CT yields significantly better results compared to CECT, in detecting nodal metastasis in primary staging and in detecting

residual or recurrent disease in patients with head and neck cancer. Its high NPV can help in avoiding unnecessary invasive procedure/surgery. For locoregional mapping of disease, PET/CT and CECT are comparable in their sensitivity for detecting the primary lesion; however, PET/CT is more sensitive and specific than CECT in detecting nodal metastasis in patients with head and neck. In summary, in this prospective study, FDG-PET/CT was not found superior to CECT for initial T-staging of head and neck malignancies, but for initial N-staging, FDG-PET/CT was superior to CECT.

Drawbacks of the study

Small sample size – Our study has 40 patients only. It is a small group. They all were Stage III, and beyond, only one patient was diagnosed as Stage II. Although this study was done in a government setup where the patients did not have to pay for PET/CT, in private sector, cost of one PET scan is approximately INR 20,000 and cost of one CECT is INR 3000–5000, which can escalate the cost of management and burn a hole in patient's pocket. Moreover, there was room for observer variation. Being a government hospital, every time reports were given by different radiologists and nuclear medicine specialists and they were reviewed by different head and neck oncologist. Larger prospective studies are warranted to stabiles the definitive role in the management protocols and cost-effectiveness of FDG-PET/CT in the management of head and neck cancers.

Acknowledgments

We would like to thank all allied specialties of oncology and the radiology and nuclear medicine department for their support in managing these cases and in carrying out the study.

Financial support and sponsorship

Nil.

Conflicts of interest

There are no conflicts of interest.

References

1. Ries LA, Melbert D, Krapcho M, Stinchcomb DG, editors. SEER Cancer Statistics Review 1975-2005. Bethesda MD.
2. National Cancer Registry Programme. Biennial Report (1988-1989) of the National Cancer Registry Programme. New Delhi: Indian Council of Medical Research, Surya Printers; 1992. p. 3-42.
3. Robert Hermans, Head and Neck Imaging Technique. P31-42,49-56.
4. Seminar in surgical Oncology. National cancer Institute, TMH 1989;5305-309.
5. Bourhis J, Le Maître A, Baujat B, Audry H, Pignon JP; Meta-Analysis of Chemotherapy in Head, Neck Cancer Collaborative Group, *et al.* Individual patients' data meta-analyses in head and neck cancer. Curr Opin Oncol 2007;19:188-94.
6. Gordin A, Daitzchman M, Doweck I, Yefremov N, Golz A, Keidar Z, *et al.* Fluorodeoxyglucose-positron emission tomography/computed tomography imaging in patients with carcinoma of the larynx: Diagnostic accuracy and impact on clinical management. Laryngoscope 2006;116:273-8.
7. Scarfone C, Lavely WC, Cmelak AJ, Delbeke D, Martin WH, Billheimer D, *et al.* Prospective feasibility trial of radiotherapy target definition for head and neck cancer using 3-dimensional PET and CT imaging. J Nucl Med 2004;45:543-52.
8. Sullivan BP, Parks KA, Dean NR, Rosenthal EL, Carroll WR, Magnuson JS, *et al.* Utility of CT surveillance for primary site recurrence of squamous cell carcinoma of the head and neck. Head Neck 2011;33:1547-50.
9. Hannah A, Scott AM, Tochon-Danguy H, Chan JG, Akhurst T, Berlangieri S, *et al.* Evaluation of 18 F-fluorodeoxyglucose positron emission tomography and computed tomography with histopathologic correlation in the initial staging of head and neck cancer. Ann Surg 2002;236:208-17.
10. Schmid DT, Stoeckli SJ, Bandhauer F, Huguenin P, Schmid S, von Schulthess GK, Goerres GW, *et al*. Impact of positron emission tomography on the initial staging and therapy in locoregional advanced squamous cell carcinoma of the head and neck. Laryngoscope. 2003;113:888-9150.
11. Ng SH, Yen TC, Liao CT, Chang JT, Chan SC, Ko SF, *et al.* 18F-FDG PET and CT/MRI in oral cavity squamous cell carcinoma: A prospective study of 124 patients with histologic correlation. J Nucl Med 2005;46:1136-43.