

## Solid Pseudopapillary Tumor of Pancreas: A Case Report and Review of Literature

### Abstract

Solid pseudopapillary neoplasm of the pancreas is one of the rarest forms of pancreatic neoplasm. It was also known as Franz's tumor or Hamoudi tumor until WHO labeled it as solid pseudopapillary tumor (SPT) in 1996. It typically affects young non-Caucasian females in their second or third decade of life. Treatment involves complete excision of the tumor which results in complete cure in majority of the cases. We present here a report of 11-year-old girl with SPT and also do a review of literature for this rare tumor.

**Keywords:** Children, Franz's tumour, solid pseudopapillary tumor

### Gursev Sandlas, Charu Tiwari<sup>1</sup>

Department of Paediatric Surgery, Kokilaben Dhirubhai Ambani Hospital, <sup>1</sup>Department of Paediatric Surgery, TNMC and BYL Nair Hospital, Mumbai, Maharashtra, India

### Introduction

Solid pseudopapillary neoplasm of the pancreas is one of the rarest forms of pancreatic neoplasm. It was also known as Franz's tumor or Hammoudi tumor until WHO labeled it as solid pseudopapillary tumor (SPT) in 1996. It typically affects young non-Caucasian females in their second or third decade of life. Treatment involves complete excision of the tumor which results in complete cure in the majority of the cases. Here, we present a report of 11-year-old girl with SPT and also do a review of literature for this rare tumor.

### Case Report

An 11-year-old, otherwise healthy girl presented with acute onset abdominal pain and associated vomiting for 1 day. On further direct questioning, the patient gave history of recurrent episodes of abdominal pain over the past 6 months. On examination, the general examination was unremarkable. The abdomen was soft. There was mild tenderness noted on deep palpation in the left hypochondrium and the left lumbar region. Hematological investigations were unremarkable. Both serum amylase and serum lipase were normal.

An ultrasound of the abdomen revealed a large mass in the lesser sac. A computed tomography scan of the abdomen showed

a large heterogeneous mass, partly solid, and partly cystic in nature occupying the entire lesser sac abutting the pancreas and the spleen [Figure 1]. The left kidney and the stomach were in proximity but not affected. The mass showed a well-defined margin, but the organ of origin could not be conclusively determined.

In view of the eminent resectability of the tumor, decision was taken to excise the mass.

On exploratory laparotomy, a large mass was found in the lesser sac densely adherent to the pancreas and the spleen with splenic artery thrombosis. Excision of the mass [Figure 2] along with distal pancreatectomy and splenectomy was done. The postoperative course was uneventful, and the patient is doing well on follow-up.

### Discussion

Solid pseudopapillary neoplasm of the pancreas is a rare tumor characterized by its occurrence in young women and its limited malignant potential.<sup>[1,2]</sup>

Our patient presented at 11 years of age which is significantly lower age of presentation as reported by other series from around the world.<sup>[3-6]</sup>

Although some authors had reported solid pseudopapillary neoplasm (SPN) as early as 1927, its recognition as a distinctive entity came in 1959 by Frantz.<sup>[7]</sup> Since then, more than 750 cases have been

This is an open access article distributed under the terms of the Creative Commons Attribution-NonCommercial-ShareAlike 3.0 License, which allows others to remix, tweak, and build upon the work non-commercially, as long as the author is credited and the new creations are licensed under the identical terms.

For reprints contact: reprints@medknow.com

**How to cite this article:** Sandlas G, Tiwari C. Solid pseudopapillary tumor of pancreas: A case report and review of literature. Indian J Med Paediatr Oncol 2017;38:207-9.

### Address for correspondence:

Dr. Gursev Sandlas,  
Kokilaben Dhirubhai Ambani  
Hospital, Mumbai,  
Maharashtra, India.  
E-mail: drgursev@gmail.com

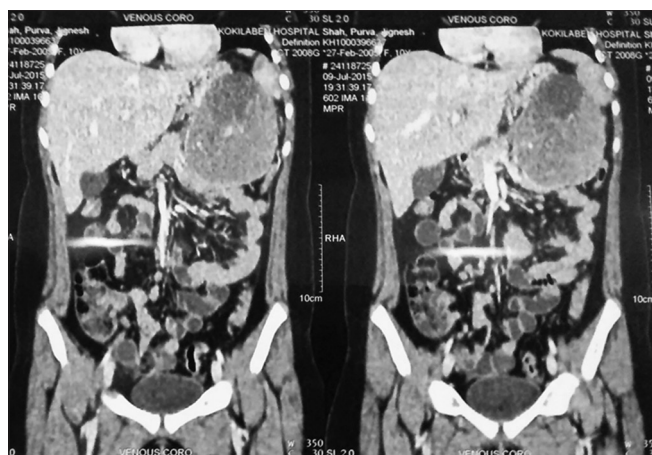
### Access this article online

Website: www.ijmpo.org

DOI: 10.4103/ijmpo.ijmpo\_59\_16

### Quick Response Code:





**Figure 1: Computed tomography scan of the abdomen showing a large heterogeneous mass, partly solid, and partly cystic in nature occupying the entire lesser sac abutting the pancreas and the spleen**

reported in the English literature,<sup>[8,9]</sup> predominantly within the last 20 years,<sup>[8,10]</sup> reflecting the increased awareness of this uncommon neoplasm. The reported frequency is variable and ranges from as low as 0.17% to as high as 6% of exocrine pancreatic tumors.<sup>[1,4,7]</sup> Interestingly, 90% of patients are young women with a mean age of 22 years in one report<sup>[4]</sup> and 28 years in another.<sup>[1]</sup> The age of patients ranges widely, from 2 to 85 years.<sup>[4]</sup> In a study of 17 pancreatic tumors in patients younger than 21 years – and representing the Memorial Sloan-Kettering Cancer Center (New York, New York) experience spanning more than 30 years – SPN represented slightly less than half of the cases and predominated in the second decade of life, whereas pancreatoblastoma predominated in the first decade.<sup>[8]</sup>

The predominant female preponderance has been hypothesized to be due to the close proximity of the primordial pancreatic cells to the ovarian ridge in the embryonic phase.<sup>[11]</sup>

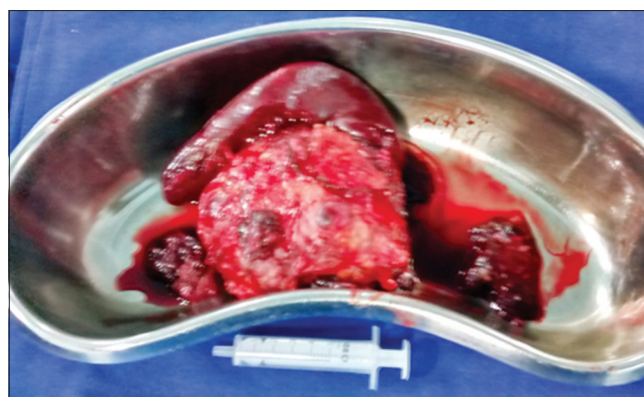
Common differential diagnosis of SPT includes microcystic adenoma, nonfunctioning islet cell tumor, mucinous cystic neoplasm, pancreatoblastoma, and calcified hemorrhagic pseudocyst.<sup>[12,13]</sup>

The role of tumor markers in diagnosis and prognosis of SPN has been explored by many and common tumor markers observed are adenosyl phosphoryl transferase/beta-catenin, cyclin D1 and D3, vimentin, antitrypsin, neuron-specific enolase (NSE), and progesterone.<sup>[7,11,14-17]</sup>

Of these the most consistent markers associated with SPT are vimentin, alpha-antitrypsin, NSE, and progesterone.<sup>[11]</sup>

Universally, surgical excision has been accepted as the only definitive treatment for SPT.<sup>[6,9,12]</sup>

The role of adjuvant therapy in the treatment of SPT is unclear, and both chemotherapeutic and radiotherapeutic options have been explored. However, the high rate of



**Figure 2: The excised specimen**

resectability of the tumor coupled with limited malignant potential precludes the need for adjuvant therapy.<sup>[10,18,19]</sup>

## Conclusion

SPT of the pancreas is a rare tumor found in young females. Although malignant, the malignant potential is low and aggressive surgical resection ensures a cure in a majority of patients.

## Financial support and sponsorship

Nil.

## Conflicts of interest

There are no conflicts of interest.

## References

1. Klimstra DS, Wenig BM, Heffess CS. Solid-pseudopapillary tumor of the pancreas: A typically cystic carcinoma of low malignant potential. *Semin Diagn Pathol* 2000;17:66-80.
2. Yu PF, Hu ZH, Wang XB, Guo JM, Cheng XD, Zhang YL, et al. Solid pseudopapillary tumor of the pancreas: A review of 553 cases in Chinese literature. *World J Gastroenterol* 2010;16:1209-14.
3. Lam KY, Lo CY, Fan ST. Pancreatic solid-cystic-papillary tumor: Clinicopathologic features in eight patients from Hong Kong and review of the literature. *World J Surg* 1999;23:1045-50.
4. Nishihara K, Nagoshi M, Tsuneyoshi M, Yamaguchi K, Hayashi I. Papillary cystic tumors of the pancreas. Assessment of their malignant potential. *Cancer* 1993;71:82-92.
5. Yagci A, Yakan S, Coskun A, Erkan N, Yildirim M, Yalcin E, et al. Diagnosis and treatment of solid pseudopapillary tumor of the pancreas: Experience of one single institution from Turkey. *World J Surg Oncol* 2013;11:308.
6. Speer AL, Barthel ER, Patel MM, Grikscheit TC. Solid pseudopapillary tumor of the pancreas: A single-institution 20-year series of pediatric patients. *J Pediatr Surg* 2012;47:1217-22.
7. Frantz VK. Atlas of Tumor Pathology, Section 7, Fascicles 27 and 28. Washington, DC, USA: Armed Forces Institute of Pathology; 1959. Papillary tumors of the pancreas: Benign or malignant? Tumors of the pancreas; p. 32-3.
8. Hruban RH, Pitman MB, Klimstra DS. Solid-pseudopapillary neoplasms. In: Silverberg SG, Sobin LH, editors. *Tumors of the*

- Pancreas, AFIP Atlas of Tumor Pathology. 4<sup>th</sup> Series, Fascicle 6. Washington, DC: ARP Press; 2007. p. 231-50.
9. Papavramidis T, Papavramidis S. Solid pseudopapillary tumors of the pancreas: Review of 718 patients reported in English literature. *J Am Coll Surg* 2005;200:965-72.
  10. Matsunou H, Konishi F. Papillary-cystic neoplasm of the pancreas. A clinicopathologic study concerning the tumor aging and malignancy of nine cases. *Cancer* 1990;65:283-91.
  11. Kosmahl M, Seada LS, Jänig U, Harms D, Klöppel G. Solid-pseudopapillary tumor of the pancreas: Its origin revisited. *Virchows Arch* 2000;436:473-80.
  12. Reddy S, Cameron JL, Scudiere J, Hruban RH, Fishman EK, Ahuja N, *et al.* Surgical management of solid-pseudopapillary neoplasms of the pancreas (Franz or Hamoudi tumors): A large single-institutional series. *J Am Coll Surg* 2009;208:950-7.
  13. Dong DJ, Zhang SZ. Solid-pseudopapillary tumor of the pancreas: CT and MRI features of 3 cases. *Hepatobiliary Pancreat Dis Int* 2006;5:300-4.
  14. Zhang H, Liang TB, Wang WL, Shen Y, Ren GP, Zheng SS. Diagnosis and treatment of solid-pseudopapillary tumor of the pancreas. *Hepatobiliary Pancreat Dis Int* 2006;5:454-8.
  15. Miao J, Kusafuka T, Kuroda S, Yoneda A, Zhou Z, Okada A. Mutation of beta-catenin and its protein accumulation in solid and cystic tumor of the pancreas associated with metastasis. *Int J Mol Med* 2003;11:461-4.
  16. Abraham SC, Klimstra DS, Wilentz RE, Yeo CJ, Conlon K, Brennan M, *et al.* Solid-pseudopapillary tumors of the pancreas are genetically distinct from pancreatic ductal adenocarcinomas and almost always harbor beta-catenin mutations. *Am J Pathol* 2002;160:1361-9.
  17. Tanaka Y, Kato K, Notohara K, Hojo H, Ijiri R, Miyake T, *et al.* Frequent beta-catenin mutation and cytoplasmic/nuclear accumulation in pancreatic solid-pseudopapillary neoplasm. *Cancer Res* 2001;61:8401-4.
  18. Maffuz A, Bustamante Fde T, Silva JA, Torres-Vargas S. Preoperative gemcitabine for unresectable, solid pseudopapillary tumour of the pancreas. *Lancet Oncol* 2005;6:185-6.
  19. Fried P, Cooper J, Balthazar E, Fazzini E, Newall J. A role for radiotherapy in the treatment of solid and papillary neoplasms of the pancreas. *Cancer* 1985;56:2783-5.