

Docetaxel-Induced Lung Injury: An Under-Recognized Complication of a Commonly Used Chemotherapeutic Agent

Abstract

Background: Docetaxel-induced pneumonitis is a rare, but potentially serious complication of a commonly used chemotherapeutic agent. **Methods:** We performed an audit of patients with suspected docetaxel pneumonitis from the tertiary cancer center. **Results:** Out of 477 patients who received docetaxel over a 1 year period, eight patients (1.7%) developed lung injury. All patients (median age: 43 years [34–65]) had breast cancer (four metastatic on palliative docetaxel, two were on neoadjuvant, and two were on adjuvant therapy) and had received a median of three cycles of docetaxel 75 mg/m² in a 3 weekly schedule (7 as single agent and 1 in combination with cyclophosphamide). One patient had the preexisting pulmonary disease (localized bronchiectasis), and four had received prior radiation to the chest wall or dorsal spine. The median time from administration of the last dose was 16 days (8–28). Most ($n = 6/8$, 75%) required hospitalization. Three patients with CTCAE Grade 3 pneumonitis required oxygen support. Radiology showed a pattern of interstitial pneumonitis in most patients. All the patients responded to steroids and follow-up imaging showed resolution of infiltrates. The median duration of hospital stay was 8.5 days (7–18 days). There was no mortality due to this condition. **Conclusions:** Drug-induced lung injury should be considered in patients presenting with respiratory symptoms after administration of docetaxel. Timely initiation of steroids could reduce complications.

Keywords: Breast cancer, docetaxel, pneumonitis, steroids

Avaronnan
Manuprasad,
Prasanth Ganesan,
Vandana Mahajan,
Trivadi S Ganesan,
Venkatraman
Radhakrishnan,
Manikandan
Dhanushkodi,
Tenali Gnana Sagar

Department of Medical
Oncology, Cancer
Institute (WIA), Chennai,
Tamil Nadu, India

Introduction

Docetaxel is a chemotherapeutic agent widely used in medical oncology practice. Pulmonary toxicity in the form of interstitial pneumonitis has been associated with docetaxel and reported when used for lung, breast, and prostate cancer.^[1,2] Although rare, the identification of this complication is important as it has been associated with up to 40% mortality in certain series.^[3] We present a descriptive audit of patients with suspected docetaxel associated lung injury from a single institute.

Methods

We reviewed the records 477 patients who received docetaxel over a 1 year period (June 2015 and 2016). Among these, patients who presented with respiratory symptoms within 4 weeks of administration of docetaxel were identified. After excluding patients with overt signs of infection (fever, productive cough, and

preexisting upper respiratory symptoms) and those who had overt metastatic disease involving the lungs, we identified eight patients (all 8 had breast cancer) with possible drug-induced lung injury. The records of these were assessed for disease characteristics, details of chemotherapy, clinical presentation, laboratory and radiological features, treatment details, and outcomes.

Results

The indications for the use of docetaxel were breast cancer ($n = 417$, 87%), prostate cancer ($n = 23$, 5%), and lung cancer ($n = 16$, 3%). All patients received docetaxel 75 mg/m² once in 3 weeks (with standard dose modifications for poor performance status/age/prior toxicity). Patients received premedications including dexamethasone as per institutional protocol and were continued on oral dexamethasone for three more days.

Address for correspondence:

Dr. Prasanth Ganesan,
Department of Medical
Oncology, Cancer
Institute (WIA), Sardar Patel
Road, Adyar, Chennai - 600 036,
Tamil Nadu, India.
E-mail: prasanth.ganesan@
cancerinstitutewia.org

This is an open access journal, and articles are distributed under the terms of the Creative Commons Attribution-NonCommercial-ShareAlike 4.0 License, which allows others to remix, tweak, and build upon the work non-commercially, as long as appropriate credit is given and the new creations are licensed under the identical terms.

For reprints contact: reprints@medknow.com

How to cite this article: Manuprasad A, Ganesan P, Mahajan V, Ganesan TS, Radhakrishnan V, Dhanushkodi M, *et al.* Docetaxel-induced lung injury: An under-recognized complication of a commonly used chemotherapeutic agent. Indian J Med Paediatr Oncol 2019;40:208-11.

Access this article online

Website: www.ijmpo.org

DOI: 10.4103/ijmpo.ijmpo_59_18

Quick Response Code:



Table 1: Characteristics of patients with suspected docetaxel-induced lung injury

Number	Age	Stage	Rx setting	Number of cycles ^a	Number of days ^b	Growth factor ^c	Prior RT	Major symptom	Grade of pneumonitis	In-patient duration (days)	Outcome
1	38	III	NACT	3	18	No	Yes	Dyspnea	III	18	Resolution
2	65	IV	Palliative	3	23	No	No	Dyspnea	II	0	Resolution
3	42	III	NACT	3	28	No	No	Dyspnea	II	0	Resolution
4	40	IV	Palliative	4	17	No	Yes	Dyspnea	III	9	Resolution
5	55	III	Adjuvant	4	8	Yes	Yes	Dyspnea	III	8	Resolution
6	48	IV	Palliative	3	15	No	Yes	Cough	II	15	Resolution
7	36	II	NACT	3	12	No	Yes	Dyspnea	II	8	Resolution
8	45	IV	Palliative	3	15	No	No	Dyspnea	II	9	Resolution

^aNumber of cycles of docetaxel delivered before the occurrence of pulmonary toxicity; ^bNumber of days which had elapsed from the last dose of the docetaxel before the occurrence of pulmonary symptoms; ^cDuring the therapy with docetaxel. NACT – Neoadjuvant chemotherapy; RT – Radiation therapy

Clinical features

Among the 8 (1.7%) patients with possible docetaxel lung injury [Table 1], median age was 43 years (34–65 years). Four patients (50%) had metastatic disease (none had lung/pleural metastasis). Two patients (25%) were on neoadjuvant chemotherapy, and the other two (25%) were on adjuvant treatment. One patient had the preexisting pulmonary disease (localized bronchiectasis). Four patients had received prior radiation to the chest wall or dorsal spine as part of breast cancer treatment. One patient received docetaxel in combination with cyclophosphamide (600 mg/m²), and the other 7 received it as a single agent. Co-administered medications included pegylated granulocyte-colony-stimulating factor ($n = 1$) and zoledronic acid ($n = 1$).

Median number of cycles before the onset of pneumonitis was 3 (3–4). The median time from administration of the last dose was 16 days (8–28). The earliest occurrence of the toxicity was in 8 days in a 55-year-old female who received a combination of cyclophosphamide and docetaxel. Dyspnea was the most common presentation ($n = 7$) followed by cough ($n = 1$). None of the patients had a fever or pleuritic chest pain. All patients had a documented normal systolic cardiac function as evaluated by echocardiography.

Radiological features

All patients underwent chest-X-ray at admission, and high resolution computed tomography (CT) scan within 48 h of presentation [Figure 1]. All the patients presented with a pattern of diffuse interstitial pneumonitis. Most of the patients had bilateral involvement with diffuse ground-glass haziness and patchy parenchymal infiltrates with no site predominance. Diffuse peribronchiolar thickening with mosaic attenuation of lung parenchyma in the involved segment was the most common presentation [Figure 2]. One patient had mainly right-sided involvement more than left, and another patient had associated minimal reactive pleural effusion. With treatment, all the patients had a significant resolution of radiological abnormalities [Figure 3].

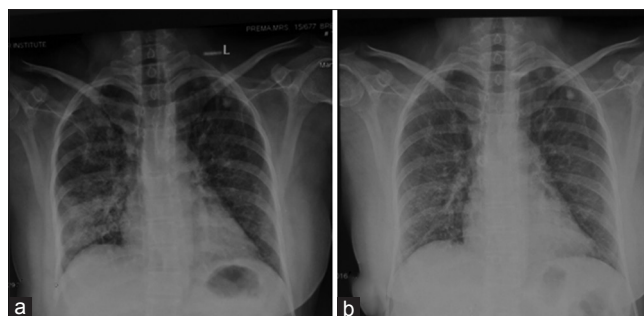


Figure 1: Pretreatment X-ray showing interstitial infiltrates involving mid and lower zones (a) with significant resolution after treatment (b)

Management and outcomes

Most ($n = 6/8$, 75%) required initial hospitalization. Three patients with CTCAE Grade 3 pneumonitis required oxygen support. Bronchoscopy was done in six patients—no airway abnormalities, inflammation, or secretions were noted in any of the studies. Bronchoalveolar fluid (BAL) was negative for acid-fast bacillus and fungal stains in all six. Although there was no fever, all the patients underwent workup for infectious causes and received empiric broad-spectrum antibiotics considering the severity of the symptoms. Furthermore, none of the patients were neutropenic. There was no response to antibiotics in any of these patients and all of these patients had significant improvement in their symptoms only after treatment with steroids.

All the patients were started oral prednisolone at a dose of 1 mg/kg and were tapered over 2–3 weeks in responding patients. In all but the 3 patients requiring oxygen support, prednisolone was started after 2–3 days of antibiotics and after CT scan images were reviewed. High dose cotrimoxazole was used to cover pneumocystis in one patient (based on radiological suspicion), which was discontinued after the negative BAL. Two patients required early taper due to hyperglycemia and due to herpes Zoster reactivation but remained symptom-free. In one patient, Tablet Pirfenidone was also started as per the advice of the pulmonologist. The median duration of

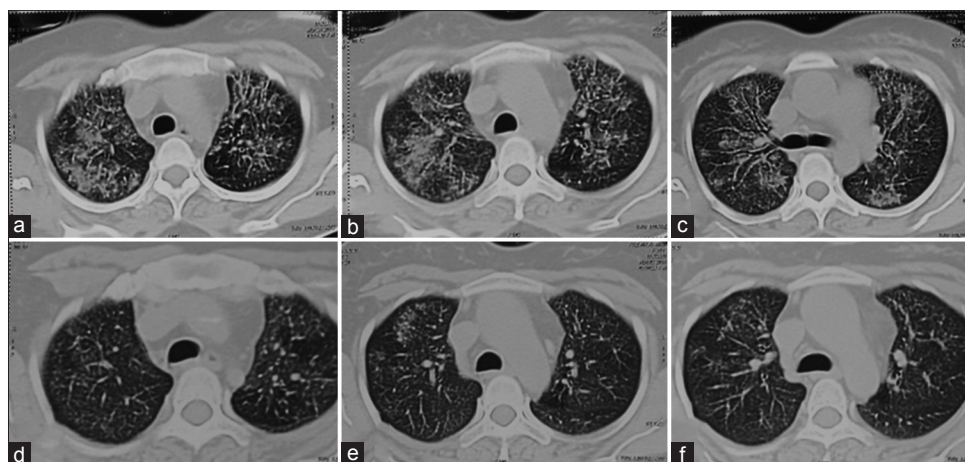


Figure 2: Pretreatment computed tomography scan - axial high resolution sections in lung windows show diffuse perihilar ground glass haziness and peribronchovascular thickening in bilateral mid zones (a-c). The same patient's posttreatment corresponding high resolution sections show marked resolution of the interstitial pneumonitis (d-f)

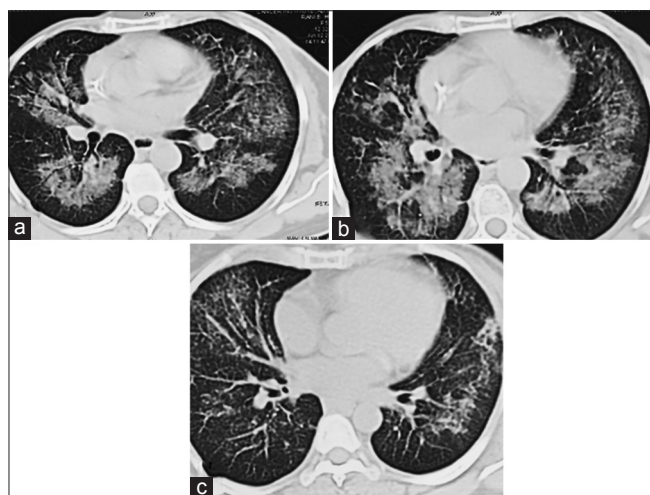


Figure 3: Pretreatment computed tomography scan - axial high resolution sections in lung windows show diffuse perihilar ground glass haziness and peribronchovascular thickening in bilateral mid zones (a and b). Posttreatment high resolution sections show significant improvement in the interstitial pneumonitis with patchy residual ground glass haziness (c)

hospital stay was 8.5 days (7–18 days). There was no recurrence of symptoms in any of the patients during subsequent follow-up. Anti-cancer therapy was resumed wherever indicated, but none were rechallenged with taxanes.

Discussion

Our audit identified a series of eight patients over a period of 1 year with possible docetaxel-induced acute lung injury. Although this is a rare complication of a relatively commonly used chemotherapeutic agent, it is well-recognized. The largest number of cases with pneumonitis (18 cases) were reported in a series of patients with lung cancer from Japan.^[1] Although one may suspect the diagnosis based on clinicoradiological information, the diagnosis of “docetaxel-induced pneumonitis” is a diagnosis of exclusion.^[4] In our series, the timing of onset of

symptoms, the interstitial pattern of infiltrates and response to steroids were the strong pointers toward the diagnosis of drug-induced lung injury. Although some patients did grow bacterial pathogens in the BAL fluid, lack of fever, the absence of response to antibiotics and radiology suggestive of an interstitial pattern of infiltration were all against a diagnosis of bacterial pneumonitis. Furthermore, there was no evidence to suggest pneumocystis infection after investigations including BAL.^[5]

All our patients received 3 weekly cycles of docetaxel, and the overall incidence was 1.7%. In the largest published series of docetaxel-related lung injury in patients with lung cancer ($n = 392$) incidence was 4.6%.^[1] However, more than two-third of patients in that series had preexisting lung abnormalities, unlike our patients. Combination of cyclophosphamide with docetaxel producing pneumonitis is also previously reported, and one of our patients had received this combination. Apart from preexisting lung diseases, use of drugs like gemcitabine and radiation exposure have also been associated with pneumonitis.^[6,7] In most of the series, patients develop pneumonitis 2–3 weeks after chemotherapy. However, there are case reports where this occurred as early as 3 days.^[8] Most of the patients presented during second to the fourth cycle of docetaxel similar to our report. However, it can be as early as one cycle and as late as nine cycles.^[6] To make sure this rare complication is not related to any particular brand, we checked the details of the batch number, brand and manufacturers which were different for each patient.

Although the exact mechanism of lung injury is debatable, the most common pattern of lung injury described is that of hypersensitivity pneumonitis.^[9] Some studies have reported that bronchoscopy and bronchoalveolar lavage may give some evidence to support the diagnosis of drug-induced pneumonitis based on lymphocytic alveolitis, leukocytosis, and a low CD4/CD8 ratio.^[4] Transbronchial lung biopsy may show nonspecific alveolar and interstitial edema with mononuclear cellular infiltrate.^[10]

Docetaxel-induced pneumonitis is a potentially serious complication with high mortality rates.^[6] In other reported cases also, prednisolone was the main drug used for treatment along with other supportive measures, and many of them required ventilatory support. In our series, all patients had a resolution of symptoms, and there was no mortality which was possibly due to early institution of steroids based on the atypical radiological findings. This is one of the largest series of possible docetaxel pneumonitis in patients with breast cancer.

Conclusions

Docetaxel-induced lung injury is a rare but well-described complication commonest form of presentation in interstitial pneumonitis. It is a diagnosis of exclusion and high index of suspicion is required to identify this uncommon problem. It should be considered as an important differential diagnosis in patients on docetaxel who presents with respiratory distress. Early detection and appropriate treatment including steroids are important to prevent mortality.

Financial support and sponsorship

Nil.

Conflicts of interest

There are no conflicts of interest.

References

1. Tamiya A, Naito T, Miura S, Morii S, Tsuya A, Nakamura Y, *et al.* Interstitial lung disease associated with docetaxel in patients with advanced non-small cell lung cancer. *Anticancer Res* 2012;32:1103-6.
2. Merad M, Le Cesne A, Baldeyrou P, Mesurolle B, Le Chevalier T. Docetaxel and interstitial pulmonary injury. *Ann Oncol* 1997;8:191-4.
3. Read WL, Mortimer JE, Picus J. Severe interstitial pneumonitis associated with docetaxel administration. *Cancer* 2002;94:847-53.
4. Nagata S, Ueda N, Yoshida Y, Matsuda H, Maehara Y. Severe interstitial pneumonitis associated with the administration of taxanes. *J Infect Chemother* 2010;16:340-4.
5. Hasskarl J, Schroettner P, von den Berg A, Rueckert A, Frydrychowicz A, Kayser G, *et al.* Severe organizing pneumonia after two cycles of docetaxel as fourth-line chemotherapy for advanced non-small cell carcinoma of the lung. *Case Rep Oncol* 2009;2:12-9.
6. Ochoa R, Bejarano PA, Glück S, Montero AJ. Pneumonitis and pulmonary fibrosis in a patient receiving adjuvant docetaxel and cyclophosphamide for stage 3 breast cancer: A case report and literature review. *J Med Case Rep* 2012;6:413.
7. Kouroussis C, Mavroudis D, Kakolyris S, Voloudaki A, Kalbakis K, Souglakos J, *et al.* High incidence of pulmonary toxicity of weekly docetaxel and gemcitabine in patients with non-small cell lung cancer: Results of a dose-finding study. *Lung Cancer* 2004;44:363-8.
8. Wang CJ, Chang HT, Chang CY. Docetaxel-related interstitial pneumonitis. *Ther Clin Risk Manag* 2015;11:1813-6.
9. Pankowska-Supryn M, Załęska M, Roszkowska-Śliż B, Roszkowski-Śliż K. Interstitial lung disease associated with docetaxel in a patient treated for breast cancer – A case report. *Pneumonol Alergol Pol* 2015;83:378-82.
10. Min BD, Kang HW, Kim WT, Kim YJ, Yun SJ, Lee SC, *et al.* Docetaxel-induced fatal interstitial pneumonitis in a patient with castration-resistant prostate cancer. *Korean J Urol* 2012;53:371-4.