

Hodgkin Variant of Richter's Transformation: Is Transplant Always an Answer?

Sir,
Richter's transformation (RT) is a rare dreaded complication in patients with chronic lymphocytic leukemia (CLL). The most common histology in RT is diffuse large B-cell lymphoma (DLBCL); other lymphomas such as Hodgkin disease, hairy cell lymphoma, and T-cell lymphoma are very scarcely reported. We report a case of Hodgkin variant of RT in CLL patient successfully treated with adriamycin, bleomycin, vinblastine, and dacarbazine (ABVD) and on follow-up for 5 years.

A 32-year-old male patient referred to our hospital in July 2008 with symptoms of fatigue and generalized lymphadenopathy. Clinical examination revealed Eastern Cooperative Oncology Group performance status 1 and mild pallor, generalized lymphadenopathy. His hemogram showed hemoglobin – 10.5 g/dL, total leukocyte count – $40 \times 10^9/L$, and platelet counts – $150 \times 10^9/L$. Peripheral blood smear examination showed normochromic normocytic anemia with 80% lymphoid cell. Flow cytometric analysis of peripheral blood revealed 80% CD19+, CD5+ abnormal lymphoid cell, which are positive of CD20 and CD23 and negative for FMC7 and CD3. Renal and liver functions were within the normal limit. Direct Coombs test was negative, and there are no features of hemolysis. Diagnosis of CLL Rai Stage III was made, and the patient was started fludarabine d1-3 (25 mg/m²) and cyclophosphamide d1-3 (250 mg/m²) each over 28 days. After six cycles, the disease was in complete remission. After a period of 4-year follow-up,

he developed progressive cervical lymphadenopathy and B symptoms, and imaging revealed supra- and infra-diaphragmatic disease. Histopathological examination of the cervical lymph node revealed Reed–Sternberg cells with typical morphology and immunophenotype (CD30+, Epstein–Barr virus [EBV] latent membrane protein-1 [LMP-1]+, CD3–, CD20–, and CD15–) associated with the characteristic polymorphous inflammatory background [Figure 1]. The final diagnosis, Hodgkin variant of RT Stage III, was made. He achieved complete remission after six cycles of ABVD. Given the lack of data for autologous stem cell transplantation (ASCT) and after discussing with the patient, we decided to observe him. The patient continues to be in complete remission after 5 years of RT.

The incidence and median time for the development of Hodgkin variant of RT in CLL patient is 0.1% to 0.5% and 2.6–6 years, respectively.^[1,2] Hodgkin variant can be clonally related or unrelated to CLL with longer survival seen in later cases.^[3] In our report, Hodgkin cells are clonally independent. The presence of EBV LMP-positive Reed–Sternberg cells supplements the hypothesis that marked prolonged immunosuppression in CLL (particularly with fludarabine therapy) leads to EBV-related B-cell proliferation with subsequent development of lymphoma-like hyperleukocytosis (HL). ABVD, mustargen, oncovin, procarbazine, and prednisone, and cyclophosphamide, oncovin, procarbazine, and prednisone regimens have been used in such cases with limited outcome. Prognosis is poor than *de novo* HL

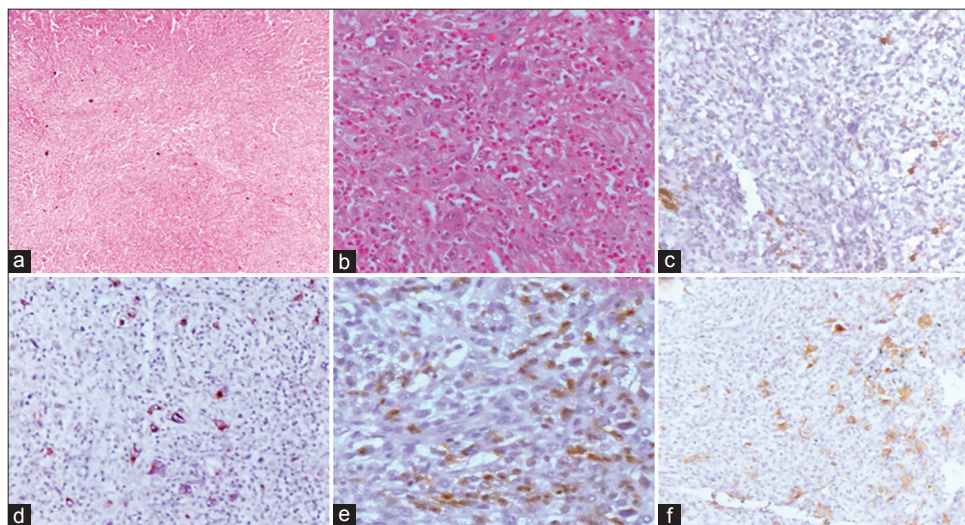


Figure 1: (a and b) Microphotograph shows effacement of architecture by polymorphous population of cells comprising eosinophils, histiocyte, and large mononuclear cell ([a] H and E, $\times 100$, [b] H and E, $\times 200$). The large cells are immunopositive for CD30 ([c] $\times 200$), Epstein–Barr virus latent membrane protein-1 ([d] $\times 200$) while negative for CD20 ([e] $\times 200$) and CD15 ([f] $\times 200$)

but better than DLBCL transformation of CLL. Median overall survival in largest series of Hodgkin variant of RT was only 8 months with few long-term survivors.^[3] The role of high-dose chemotherapy with ASCT and the subset of patients who benefit from it are not well defined in Hodgkin variant of RT unlike DLBCL variant. We described the good response with ABVD therapy, reserving the ASCT at the time of progression if needed. In conclusion, our case highlights that Hodgkin variant of CLL can have heterogeneous course and not all patients may require transplant in this variant. ABVD can be considered as a reasonable option with good outcome. More insights into predictive and prognostic factors are required to select patients who will benefit from high-dose chemotherapy with ASCT.

Declaration of patient consent

The authors certify that they have obtained all appropriate patient consent forms. In the form the patient(s) has/have given his/her/their consent for his/her/their images and other clinical information to be reported in the journal. The patients understand that their names and initials will not be published and due efforts will be made to conceal their identity, but anonymity cannot be guaranteed.

Financial support and sponsorship

Nil.

Conflicts of interest

There are no conflicts of interest.

**Ilavarasi Vanidassane, Ajay Gogia,
Vinod Sharma, Soumya Mallick¹**

Departments of Medical Oncology and ¹Pathology, All India Institute of Medical Sciences, New Delhi, India

Address for correspondence:

*Dr. Ajay Gogia,
Department of Medical Oncology, All India Institute of Medical Sciences,
New Delhi, India.
E-mail: ajaygogia@gmail.com*

References

1. Bockorny B, Codreanu I, Dasanu CA. Hodgkin lymphoma as Richter transformation in chronic lymphocytic leukaemia: A retrospective analysis of world literature. *Br J Haematol* 2012;156:50-66.
2. Parikh SA, Habermann TM, Chaffee KG, Call TG, Ding W, Leis JF, *et al.* Hodgkin transformation of chronic lymphocytic leukemia: Incidence, outcomes, and comparison to de novo Hodgkin lymphoma. *Am J Hematol* 2015;90:334-8.
3. Tsimberidou AM, O'Brien S, Kantarjian HM, Koller C, Hagemester FB, Fayad L, *et al.* Hodgkin transformation of chronic lymphocytic leukemia: The M. D. Anderson cancer center experience. *Cancer* 2006;107:1294-302.

This is an open access journal, and articles are distributed under the terms of the Creative Commons Attribution-NonCommercial-ShareAlike 4.0 License, which allows others to remix, tweak, and build upon the work non-commercially, as long as appropriate credit is given and the new creations are licensed under the identical terms.

Access this article online	
Quick Response Code: 	Website: www.ijmpo.org
	DOI: 10.4103/ijmpo.ijmpo_71_18

How to cite this article: Vanidassane I, Gogia A, Sharma V, Mallick S. Hodgkin variant of Richter's transformation: Is transplant always an answer? *Indian J Med Paediatr Oncol* 2019;40:307-8.

©2019 Indian Journal of Medical and Paediatric Oncology | Published by Wolters Kluwer - Medknow