

## Study of Clinicopathological Spectrum and Pattern of Expression of Cyclooxygenase-2 in Urothelial Carcinomas of Bladder

### Abstract

**Introduction:** Overexpression of cyclooxygenase-2 (COX2) in urothelial carcinoma of bladder (UCB) had been studied in the past by different workers and the results were contradictory. The objective of the present study was to evaluate the prognostic implication of COX2 expression in primary urothelial carcinomas of the urinary bladder and its correlation with clinical parameters, tumor stage, grade, and recurrence. **Materials and methods:** A total of 68 cases who underwent surgery for urothelial carcinoma in our medical college from January 2013 to December 2015 were evaluated in our study. Hematoxylin and eosin-stained slides were examined by two faculties applying standard reporting protocol. Tumor staging and grading was performed as per the WHO guidelines. Immunohistochemistry for expression of COX2 was performed to study any correlation of tumor grade with COX2 expression. The distribution of COX2 positivity was studied in tumors stratified according to established bladder cancer prognostic factor, for example, tumor size, grade, invasion, and spread. **Results:** Out of 68 cases, 42 cases showed COX2 positivity (61%). In low-grade cases of bladder carcinoma, COX2 positivity was 16 out of 24 cases (60%), and in high-grade cases, COX2 positivity was 10 out of 18 cases (64.28%). **Conclusion:** In the present study, the association of COX2 overexpression with advanced tumor invasion and tumor grade has been substantiated. Hence, COX2 expression can be taken as a prognostic factor along with other usual prognostic factors in patients of UCB.

**Keywords:** Cyclooxygenase-2 expression, urothelial carcinoma, tumor grade

### Introduction

Urothelial carcinoma of bladder (UCB) is the second most common genitourinary malignancy.<sup>[1,2]</sup> It is the 7<sup>th</sup> most common malignancy in men and 17<sup>th</sup> in women.<sup>[3]</sup> The mortality of transitional cell carcinoma (TCC) of urinary bladder increases significantly with the progression of superficial or locally invasive disease (pTa/pT<sub>1</sub>) to detrusor muscle invasive disease (pT<sub>2</sub>).<sup>[4]</sup> Radical cystectomy with bilateral pelvic lymph node dissection is currently the gold standard treatment for muscle invasive UCB.<sup>[2,5,6]</sup> The most common prognostic markers in clinical use for these tumors are tumor stage and grade, which are subject to considerable intra- and inter-observer variation.<sup>[4]</sup> It is noted that about 40% of patients with organ-confined disease at the time of cystectomy subsequently suffer recurrence. Due to this high recurrence rate, there is a need for close follow-up throughout the patient's lifetime.<sup>[7]</sup>

Advanced pathological stage, nodal involvement, grade, and urinary obstruction have been reported as prognostic factors for survival and recurrence. However, many UCB with similar stage and grade have demonstrated variable clinical outcome after radical cystectomy.

Hence, many attempts have been made to determine new and reliable prognostic factors.<sup>[8-11]</sup>

Many recent scientific studies show that chronic inflammation may positively influence the risk of UCB. Furthermore, studies investigating the prolonged use of cyclooxygenase-2 (COX2) inhibiting nonsteroidal anti-inflammatory drugs have reported a decrease in UCB risk.<sup>[12,13]</sup>

Few studies have shown that bladder tissue from patients with cystitis or UCB exhibits elevated COX2 levels in contrast to benign bladder tissue.<sup>[14]</sup>

This is an open access article distributed under the terms of the Creative Commons Attribution-NonCommercial-ShareAlike 3.0 License, which allows others to remix, tweak, and build upon the work non-commercially, as long as the author is credited and the new creations are licensed under the identical terms.

For reprints contact: reprints@medknow.com

**How to cite this article:** Bandyopadhyay R, Bandyopadhyay U, Chatterjee U, Naskar S, Nandy S, Basu K. Study of clinicopathological spectrum and pattern of expression of Cyclooxygenase-2 in urothelial carcinomas of bladder. *Indian J Med Paediatr Oncol* 2018;39:172-7.

**Ranjana Bandyopadhyay, Ujjwal Bandyopadhyay, Uttara Chatterjee<sup>1</sup>, Sukla Naskar, Sumit Nandy, Keya Basu**

*Department of Pathology, Calcutta National Medical College, <sup>1</sup>Department of Pathology, Institute of Post Graduate Medical Education and Research, Kolkata, West Bengal, India*

**Address for correspondence:**  
Dr. Ujjwal Bandyopadhyay,  
P-60 Kalindi Housing Scheme,  
Kolkata - 700 089, West Bengal,  
India.  
E-mail: ujjwal.kalindi@gmail.com

Access this article online

Website: www.ijmpo.org

DOI: 10.4103/ijmpo.ijmpo\_81\_17

Quick Response Code:



Furthermore, studies of tumor chemotherapy show that selective increase in tumor cytotoxicity relative to normal tissue can be achieved by inhibition of angiogenic inducers which are frequently present in bladder tumor. Several studies have correlated elevated vascular endothelial growth factor (VGEF) level or COX2 expression with disease recurrence or progression often as an independent prognostic factor by multivariate analysis.<sup>[15,16]</sup>

This is the basis of combining anti-VGEF therapy or COX2 inhibitors with other forms of cytotoxic therapy in prospective clinical trials. While numerous study groups have investigated in different ways, the expressions of COX2 in UCB as a potential prognostic indicator, there is no clear consensus yet.<sup>[15-18]</sup> Hence, our present study was formulated, and objective of our present study is to evaluate the prognostic implication of COX2 expression in primary urothelial carcinomas of the urinary bladder and its correlation with clinical parameters, tumor stage, grade, and recurrence.

## Materials and Methods

A total of 68 cases who underwent surgery for TCC in our institute from January 2013 to December 2015 were included in the study.

Both transurethral resection and radical cystectomy cases were taken. Sections were examined by two faculties applying standard reporting protocol. Tumor staging and grading was performed as per the WHO guidelines.

Tumor differentiation, invasion depth, lymphovascular invasion (LVI), perineural invasion (PNI), necrosis, mitosis, and perivesical tumor spread were assessed histopathologically.

The association of age, gender, LVI, PNI, metastasis, necrosis, mitosis, and COX2 expression with pathological tumor grade and stage was evaluated and statistically analyzed.

Formalin-fixed, paraffin-embedded tissue sections were used for hematoxylin and eosin (H and E) staining and morphological diagnosis. A 2 µm thick paraffin-embedded section on poly-L-lysine-coated slide was taken for immunohistochemistry (IHC). Antigen retrieval was done by heat treatment using microwave oven. IHC for COX2 expression was performed using rabbit monoclonal antibody to COX2 and Super Sensitive polymer-based detection system (Biogenex). Negative and positive controls were put up side by side.

Interpretation of COX2 immunostaining was then performed by two pathologists selecting the maximum positive area with strongest positive intensity and expressing it in a percentage.<sup>[19]</sup> The grading of COX2 expression was done semi-quantitatively. Positive staining pattern was graded as: undetected, mild (expressed in 10% tumor cells), moderate (10%–50% positive tumor cells), and strong (>50% positive tumor cells).<sup>[19,20]</sup> For statistical analysis, undetected and mild cases were categorized

as low and moderate and strong cases as high COX2 expression.<sup>[19]</sup> H and E-stained section was examined first and representative areas were identified. Those areas were examined in IHC slides by conventional microscopy.<sup>[19]</sup>

## Results

Age range of the patients included in the study was 45–82 years with median 60.20 years. Out of 68 patients, 56 were male and 12 female. Five patients were below 50 years of age (all male). Hence, our data are confirming the fact that bladder carcinoma is more common in male compared to female patients<sup>[5]</sup> [Table 1].

Out of 56 male patients, smoking could be elucidated in 30 patients from personal history as found from history sheets. Twenty-six patients are nonsmoker. None of the 12 female patients were smoker.

Out 68 patients, 65 patients had a history of hematuria and 2 patients presented with pain hypogastrium and frequency of micturition but without hematuria in history. One patient was asymptomatic and diagnosed during real-time checkup (ultrasonography whole abdomen).

In the present study, 38 patients had tumor size >3 cm and 30 patients with tumor size ≤3 cm. In 12 cases, tumor size was missing in case history. Relation of COX2 expression and tumor size is presented in Table 2.

Forty out of 68 patients had high-grade TCC (male - 33 and female - 7) and 28 patients had low-grade TCC (male - 23 and female - 5) [Table 3].

Out of 25 cases in stage T2, 48% showed COX2 positivity. In T3 and T4 cases, COX 2 positivity were 66% and 73%. [Table 4].

Lymphnode metastasis was present in 36 out of 68 cases. 66% of node positive cases showed cox-2 positivity [Table 5]

Both LVI and PNI were found in 40 cases out of 68 cases. Only LVI was seen in 44 cases and only PNI was seen in

**Table 1: Age and sex variation in bladder tumor with cyclooxygenase-2 expression**

Age	Total number	COX2-positive cases	COX2-negative cases
<50 years	5 (all males)	4 (male - 4)	1 (male - 1)
50 years or more	63 (female - 12, male - 51)	38 (female - 7, male - 31)	25 (female - 5, male - 20)

COX2 – Cyclooxygenase-2

**Table 2: Tumor size and cyclooxygenase-2 expression**

Tumor size	Total cases	COX2-positive cases (%)	COX2-negative cases
3 cm or less	26	14 (53.8)	12
>3 cm	30	20 (66.6)	10

COX2 – Cyclooxygenase-2

7 cases. Tumor distant metastasis was seen in total 20 cases who underwent radical cystectomy [Table 6].

Concomitant carcinoma *in situ* was observed in 19 cases (29%). Forty cases (58.8%) showed tumor necrosis [Table 7].

COX2 expression was also studied in total 68 cases. The distribution of COX2 positivity was also studied according to established bladder cancer prognostic factor, for example, tumor size, grade, invasion, and spread. Out of 68 cases, 42 cases showed COX2 positivity (61%) and 26 cases came out as COX2 negative.

COX2 positivity was seen in 60% cases of Grade II UCB (i.e., 16 out of 24 cases) [Figures 1 and 2] and 64.28%

cases of Grade III UCB (10 out of 18 cases) [Figures 3 and 4]. It was found in the study that COX2 positivity was 80% in UCB showing LVI (32 out of 40 cases) [Table 8]. About 75% cases that showed PNI, showed COX2 positivity [Table 9].

**Discussion**

UCB is the 7<sup>th</sup> most common malignancy in men and 17<sup>th</sup> in women.<sup>[3]</sup> As a whole, UCB is the 2<sup>nd</sup> most common genitor urinary malignancy.<sup>[1,2]</sup> Mortality of UCB increases significantly with the progression of superficial and locally invasive disease (pT<sub>a</sub>/pT<sub>1</sub>) to detrusor muscle invasive

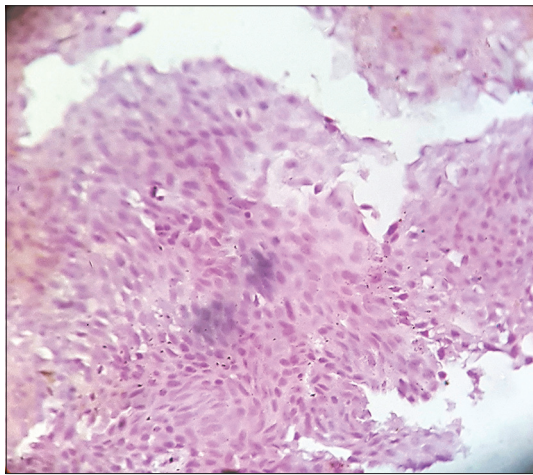


Figure 1: Low-grade urothelial carcinoma, immunohistochemistry showing negative cyclooxygenase-2 expression (×100)

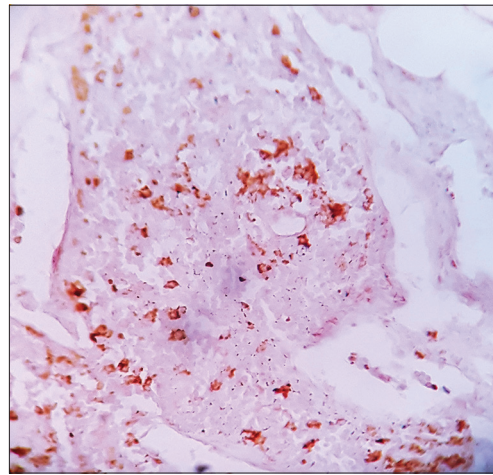


Figure 2: Low-grade urothelial carcinoma, immunohistochemistry showing weak cyclooxygenase-2 expression (×100)

**Table 3: Tumor grade and cyclooxygenase-2 expression**

Tumor grade	Total cases	COX2-positive cases (%)	COX2-negative cases
low grade	40	24 (60)	16
High grade	28	18 (64.28)	10

COX2 – Cyclooxygenase-2

**Table 4: Stage of tumor and cyclooxygenase-2 expression**

Tumor invasion	Total cases	COX2-positive cases (%)	COX2-negative cases
T2	25	12 (48)	13
T3	24	16 (66.6)	08
T4	19	14 (73.6)	05

COX2 – Cyclooxygenase-2

**Table 5: Lymph node metastasis and cyclooxygenase-2 expression**

Lymphatic invasion	Total cases	COX2-positive cases (%)	COX2-negative cases
N0	18	11 (61.11)	7
N1, N3	36	24 (66.6)	12
Nx	14	5	9

COX2 – Cyclooxygenase-2

**Table 6: Cyclooxygenase-2 expression and distant metastatic tumor**

Metastasis	Total cases	COX2-positive cases (%)	COX2-negative cases
M0	20	12 (60)	8
M1	20	15 (75)	15
Mx	28	15 (53.5)	13

COX2 – Cyclooxygenase-2

**Table 7: Cyclooxygenase-2 expression and histopathological features**

COX2 expression	Tumor necrosis (%)	Concomitant carcinoma <i>in situ</i> (%)
Negative	36 (52.9)	40 (58.8)
Positive	32 (47)	28 (41.1)

COX2 – Cyclooxygenase-2

**Table 8: Cyclooxygenase-2 expression in tumors showing lymphovascular invasion**

LVI	Total cases	COX2-positive cases (%)	COX2-negative cases
Present	40	32 (80)	8
Absent	28	10 (35.7)	18

LVI – Lymphovascular invasion; COX2 – Cyclooxygenase 2

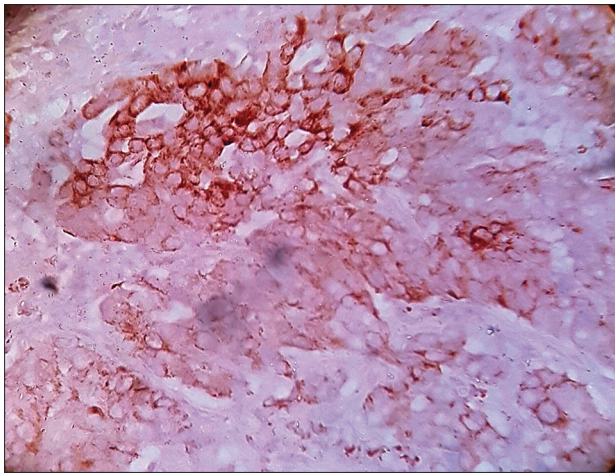


Figure 3: High-grade urothelial carcinoma, immunohistochemistry showing strong cyclooxygenase-2 expression (x400)

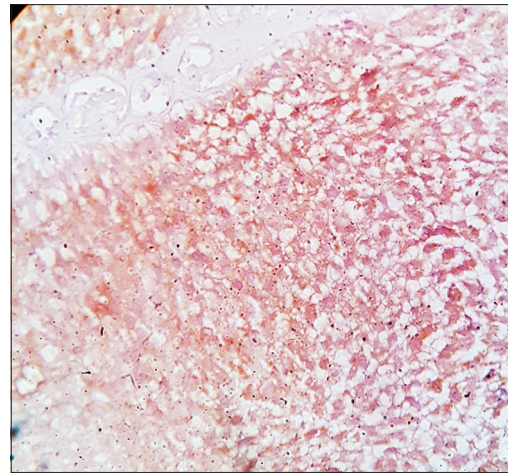


Figure 4: High-grade urothelial carcinoma, immunohistochemistry showing moderate cyclooxygenase-2 expression (x400)

**Table 9: Cyclooxygenase-2 expression in tumors showing perineural invasion**

PNI	Total cases	COX2-positive cases (%)	COX2-negative cases
Present	35	26 (74.28)	9
Absent	33	16 (48.4)	17

PNI – Perineural invasion; COX2 – Cyclooxygenase-2

disease (pT<sub>2</sub>).<sup>[4]</sup> Recently, the pathological stage of tumor and the presence of lymph node metastasis (LNM) have been pointed out as two most important prognostic factors.<sup>[4]</sup>

However, there are several other factors defining the prognosis of UCB even with treatment, and review of literature shows that though numerous study groups have investigated in different ways, the expression of COX2 in UCB as a potent prognostic factor, there is no clear consensus about that till now. Despite many published studies, contradictory findings predominate on COX2 expression as a prognostic marker of UCB.<sup>[15-18]</sup>

Prognosis of UCB in female is much worse than in male. Large European epidemiological study of 1.2 million cancer patients reported a 30% lower mortality in female with respect to male.<sup>[5]</sup> However, the study also demonstrated that UCB followed a more aggressive clinical course in female than in male.<sup>[21-23]</sup> In the present study, most of patients were male (56 out of 68) and only 12 patient female. Due to small number of female patients in this study group, a statistically significant relationship could not be elucidated.

LNM has been noted in 25% cases undergoing cystectomy.<sup>[24]</sup> In the present study, it was 29%, which is in consistence with the literature.

Previous studies have reported that rate of LVI ranges from 35% to 55% in muscle invasive bladder carcinoma (MIBC).<sup>[25,26]</sup> We assessed LVI in H and E stained section and it was 60%. The higher rate of LVI is

probably due to difficulty in distinguishing LVI from tissue retraction artifacts. Hence, associated IHC study to detect LVI may be more helpful in these cases.

Previous studies reveal controversial results regarding PNI as prognostic factor.<sup>[27]</sup> Some studies have reported that PNI is associated with LNM and distant metastasis, whereas other studies have shown that tumor stage, LNM, urethral obstruction, LVI, and PNI are significant prognostic factors on univariate analysis;<sup>[24-27]</sup> however, on multivariate analysis, it comes out that only tumor stage and LNM are independent prognostic factors.<sup>[24-27]</sup> In our present study, PNI is present in 51.5% cases and LVI is noted in 60% cases.

Despite many published articles, findings are rather contradictory regarding COX2 expression as prognostic marker in UCB patients. In the present study, we have found 61.7% positivity for COX2 expression (42 out of 68 cases) [Figure 1 and 2]. Using the largest patient cohort with nonmuscle invasive bladder carcinoma (NMIBC), the result was 38%.<sup>[19,28]</sup> Other study groups have reported frequencies ranging from (53% to 88%).<sup>[16]</sup> However, these studies used different COX2 antibodies and expression evaluation technique and had smaller sample size.<sup>[29,30]</sup> However, COX2 positivity appears as 58% in MIBCs in study with large patient cohort which is similar to our findings of 61.7% positivity of COX2 in transitional cell carcinoma of bladder.<sup>[19,28]</sup> This frequency is also similar to that observed in other large histologically homogeneous studies.<sup>[19,28,31-33]</sup>

In review of literature,<sup>[29,31]</sup> we have found that there is a significant association between COX2 overexpression with advanced tumor grade and invasion. Given the known disparity in COX2 expression between NMIBC and MIBC, few studies show a strong association between COX2 overexpression and advanced tumor grade in pooling cohort of NMIBC and MIBC.<sup>[19,29,31]</sup> In our study, we have found 60% COX2 positivity in Group 2 and 64.28% positivity in Group 3 cases of MIBC.

Shirahama *et al.*<sup>[32]</sup> in a study of COX2 distribution observed 8% positivity in pT1 tumor and 50% positivity and pT2 tumor.<sup>[32]</sup> In our study, we have seen similar results that are 48% COX2 positivity in pT2, 66.6% positivity in pT3, and 73.6% positivity in pT4 cases.

In our study, we have seen 53.8% COX2 positivity in tumors with size  $\leq 3$  cm and a 66.6% positivity in tumor size with  $>3$  cm.

We have also found 60% COX2 positivity in M0 UCB and 75% COX2 positivity in M1 UCB. Furthermore, COX2 positivity was 61.1% in N<sub>0</sub> lymphatic invasion cases and 66.6% in N<sub>1</sub>-N<sub>3</sub> lymphatic invasion cases.

The results are similar to those in other publication, indicating the fact that COX2 expression may be taken as an important prognostic factor in case of UCB study<sup>[19,20,28-32,34]</sup>

The results presented herein focus on COX2 expression levels measured in tumor epithelial cells which is only one aspect of the complex interplay between the tumor and the host inflammatory response. Furthermore, in experimental models of cervical cancers, Farrandina *et al.*<sup>[19,33]</sup> observed that while COX2 expression was mutually exclusive in the tumors and stromal inflammatory cells, high expression of COX2 in both cell types could be used as independent prognostic markers.<sup>[19,20,33]</sup>

Apart from the importance of COX2 as an important prognostic factor in bladder carcinoma, new avenues are coming in light regarding role of anti-COX2 drugs in treatment and preventions of bladder and colorectal cancers.<sup>[34,35]</sup> Currently, a large clinical study<sup>[35]</sup> examining inhibition of COX2 and recurrence of bladder cancer is ongoing at The University of Texas M. D. Anderson Cancer Center, Houston. This study is designed to compare the time to recurrence following treatment with celecoxib (COX2 inhibitor) or placebo in patients with superficial TCC of the bladder at high risk for recurrence. This study will also correlate the modulation of one or more biomarkers with recurrence of bladder cancer and evaluate the quality of life of patients enrolled in the study.<sup>[35]</sup> Moreover, one step forward, future studies investigating the prognostic value of COX2 expression in UCB should also take into consideration the multifactorial context of the inflammatory response during carcinogenesis.<sup>[34]</sup>

## Conclusion

Data indicate that selective inhibition of COX2 may be an effective strategy for preventing Colorectal and bladder cancer also may have application in other cancers. Furthermore, because COX2 overexpression has been observed in both preneoplastic lesions and cancers, chemoprevention and intervention is possible at multiple stages of carcinogenesis.

Recently, the pathological stage of tumor and the presence of LNM have been pointed out as two most important

prognostic factors. However, there are several other factors defining the prognosis of UCB even with treatment. Here, in our present study, we have substantiated the fact that COX2 overexpression is associated with advanced tumor invasion and tumor grade which is in accordance with other published articles. Hence, COX2 expression can be taken as a prognostic factor along with other usual prognostic factors in study of patients of UCB. In this line, future research may take the avenue of study of multifactorial context of the inflammatory response during carcinogenesis. Furthermore, importance of COX2 expression by bladder cancer also lies in the fact that potential role of few anti-COX2 agents in the prevention, treatment, and recurrence prevention for bladder cancer is already in evaluation study.

## Financial support and sponsorship

Nil.

## Conflicts of interest

There are no conflicts of interest.

## References

1. May M, Bastian PJ, Brookman-May S, Fritsche HM, Tilki D, Otto W, *et al.* Gender-specific differences in cancer-specific survival after radical cystectomy for patients with urothelial carcinoma of the urinary bladder in pathologic tumor stage T4a. *Urol Oncol* 2013;31:1141-7.
2. Bruins HM, Arends TJ, Pelkman M, Hulsbergen-van de Kaa CA, van der Heijden AG, Witjes JA. Radical cystectomy in a Dutch University hospital: Long-term outcomes and prognostic factors in a homogeneous surgery-only series. *Clin Genitourin Cancer* 2014;12:190-5.
3. Ploeg M, Aben KK, Kiemeny LA. The present and future burden of urinary bladder cancer in the world. *World J Urol* 2009;27:289-93.
4. Latif Z, Watters AD, Dunn I, Grigor KM, Underwood MA, Bartlett JM. HER2/neu overexpression in the development of muscle-invasive transitional cell carcinoma of the bladder. *Br J Cancer* 2003;89:1305-9.
5. Otto W, May M, Fritsche HM, Dragun D, Aziz A, Gierth M, *et al.* Analysis of sex differences in cancer-specific survival and perioperative mortality following radical cystectomy: Results of a large German multicenter study of nearly 2500 patients with urothelial carcinoma of the bladder. *Gen Med* 2012;9:481-9.
6. May M, Stief C, Brookman-May S, Otto W, Gilfrich C, Roigas J, *et al.* Gender-dependent cancer-specific survival following radical cystectomy. *World J Urol* 2012;30:707-13.
7. Botteman MF, Pashos CL, Redaelli A, Laskin B, Hauser R. The health economics of bladder cancer: A comprehensive review of the published literature. *Pharmacoeconomics* 2003;21:1315-30.
8. Hong SK, Kwak C, Jeon HG, Lee E, Lee SE. Do vascular, lymphatic, and perineural invasion have prognostic implications for bladder cancer after radical cystectomy? *Urology* 2005;65:697-702.
9. Zigeuner R, Shariat SF, Margulis V, Karakiewicz PI, Roscigno M, Weizer A, *et al.* Tumour necrosis is an indicator of aggressive biology in patients with urothelial carcinoma of the upper urinary tract. *Eur Urol* 2010;57:575-81.
10. Xylinas E, Rink M, Robinson BD, Lotan Y, Babjuk M,

- Brisuda A, *et al.* Impact of histological variants on oncological outcomes of patients with urothelial carcinoma of the bladder treated with radical cystectomy. *Eur J Cancer* 2013;49:1889-97.
11. Mitra AP, Bartsch CC, Bartsch G Jr, Miranda G, Skinner EC, Daneshmand S. Does presence of squamous and glandular differentiation in urothelial carcinoma of the bladder at cystectomy portend poor prognosis? An intensive case-control analysis. *Urol Oncol* 2014;32:117-27.
  12. Wheeler MA, Hausladen DA, Yoon JH, Weiss RM. Prostaglandin E2 production and cyclooxygenase-2 induction in human urinary tract infections and bladder cancer. *J Urol* 2002;168(4 Pt 1):1568-73.
  13. Shirahama T. Cyclooxygenase-2 expression is up-regulated in transitional cell carcinoma and its preneoplastic lesions in the human urinary bladder. *Clin Cancer Res* 2000;6:2424-30.
  14. Diamantopoulou K, Lazaris A, Mylona E, Zervas A, Stravodimos K, Nikolaou I, *et al.* Cyclooxygenase-2 protein expression in relation to apoptotic potential and its prognostic significance in bladder urothelial carcinoma. *Anticancer Res* 2005;25:4543-9.
  15. Eltze E, Wülfing C, Von Struensee D, Piechota H, Buerger H, Hertle L. Cox-2 and Her2/neu co-expression in invasive bladder cancer. *Int J Oncol* 2005;26:1525-31.
  16. Friedrich MG, Toma MI, Petri S, Huland H. Cyclooxygenase-2 promotes angiogenesis in pTa/T1 urothelial bladder carcinoma but does not predict recurrence. *BJU Int* 2003;92:389-92.
  17. Gudjónsson S, Bendahl PO, Chebil G, Höglund M, Lindgren D, Lundberg LM, *et al.* Can tissue microarray-based analysis of protein expression predict recurrence of stage Ta bladder cancer? *Scand J Urol Nephrol* 2011;45:270-7.
  18. Hilmy M, Campbell R, Bartlett JM, McNicol AM, Underwood MA, McMillan DC. The relationship between the systemic inflammatory response, tumour proliferative activity, T-lymphocytic infiltration and COX-2 expression and survival in patients with transitional cell carcinoma of the urinary bladder. *Br J Cancer* 2006;95:1234-8.
  19. Czachorowski MJ, Amaral AF, Montes-Moreno S, Lloreta J, Carrato A, Tardón A, *et al.* Cyclooxygenase-2 expression in bladder cancer and patient prognosis: Results from a large clinical cohort and meta-analysis. *PLoS One* 2012;7:e45025.
  20. Hsu FS, Hsin C, Tu PY, Pu SY. The role of cyclooxygenase-2 expression in chemoresistance and invasiveness of urothelial carcinoma. *Imp J Interdiscip Res* 2016;2:979-86.
  21. Fajkovic H, Halpern JA, Cha EK, Bahadori A, Chromecki TF, Karakiewicz PI, *et al.* Impact of gender on bladder cancer incidence, staging, and prognosis. *World J Urol* 2011;29:457-63.
  22. Cao D, Vollmer RT, Luly J, Jain S, Roytman TM, Ferris CW, *et al.* Comparison of 2004 and 1973 World Health Organization grading systems and their relationship to pathologic staging for predicting long-term prognosis in patients with urothelial carcinoma. *Urology* 2010;76:593-9.
  23. Babjuk M, Oosterlinck W, Sylvester R, Kaasinen E, Böhle A, Palou-Redorta J, *et al.* EAU guidelines on non-muscle-invasive urothelial carcinoma of the bladder, the 2011 update. *Eur Urol* 2011;59:997-1008.
  24. Stein JP, Quek ML, Skinner DG. Lymphadenectomy for invasive bladder cancer: I. historical perspective and contemporary rationale. *BJU Int* 2006;97:227-31.
  25. Lotan Y, Gupta A, Shariat SF, Palapattu GS, Vazina A, Karakiewicz PI, *et al.* Lymphovascular invasion is independently associated with overall survival, cause-specific survival, and local and distant recurrence in patients with negative lymph nodes at radical cystectomy. *J Clin Oncol* 2005;23:6533-9.
  26. Hara S, Miyake H, Fujisawa M, Okada H, Arakawa S, Kamidono S, *et al.* Prognostic variables in patients who have undergone radical cystectomy for transitional cell carcinoma of the bladder. *Jpn J Clin Oncol* 2001;31:399-402.
  27. Leissner J, Koeppen C, Wolf HK. Prognostic significance of vascular and perineural invasion in urothelial bladder cancer treated with radical cystectomy. *J Urol* 2003;169:955-60.
  28. Yoshimura R, Sano H, Mitsuhashi M, Kohno M, Chargui J, Wada S. Expression of cyclooxygenase-2 in patients with bladder carcinoma. *J Urol* 2001;165:1468-72.
  29. Wild PJ, Kunz-Schughart LA, Stoehr R, Burger M, Blaszyk H, Simon R, *et al.* High-throughput tissue microarray analysis of COX2 expression in urinary bladder cancer. *Int J Oncol* 2005;27:385-91.
  30. Wülfing C, Eltze E, von Struensee D, Wülfing P, Hertle L, Piechota H. Cyclooxygenase-2 expression in bladder cancer: Correlation with poor outcome after chemotherapy. *Eur Urol* 2004;45:46-52.
  31. Margulis V, Shariat SF, Ashfaq R, Thompson M, Sagalowsky AI, Hsieh JT, *et al.* Expression of cyclooxygenase-2 in normal urothelium, and superficial and advanced transitional cell carcinoma of bladder. *J Urol* 2007;177:1163-8.
  32. Shirahama T, Arima J, Akiba S, Sakakura C. Relation between cyclooxygenase-2 expression and tumor invasiveness and patient survival in transitional cell carcinoma of the urinary bladder. *Cancer* 2001;92:188-93.
  33. Ferrandina G, Lauriola L, Zannoni GF, Distefano MG, Legge F, Salutati V, *et al.* Expression of cyclooxygenase-2 (COX-2) in tumour and stroma compartments in cervical cancer: Clinical implications. *Br J Cancer* 2002;87:1145-52.
  34. Matsuo T, Miyata Y, Mipsunari K. Pathological significance and prognostic implications of heme oxygenase1 expression in non muscle invasive bladder cancer: Correlation with cell proliferation, angiogenesis, lymphangiogenesis and expression of VEGFs and cox2. *Oncol Lett* 2017;13:275-80.
  35. Prabhu B, Balakrishnan D, Sundaresan S. Antiproliferative and anti-inflammatory properties of diindolylmethane and luteol against N-butyl-N-(4-hydroxybutyl) nitrosamine induced bladder carcinogenesis in experimental rats. *Hum Exp Toxicol* 2016;35:685-92.