

Original Article

Contralateral lumbo-umbilical flap: A versatile technique for volar finger coverage

Akram Hussain Bijli, Sheikh Adil Bashir, Altaf Rasool, Mir Yasir, Adil Hafeez Wani, Tanveer Ahmad, Mushtaq Ahmad

Department of Plastic and Reconstructive Surgery, SKIMS, Srinagar, Jammu and Kashmir, India

Address for correspondence: Dr. Mir Yasir, Department of Plastic and Reconstructive Surgery, SKIMS, Soura, Srinagar - 190 011, Jammu and Kashmir, India. E-mail: dmiryasir@yahoo.co.in

ABSTRACT

Background: While contemplating any difficult soft tissue reconstruction, patient comfort and compliance is of paramount importance. Reconstruction of the volar aspect of fingers and hand by the ipsilateral pedicled flaps (groin flap, abdominal flaps) is demanding as the flap inset is difficult for the surgeon and very uncomfortable for the patient. This often leads to flap complications. For the comfort of the patient, better compliance and ease of complete inset, we planned to manage soft tissue defects of the volar aspect of fingers and hand by a new contralateral pedicled lumbo-umbilical flap. This flap is based on the paraumbilical perforators of deep inferior epigastric artery. **Materials and Methods:** The contralateral pedicled lumbo-umbilical flap was used in eight patients with high-tension electrical burn injuries involving the volar aspect of fingers and hand. The patients were closely observed for first 6 weeks for any flap or donor site complications and then followed monthly to assess donor and recipient site characteristics for 6 months to 2 years. **Results and Conclusion:** Large flaps up to 8 cm × 16 cm were raised. All but one flaps survived completely. All patients were mobilised within 48 h and five were discharged in less than a week after initial inset. The flap is reliable, easy to harvest and easy to inset on the volar aspect of fingers. The arm is positioned in a very comfortable position. The main disadvantage, however, is a conspicuous abdominal scar.

KEY WORDS

Finger defect; groin flap; hand defect; high-tension electric burn; lumbo-umbilical flap; paraumbilical perforators

INTRODUCTION

Electrical burns form 3%–5% of burn admissions and extremities are involved in more than 70% of cases.^[1,2] Young men are mostly involved while on

work at power lines.^[3,4] It leads to tissue necrosis of skin and damage along its path through the muscles, vessels, nerves and bone.^[5] Severe injury can occur, especially in limbs.^[6] Cover of vital structures (tendons, nerves, vessels

This is an open access article distributed under the terms of the Creative Commons Attribution-NonCommercial-ShareAlike 3.0 License, which allows others to remix, tweak, and build upon the work non-commercially, as long as the author is credited and the new creations are licensed under the identical terms.

For reprints contact: reprints@medknow.com

How to cite this article: Bijli AH, Bashir SA, Rasool A, Yasir M, Wani AH, Ahmad T, *et al.* Contralateral lumbo-umbilical flap: A versatile technique for volar finger coverage. Indian J Plast Surg 2017;50:201-6.

Access this article online	
Quick Response Code: 	Website: www.ijps.org
	DOI: 10.4103/ijps.IJPS_13_17

and bone) is needed to preserve or achieve a better functional result.^[7] Limb salvage and reconstruction in these cases can be extremely difficult.^[8]

The local tissue is usually not available or is insufficient in severe cases, necessitating import of tissue from a distant source.^[1] Every attempt is made to preserve and repair fingers which show promise of survival.^[7] Flap cover is urgent to save vital structures. The use of flap improves functional and esthetic results and prevents amputations.^[9,10]

Microvascular free flap reconstruction in electrical injury is quite challenging if there is accompanying vascular injury.^[1] Electrical damage to vascular endothelium manifests over a period of time.^[11] This often precludes the use of free tissue transfer, especially in fingers.

Distant pedicled flaps (groin, tensor fascia lata, superficial external pudendal artery and ipsilateral abdominal flaps) have been used in hand reconstructions^[12-15] but there is a lack of literature when it comes exclusively to volar hand and finger coverage in high-tension electrical burns. The above-mentioned flaps for volar hand and fingers are difficult to inset and keep upper limb in a very uncomfortable position.

We describe our experience with a versatile contralateral lumbo-umbilical flap with a relatively narrow pedicle base on the paraumbilical perforators. In all our cases, we used the contralateral lumbo-umbilical flap to cover the volar aspect of fingers and hand.

MATERIALS AND METHODS

The prospective study was conducted from October 2013 to April 2016 we received thirty-eight patients of high-tension electric burn. Of them, eight had predominantly deep burns on volar aspect of hand and fingers [Table 1]. In emergency care reliable vascular access was established, patients catheterised, cardiac monitoring was done and advanced trauma life support algorithm was followed in all patients. Patients with serious accompanying trauma were not included in the study group. Further evaluation and interventions were performed as required (fluid resuscitation, escharotomy/fasciotomies) on the day of admission. Patients were taken up for debridement and planned for lumbo-umbilical flap cover in the 1st week of injury

Table 1: Brief profile of cases

Sex	Age	Soft tissue defect (volar hand)	Size of the lumbo-umbilical flap
Male	24	Right middle, ring and little finger	15 cm×8 cm
Male	15	Left middle finger	12 cm×5 cm
Male	38	Right middle and ring finger	13 cm×7 cm
Male	26	Right index, middle and ring finger	16 cm×8 cm
Male	30	Right middle and ring finger	15 cm×8 cm
Male	35	Right middle and ring finger	15 cm×7 cm
Male	21	Right index and middle finger	12 cm×7 cm
Male	23	Left ring and middle finger	15 cm×8 cm

for salvage of hand and finger function. Paraumbilical perforators were confirmed by a hand held Doppler on the contralateral side to that of the involved hand. The direction of the flap was inferolateral, extending to the lumbar region up to posterior axillary line [Figure 1]. The flap base is centred on one of the perforators. The flap was raised superficial to the fascia of the external oblique muscle. At the flap base, perforators were not visualised to avoid trauma. Wide undermining and advancement of donor site edges were performed for a tension-free closure. Donor site was closed in two layers. The flaps were easily inset on the fingers, and syndactylisation was done if more than one finger was involved. The flaps were detached between 3 and 4 weeks after inset. After pedicle separation, the pedicle of the flap was carefully inset, avoiding distortion of the paraumbilical region. Primary tendon reconstruction was not performed at the time of flap inset. The patients were closely observed for first 6 weeks for any flap or donor site complications and then followed monthly to assess donor and recipient site characteristics for 6 months to 2 years.

Three index cases are discussed as under:

Case 1

A 26-year-old man with high-tension electric burn involving right upper limb as an entry point and right thigh as the exit was admitted in an emergency. The hand burn mainly involved volar aspect of fingers and palm. After resuscitation and stabilisation, the patient was taken electively to operation theatre, and debridement of devitalised tissues was done. After debridement, tendon/bone of index, middle and ring fingers got exposed. Distal vascularity was intact. The umbilical perforators

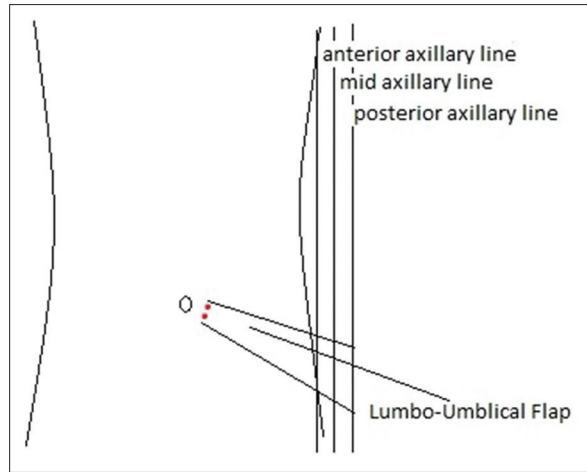


Figure 1: Lumbo-umbilical flap direction and extension limit shown up to posterior axillary line

on contralateral side of abdomen were identified, and lumbo-umbilical flap (8 cm × 16 cm) was raised. The injured fingers were syndactylised and covered with a flap. The detachment was done after 3 weeks without any delay. Final inset was given, and at this time palm of the hand was grafted. The flap survived completely. Some pus discharge from under the flap in post-operative period was managed by local care. Donor site scar was visible but acceptable to the patient [Figure 2a-e].

Case 2

A 35-year-old male with high-tension electric burn involving the right hand was admitted to the emergency department. The volar aspect of fingers had deep injuries. Debridement of eschar resulted in the exposure of tendons/bone in two fingers with intact vascularity. The lumbo-umbilical flap (7 cm × 15 cm) from contralateral side was used to cover exposed tendon/bone of volar aspect of fingers. The inset was easy, and the carrier segment was lengthy. Donor site was closed without tension. The patient was discharged after 5 days from the hospital as the patient was mobile and had very comfortable arm position. The patient was readmitted after 3 weeks and final flap inset done without any delay. The flap survived completely without any complications. Donor site scar was conspicuous but quite acceptable to the patient [Figure 3a-e].

Case 3

A 15-year-old boy was admitted to emergency service with severe high-tension burn injury involving the left hand. The volar aspect of thumb, index and middle fingers were more severely involved. After stabilisation, the patient was taken for debridement leading to tendon

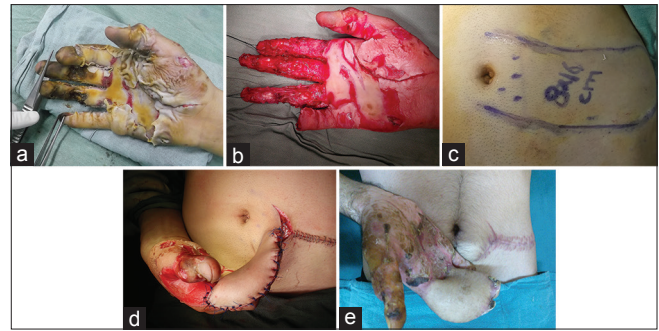


Figure 2: (a) Severe electrical burn injury right hand. (b) Tissue loss over index, middle and ring fingers with exposed tendon/bone after debridement. (c) A 8 cm × 16 cm contralateral lumbo-umbilical perforator pedicled flap was planned for cover. (d) Volar defect of fingers was covered with contralateral lumbo-umbilical perforator pedicled flap in a comfortable position. (e) Well-settled flap after 2 months with conspicuous abdominal scar

exposure on volar aspect of middle finger necessitating a flap cover. A 5 cm × 12 cm pedicled flap based on paraumbilical perforators was planned. The whole exposed volar aspect of middle finger was reconstructed with lumbo-umbilical flap of contralateral side. The thumb and index finger were skin grafted. The donor site was closed primarily. The flap was detached after 3 weeks without any delay and final inset given. The flap survived completely without any complication [Figure 4a-c].

RESULTS

Eight contralateral lumbo-umbilical flaps were used for volar finger reconstruction in eight patients. All patients were young males between 15 and 38 years of age, with a mean age of 26.5 years. Large flaps up to 8 cm × 16 cm were raised. Seven flaps survived completely, and one had necrosis of distal part requiring readvancement after debridement. All patients were mobilised within 48 h and five were discharged within a week. There was no dehiscence of inset in any case. None of the patients complained about the positioning of the arm and hand. Pedicle division was done between 3 and 4 weeks after inset. Infection occurred in three out of eight cases and was managed by local care. The donor site was primarily closed in all cases. Donor site scar was conspicuous but not bothersome.

DISCUSSION

Various pedicled abdominal flaps have been described for coverage of hand defects.^[8] These flaps may be random or axial based on the dominant paraumbilical perforators originating from the deep inferior epigastric artery. Other axial abdominal flaps such as the groin

flap and superficial inferior epigastric artery (SIEA) flap are also used. The groin flap is the workhorse for reconstruction of dorsal hand defects.^[16,17] Its inset on volar aspect, especially fingers, is quite difficult and the position of extended shoulder with supinated forearm and hand on ipsilateral side makes it very uncomfortable for the patient.^[18] The SIEA flap described by Shaw and Payne can easily cover dorsal finger defects, but its use for volar fingers is again difficult.^[19] The contralateral pedicled lumbo-umbilical flap keeps shoulder adducted; forearm flexed at 90°–110° in midprone position and hand in neutral position [Figure 5]. This position is very comfortable for the patient with no tendency on the part of patient to change it as occurs in ipsilateral flaps. Change in position does lead to complications as edema of flap and/or dehiscence. The flap has a better physiologic position, which is comfortable for the patient, and early mobilisation of upper limb joints is possible with the use of this flap. There is no restriction of hip movements leading to excellent mobility with no need to restrict the patient to the bed. There is no violation of patient privacy as the groin region is not left exposed and the patient can wear his/her routine clothes.

We could easily mobilise the patients within 48 h as there was no restriction on lower limbs. Five of our patients were discharged within a week after initial inset because of this. They were managed on outpatient basis till readmission 2–3 weeks later. Other advantage of this position is the ease of insetting flap on volar aspect of fingers as compared to ipsilateral flaps. The end result is a complete tension-free inset.

The vascular anatomy of the paraumbilical region is well known.^[20] In a recent microdissection study, El-Mrakby and Milner investigated the course of paraumbilical perforator vessels.^[21] A number of free flaps have been designed based on these paraumbilical perforator vessels.^[22] Yilmaz *et al.* first described a paraumbilical-based pedicled abdominal flap for coverage of extensive soft tissue defects of the forearm and hand using narrower pedicle and incorporating at least one perforator vessel. They reported total flap survival in all cases, pointing toward the reliability of this flap.^[15] A very large paraumbilical perforator-based flap for scrotal reconstruction has been described by Kim *et al.*^[23] Pre-expanded paraumbilical perforator flaps have also been devised as an effective option for upper extremity reconstruction.^[24] In our series, all flaps except one survived completely. The paraumbilical perforator-pedicled abdominal flap has

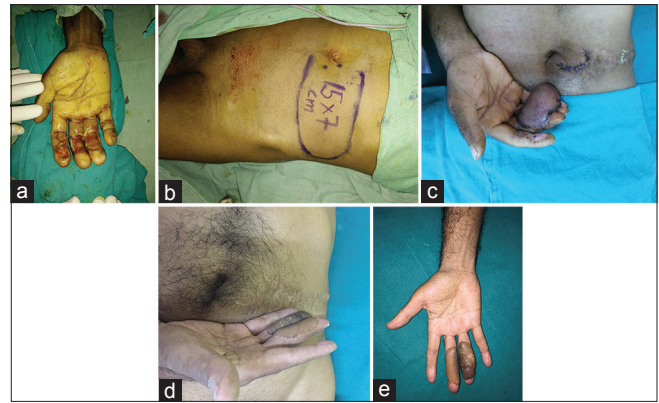

Figure 3: (a) Deep electric burn right middle and ring finger. (b) A 7 cm × 15 cm contralateral lumbo-umbilical perforator pedicled flap was planned for cover. (c) Showing post-operative picture after detachment and inset of flap. (d) Results, hand and abdominal scar after 18 months. (e) Post-flap thinning on fingers

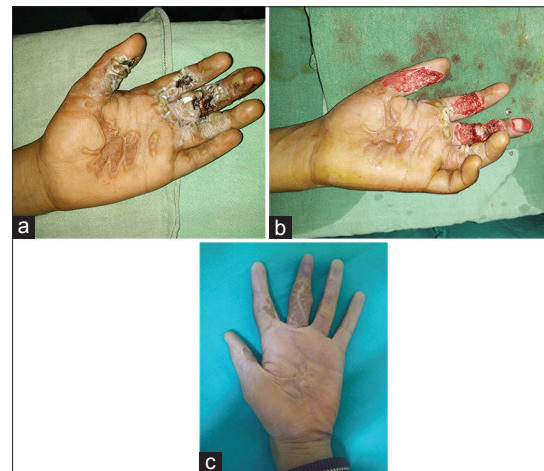

Figure 4: (a) Severe electrical burn injury left hand. (b) Showing soft tissue loss over thumb, index and middle finger with exposed tendon of middle finger. (c) The result after 12 months

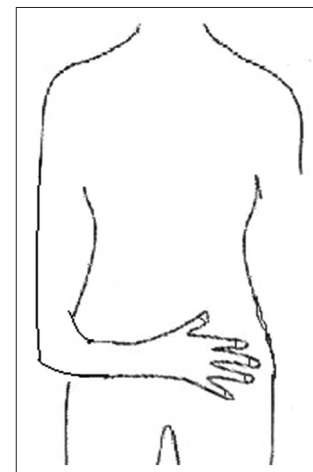


Figure 5: Comfortable position of upper limb when contralateral lumbo-umbilical abdominal flap is used

many advantages over other abdominal flaps. It is possible to design a large flap extending up to the lumbar region

without compromising the flap survival. In our series of high-tension electric burn wounds, we were successful in salvaging hand and digit function with this versatile flap in all the eight patients. The largest flap we used was 8 cm × 16 cm and the donor site was closed primarily in all cases. The case which showed distal necrosis had significant perforators in the lumbar region while elevating it. In this, possibly paraumbilical perforators were not well developed. This may be explained by the law of equilibrium that vessels obey.^[25] Thus, we infer, that if perforators in lumbar region are of significant calibre it may be prudent to delay the flap before complete elevation and transfer as is done for deltopectoral flap.^[26]

A visible scar has been mentioned as the main disadvantage of abdominal flap^[15] although most of our patients were satisfied with the procedure. A linear scar on the abdomen is easily accepted by the patients as the abdomen remains covered all the time in our society. Flap debulking was needed (maximum of two procedures) though our patients were lean and thin. All the donor sites were closed primarily.

We did not find any report in literature encouraging the use of contralateral lumbo-umbilical flaps for coverage of volar aspect of fingers in patients with high-tension electrical burns. The main purpose of our study is to emphasise that contralateral side of abdomen is a viable choice for coverage for volar fingers, and its use in volar hand defects is highly recommended.

CONCLUSION

Choosing the contralateral side gives a better physiologic position to the hand and patients can be mobilised very early and in a very comfortable manner. Large flaps can be elevated with primary donor site closure. Inset of the flap is easier for surgeon. The flap fares quite well as compared to the commonly used abdominal and groin flaps for soft tissue reconstruction of volar aspect of fingers.

Financial support and sponsorship

Nil.

Conflicts of interest

There are no conflicts of interest.

REFERENCES

- Eser C, Kesiktaş E, Gencil C, Kokacıya O, Yavuz M, Kerimov R. Algorithms of flap reconstruction in high-voltage electrical injuries: 26 years experience. *Trauma Cases Rev* 2015;1:1.
- Butler ED, Gant TD. Electrical injuries, with special reference to the upper extremities. A review of 182 cases. *Am J Surg* 1977;134:95-101.
- Luz DP, Millan LS, Alessi MS, Uguetto WF, Paggiaro A, Gomez DS, *et al.* Electrical burns: A retrospective analysis across a 5-year period. *Burns* 2009;35:1015-9.
- Khan TS, Wani AH, Darzi MA, Bijli AH. Epidemiology of burn patients in a tertiary care hospital in Kashmir: A prospective study. *Indian J Burns* 2014;22:98-103.
- Thomson CJ, Miles DA, Beveridge J, Chang PS. Treatment of electrical burns by single debridement followed by free-flap coverage: How important is timing? *Can J Plast Surg* 2004;12:35-6.
- Xu X, Zhu W, Wu Y. Experience of the treatment of severe electric burns on special parts of the body. *Ann N Y Acad Sci* 1999;888:121-30.
- Gajbhiye AS, Meshram MM, Gajjarwar RS, Kathod AP. The management of electrical burn. *Indian J Surg* 2013;75:278-83.
- Groner JP, Weeks PM. Skin and soft tissue replacement in the hand. In: Smith JW, Aston SI, editors. *Plastic Surgery*. 4th ed. Boston: Little, Brown and Company; 1991. p. 874-91.
- Stefanacci HA, Vandevender DK, Gamelli RL. The use of free tissue transfers in acute thermal and electrical extremity injuries. *J Trauma* 2003;55:707-12.
- Hallock GG. The utility of both muscle and fascia flaps in severe upper extremity trauma. *J Trauma* 2002;53:61-5.
- Wang XW, Zoh WH. Vascular injuries in electrical burns – The pathologic basis for mechanism of injury. *Burns Incl Therm Inj* 1983;9:335-8.
- Dias AD. Remember S.E.P.A. flap? *Indian J Plast Surg* 2010;43:119-20.
- Goertz O, Kapalschinski N, Daigeler A, Hirsch T, Homann HH, Steinstraesser L, *et al.* The effectiveness of pedicled groin flaps in the treatment of hand defects: Results of 49 patients. *J Hand Surg Am* 2012;37:2088-94.
- Fankhauser G, Klomp A, Smith A, Recceca A, Casey W 3rd. Use of the pedicled tensor fascia lata myocutaneous flap in the salvage of upper extremity high-voltage electrical injuries. *J Burn Care Res* 2010;31:670-3.
- Yilmaz S, Saydam M, Seven E, Ercocen AR. Paraumbilical perforator-based pedicled abdominal flap for extensive soft-tissue deficiencies of the forearm and hand. *Ann Plast Surg* 2005;54:365-8.
- Yuce S, Oksuz M, Ersoz ME, Kocak OF, Kahraman A, Isik D, *et al.* Groin flap experience in the reconstruction of soft tissue defects of the hand. *Turk J Plast Surg* 2016;24:22-6.
- Li YY, Wang JL, Lu Y, Huang J. Resurfacing deep wound of upper extremities with pedicled groin flaps. *Burns* 2000;26:283-8.
- Bajantri B, Latheef L, Sabapathy SR. Tips to orient pedicled groin flap for hand defects. *Tech Hand Up Extrem Surg* 2013;17:68-71.
- Hester TR Jr., Nahai F, Beegle PE, Bostwick J 3rd. Blood supply of the abdomen revisited, with emphasis on the superficial inferior epigastric artery. *Plast Reconstr Surg* 1984;74:657-70.
- Boyd JB, Taylor GI, Corlett R. The vascular territories of the superior epigastric and the deep inferior epigastric systems. *Plast Reconstr Surg* 1984;73:1-16.
- El-Mrakby HH, Milner RH. The suprafascial course of the direct paraumbilical perforator vessels. *Plast Reconstr Surg* 2002;109:1766-8.
- Gutwein LG, Merrell GA, Knox KR. Paraumbilical perforator flap for soft tissue reconstruction of the forearm. *J Hand Surg Am* 2015;40:586-92.

23. Kim KS, Noh BK, Kim DY, Lee SY, Cho BH. Thin paraumbilical perforator-based cutaneous island flap for scrotal resurfacing. *Plast Reconstr Surg* 2001;108:447-51.
24. Liu Y, Zang M, Zhu S, Chen B, Ding Q. Pre-expanded paraumbilical perforator flap. *Clin Plast Surg* 2017;44:99-108.
25. Salmon M. The arterial anatomy of skin flaps In: Taylor GI, Tempest M, editors. *Arteries of the Skin*. London: Churchill-Livindstone; 1988.
26. Balakrishnan C, Hackenson D, Balakrishnan A, Elliott D, Careaga D. Reconstruction of the chin using an expanded deltopectoral flap following multiple recurrences of oral cancer. *Can J Plast Surg* 2012;20:e37-9.