

## Original Article

# Proposal of a new classification scheme for periocular injuries

Devi Prasad Mohapatra, Friji Meethale Thiruvoth, Ravi Kumar Chittoria, S. Dinesh Kumar, Sudhanva Hemant Kumar, Senthil Kumar, Preethitha Babu, Elan Kumar

Department of Plastic Surgery, Jawaharlal Institute of Postgraduate Medical Education and Research, Pondicherry, India

**Address for correspondence:** Dr. Devi Prasad Mohapatra, Department of Plastic Surgery, Superspeciality Block, Jawaharlal Institute of Postgraduate Medical Education and Research, Pondicherry - 605 006, India. E-mail: devimohapatra1@gmail.com

### ABSTRACT

**Background:** Eyelids are important structures and play a role in protecting the globe from trauma, brightness, in maintaining the integrity of tear films and moving the tears towards the lacrimal drainage system and contribute to aesthetic appearance of the face. Ophthalmic trauma is an important cause of morbidity among individuals and has also been responsible for additional cost of healthcare. Periocular trauma involving eyelids and adjacent structures has been found to have increased recently probably due to increased pace of life and increased dependence on machinery. A comprehensive classification of periocular trauma would help in stratifying these injuries as well as study outcomes. **Material and Methods:** This study was carried out at our institute from June 2015 to Dec 2015. We searched multiple English language databases for existing classification systems for periocular trauma. We designed a system of classification of periocular soft tissue injuries based on clinico-anatomical presentations. This classification was applied prospectively to patients presenting with periocular soft tissue injuries to our department. **Results:** A comprehensive classification scheme was designed consisting of five types of periocular injuries. A total of 38 eyelid injuries in 34 patients were evaluated in this study. According to the System for Peri-Ocular Trauma (SPOT) classification, Type V injuries were most common. SPOT Type II injuries were more common isolated injuries among all zones. **Discussion:** Classification systems are necessary in order to provide a framework in which to scientifically study the etiology, pathogenesis, and treatment of diseases in an orderly fashion. The SPOT classification has taken into account the periocular soft tissue injuries i.e., upper eyelid, lower eyelid, medial and lateral canthus injuries., based on observed clinico-anatomical patterns of eyelid injuries. **Conclusion:** The SPOT classification seems to be a reliable system to address eyelid injuries. This classification scheme would guide the ophthalmic and facial reconstructive surgeons to provide optimal outcomes in eyelid injuries. Based on the classification scheme and review of existing literature, an algorithm is presented to facilitate repair and reconstruction.

Access this article online	
Quick Response Code:	Website: www.ijps.org
	DOI: 10.4103/ijps.IJPS_207_16

This is an open access article distributed under the terms of the Creative Commons Attribution-NonCommercial-ShareAlike 3.0 License, which allows others to remix, tweak, and build upon the work non-commercially, as long as the author is credited and the new creations are licensed under the identical terms.

**For reprints contact:** reprints@medknow.com

**How to cite this article:** Mohapatra DP, Thiruvoth FM, Chittoria RK, Kumar SD, Kumar SH, Kumar S, *et al.* Proposal of a new classification scheme for periocular injuries. Indian J Plast Surg 2017;50:21-8.

## KEY WORDS

Algorithm, eyelid injures, eyelid repair, eyelid trauma treatment, injury classification, ocular injuries, periocular trauma, System for peri-ocular trauma classification

## INTRODUCTION

Eyelids are important structures and play a role in protecting the globe from trauma, brightness, in maintaining the integrity of tear films and moving the tears towards the lacrimal drainage system and contribute to aesthetic appearance of the face. Ophthalmic trauma is an important cause of morbidity among individuals and has also been responsible for the additional cost of healthcare. Orbital and periorbital regions may be affected by many traumatic factors. International studies have estimated the lifetime prevalence of ocular injuries to be 14.4%–19.8%, whereas the incidence rate of hospitalised eye injuries was found to be 13.2/100,000.<sup>[1,2]</sup>

Classification of periocular trauma would help in stratifying these injuries; decide treatment options and study outcomes. This article presents a classification system for periocular soft tissue injuries without the involvement of globe, based on observed clinico-anatomical patterns of eyelid injuries.

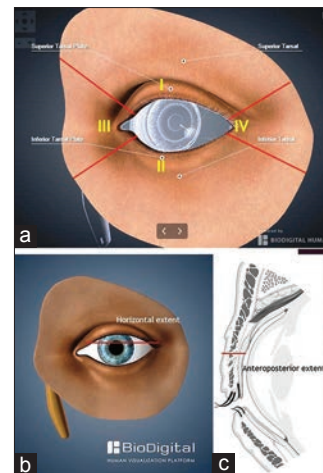
## MATERIALS AND METHODS

This study was carried out at our institute from June 2015 to December 2015. We searched the English literature for existing classification systems for periocular trauma. A search in multiple internet databases, including PubMed, Medline and Google scholar was carried out using the keywords ‘Eyelid injuries’ ‘Eyelid Trauma’ ‘Periocular Trauma’ ‘Periocular injuries’ and ‘Classification AND Eyelid Injuries’ were performed. Other medical search engines such as Trip database and ACCESSS Federated Search database were also explored using the same search terms. A review of existing literature failed to reveal a classification system that addresses the spectrum of eyelid injuries. We designed a system of classification of periocular soft tissue injuries after reviewing patient records and analysing the injuries that had presented to us previously. This system was discussed among the reconstructive surgeons of our unit, and the taxonomy was finalised. We applied the classification system prospectively to patients with periocular trauma presenting to our hospital. A final classification

system was then agreed on among the members of the reconstructive surgery unit. Based on the classification scheme and review of existing literature, an algorithm was designed to facilitate repair and reconstruction.

## Approach

To conceptualise periocular anatomy, the periorbital region has been divided into 4 zones as following: Zone I – upper eyelid; Zone II – lower eyelid; Zone III-medial canthus; and Zone IV – lateral canthus. Spinelli had originally designed this nomenclature to divide the periorbital region with an aim to approach reconstruction options for post-surgical eyelid defects.<sup>[3]</sup> We adopted this nomenclature in our classification scheme to address the anatomical component. The eyelid zones were more rigidly demarcated in our system to reduce inter-observer discrepancy. We defined Zone I as upper eyelid in a region extending from a point 1 mm lateral to the lacrimal punctum to 3 mm medial to lateral ocular commissure on the palpebral margin. Similarly, Zone II represented the lower eyelid in a region at a point 1 mm lateral to the lacrimal punctum to 3 mm medial to lateral ocular commissure on the palpebral margin. An imaginary perpendicular line dropped from the palpebral margin to orbital rim at each of these points helped in demarcating the zones more clearly [Figure 1a]. Type I injuries were the one involving Zone I, Type II injuries were the one involving Zone II, Type III injuries involved the Zone III and Type IV



**Figure 1:** Depiction of the zones of periorbital region (a) horizontal eyelid dimension (b) and anteroposterior eyelid anatomy (c)

injuries involved the Zone IV. The eyelid injuries were addressed in anteroposterior and horizontal dimensions [Figure 1b and c]. Antero-posterior tissue involvement was divided into superficial (epidermo-dermal injury), partial thickness (Subcutaneous injury extending up to but not involving palpebral conjunctiva) and full thickness losses (involvement of palpebral conjunctiva) for injuries of Type I and Type II. These Type I and Type II full thickness injuries of the upper and lower eyelids, respectively, were further defined according to the horizontal extent of eyelid tissue lost ( $\frac{1}{4}$ ,  $\frac{1}{2}$  and more than  $\frac{1}{2}$  loss of eyelid tissue). Antero-posterior tissue involvement for Type III and Type IV (Medial and lateral canthus, respectively) injuries were again subdivided into superficial (epidermo-dermal injury), partial thickness (Subcutaneous injury extending up to but not involving periosteum) and full thickness losses (involvement of periosteum and bone in addition to above) Table 1.

If the injuries involved more than one zone, it was classified as a Type V injury with a subclassification nomenclature added to depict the individual anatomical zones involved. To indicate side of involvement, a 'Rt' or 'Lt' was included in the nomenclature representing right or left, respectively. Lacrimal system involvement in Type III injuries was demonstrated with an 'L'. We subdivided the lacrimal apparatus injury into simple and complex types. The former, involving only the lacrimal canaliculi, and the latter involving, either, the common canaliculus, nasolacrimal sac or nasolacrimal duct. Simple lacrimal injuries were monocanicular or bicanicular. We excluded globe injuries and skeletal injuries from our classification system to maintain lucidity in the system. We named this scheme as the System for Peri-Ocular Trauma (SPOT) classification.

**Observations**

The classification scheme was applied prospectively to patients of acute eyelid injuries attending the emergency

**Table 1: System for peri-ocular trauma classification for periorcular injuries**

Type	Zone	Anatomical region	Injury
I	I	Upper eyelid	A=Superficial B=Partial thickness 1=Without tissue loss 2=with tissue loss C=Full thickness 1=< ¼ tissue loss 2=1/4-1/2 tissue loss (Subtotal) 3= > 1/2 (Near total/Total loss of eyelid )
II	II	Lower eyelid	A=Superficial B=Partial thickness 1=Without tissue loss 2=with tissue loss C=Full thickness 1=< ¼ tissue loss 2=1/4-1/2 (Subtotal) 3=>1/2 (Near total/Total loss of eyelid )
III	III	Medial canthus	A=Superficial B=Partial thickness ( periosteum intact) 1=Without tissue loss 2=with tissue loss C=Full thickness ( periosteum breached) 1=Without tissue loss 2=with tissue loss (Presence of injuries to the Lacrimal canalicular system is represented by an 'L' )
IV	IV	Lateral canthus	A=Superficial B=Partial thickness ( periosteum intact) 1=Without tissue loss 2=with tissue loss C=Full thickness ( periosteum breached ) 1=Without tissue loss 2=with tissue loss
V	Any Combination of above involving more than 1 zone		

services at our hospital. An attempt also was made to classify patients with old eyelid injuries attending the out-patient services, using the same scheme.

#### Clinical scenario 1

A 40-year-old male patient [Figure 2] presents with an upper eyelid injury extending onto the medial eyebrow region. Although the palpebral margins were lacerated and the tissues twisted on themselves, there was no evidence of tissue loss when repositioned. The canthal regions were unaffected. Based on our classification scheme, we defined it as a 'Lt Type I C<sup>1</sup>' injury. An anatomical repair was carried out, and the eyelid function was restored without any limitations.

#### Clinical scenario 2

A 33-year-old male patient [Figure 3] sustained injury to the left side of the face in a road traffic accident. He presented with a lower eyelid laceration in addition to other injuries. The eyelid laceration involved the lateral third of the eyelid, was full thickness and associated without tissue loss. It was classified as 'Rt Type II C<sup>1</sup>' injury.

#### Clinical scenario 3

A 55-year-old male [Figure 4] patient had a fall from his motorcycle and sustained a right lower eyelid injury.

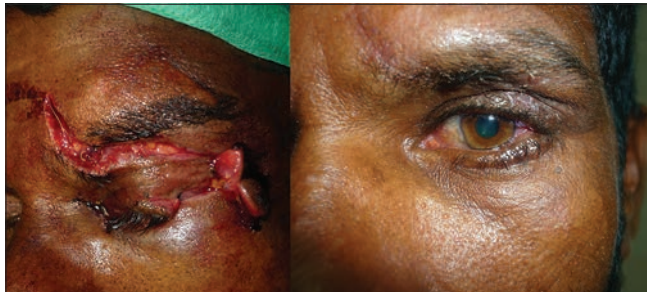

Figure 2: Type I injury

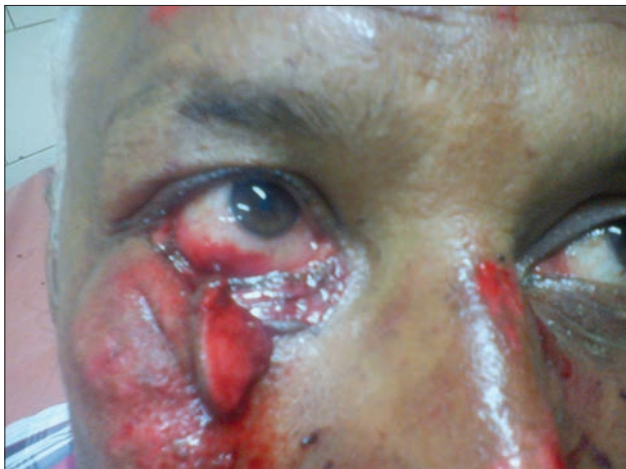

Figure 4: Type II injury with tissue loss

Clinical examination revealed a full thickness laceration involving lateral half of the lower eyelid without any primary tissue loss. The canthal areas were intact. This injury was initially classified as 'Rt Type II C<sup>1</sup>.' Primary repositioning of tissues was initially carried out and sutured. However, the lateral portion necrosed leading to loss of nearly half of the lower eyelid. A rhomboid pattern flap was performed at a later date. We revised this injury classification as 'Rt Type II C<sup>2</sup>.'

#### Clinical scenario 4

A 48-year-old female [Figure 5] patient was injured while tying her bull at a rural setup. She presented to our unit with an avulsion laceration injury involving the medial and lateral canthus and the palpebral conjunctiva of the lower eyelid. The external surface of the lower eyelid was largely unaffected except for few contusions. Although the medial and lateral canthal tendons were injured, the underlying periosteum was not breached. The inferior lacrimal canaliculus was also injured. After a thorough cleaning, a meticulous anatomical repair was carried out. We classified this injury as an 'Rt Type V (II B<sup>1</sup> + IIIB<sup>1</sup> + IVB<sup>1</sup>) L' injury.

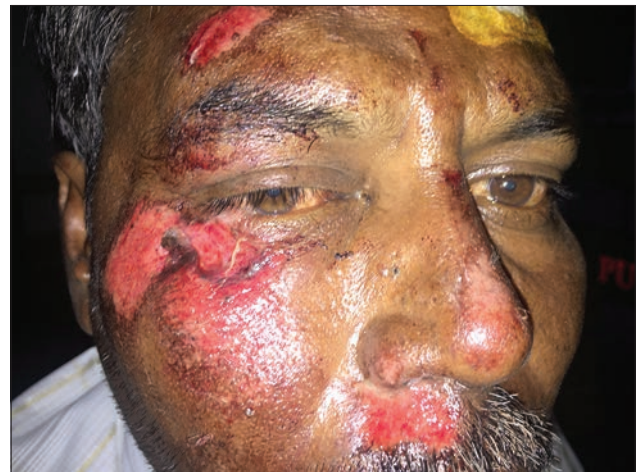

Figure 3: Type II injury without tissue loss

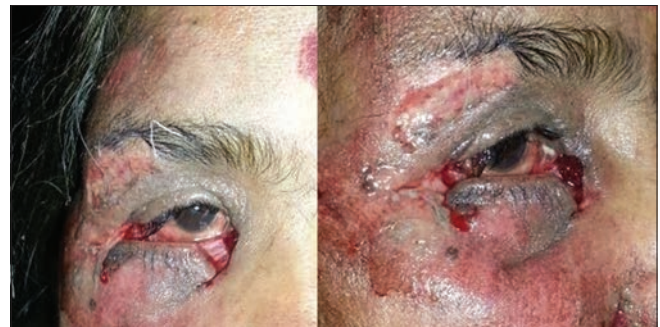

Figure 5: Type V injury without tissue loss

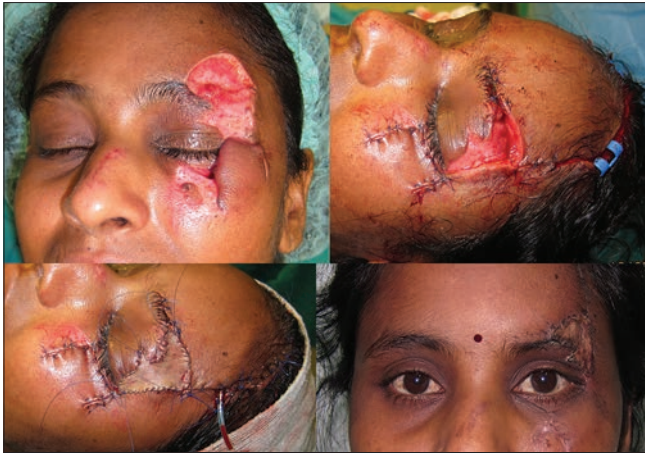

Figure 6: Type V injury with tissue loss

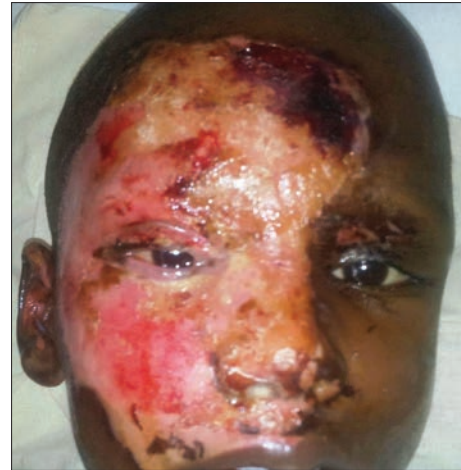

Figure 7: Type V injury seen in thermal burns

### Clinical scenario 5

A 28-year-old female [Figure 6] patient presented with injuries to left periocular region involving upper eyelid lateral aspect extending to lateral forehead with tissue loss, lateral 2/3 of lower eyelid, avulsion involving lateral canthus region without tissue loss. After a thorough cleaning, primary repair of lateral canthal region and lower eyelid was performed. The forehead and upper eyelid soft tissue defect were covered with the advancement of the lateral forehead. The upper eyelid defect was resurfaced with a full thickness skin graft. This was classified as a 'Lt Type V (IB<sup>2</sup> + IIC<sup>1</sup> + IVB<sup>1</sup>)' injury.

### Clinical scenario 6

A 12-year-old child [Figure 7] presents with second degree superficial scald burns on the right side of the face and involving the adjacent periocular region. The globe was uninjured. We classified it as an 'Rt Type V (IA + II A + III A + IV A)' injury. The child was admitted and treated conservatively with collagen dressings, antibiotics and analgesics.

## RESULTS

A total of 38 eyelid injuries in 34 patients were evaluated in this study. The most common mechanism of injury in our series was road traffic accident, followed by thermal burns. Uncommon causes included bull horn injury and blouse hook injuries. The age range varied from 6 months to 52 years. Among post-traumatic injuries, males were most commonly injured and majority injuries were of Type V (69%). Isolated Type III and Type IV injuries were not seen in our series, whereas isolated Type II injuries were more common among all periocular zones. Females

were more commonly affected in cases of thermal injuries affecting the periocular region. These were all SPOT Type V injuries involving all 4 Zones. We did not to see any chemical injuries in the present series.

## DISCUSSION

The increased mechanisation in domestic and industrial settings as well as exposure to high-velocity traffic has resulted in increased incidences of trauma, including facio-ocular injuries. Eyelid injuries vary in severity and extent and present in a variable fashion.<sup>[1]</sup>

Among all sites of ophthalmic injury, eyelid laceration seems to be neglected in terms of sufficient epidemiological investigations, whereas studies have shown that in ophthalmic trauma, injuries to the eyelids comprise up to 13% of anatomical region involved.<sup>[1]</sup> Trauma to the eyelids occurs in a variety of ways and in complex combinations. Moving objects, Workplace injuries, motor vehicle accidents, falling, thermal injuries and assault are the main causes of lid lacerations in our population. Among all cases of eyelid trauma, the lid margin is affected in 24%, the lacrimal drainage system in 16% of all injuries.<sup>[1]</sup> Data show a high association (44%) of eyelid injuries with trauma to the eyeball.<sup>[2]</sup> Thermal and chemical burns lead to injuries in the periocular region. While the globe is protected in the majority of cases due to the reflex closure of eyelids, they may be involved in more severe burns.<sup>[4,5]</sup>

Classification systems are necessary to provide a framework in which to scientifically study the aetiology, pathogenesis and treatment of diseases in an orderly fashion. Systems of injury classifications enable a systematic description

of injuries.<sup>[6]</sup> Without a standardised terminology of eye injury types, it is impossible to design eye injury registries or organise research in the field of ocular trauma, and the communication between reconstructive surgeons remains ambiguous. A proper classification system also helps to facilitate the comparison of health-related data within and across populations and over time as well as in the compilation of nationally and internationally homogenous data.<sup>[6]</sup> With a thorough understanding of the causes and types of eyelid lacerations, it is possible to develop a better preventive strategy and hence improve the public health policy in this respect. In addition, a systematic approach to these complex injuries would aid the reconstruction specialist to restore the anatomy of the region.

The International Classification of Diseases (ICD-10) has classified the eyelid injuries and injury to the periocular region as superficial and open injuries (S 00.1, S 00.2, S01.1).<sup>[7]</sup> Since no other suitable systems were available, we designed this present system. The clinico-anatomic basis of the classification has been the anatomical zones of the periocular region as defined by Spinelli and Jelks.<sup>[3]</sup> A taxonomy review and validation of the system was performed among the reconstructive surgeons in our unit. The classification system was then applied prospectively to patients with eyelid injuries presenting to our trauma unit over 6 months period to assess its clinical usefulness. Some adjustments in the classification terminology were made after discussion among the reconstructive surgeons.

The SPOT classification has taken into account only the periocular soft tissue injuries i.e., upper eyelid, lower eyelid, medial and lateral canthus injuries. Different well-established classification systems are available for globe injuries and orbital skeletal injuries.<sup>[8]</sup> None of these classification schemes have taken into account the varied spectrum of periocular injuries. The SPOT classification is designed to work in conjunction with these pre-existing classifications. We purposefully excluded globe and skeletal injuries from this classification to maintain its simplicity.

Due to the functional and cosmetic importance of the eyelid, repair and reconstruction becomes paramount. Numerous approaches have been made towards repair and reconstruction of eyelids.<sup>[9-11]</sup> Repair and reconstruction of injuries vary with severity and extent.<sup>[12,13]</sup> Approach

to these injuries should be performed in an orderly fashion. An algorithm for repair of injuries would help reconstructive surgeons to approach the defects systematically. With the availability of numerous reconstruction strategies, it becomes necessary to help the ophthalmic reconstructive surgeon in decision making to provide a suitable treatment for a given defect. To address this requirement, we designed an algorithm [Figure 8] for eyelid reconstruction in trauma based on the SPOT classification for eyelid injuries. We included a minor anatomical sub-classification of lacrimal system injury in the SPOT system. An aetiological classification such injury has been proposed previously.<sup>[14]</sup> Since this algorithm was meant to address eyelid and periocular soft tissue injuries, while designing it, the specific management of adjacent skeletal trauma has not been mentioned. However, the reconstructive surgeon needs to consider the presence of skeletal injuries and provide appropriate skeletal stabilisation in the form of open reduction and internal fixation where indicated, irrespective of the injury type.

Prognosis of periocular soft tissue injuries takes into consideration the aesthetic appearance in addition to eyelid function. Prognosis and outcomes of these injuries depend on a number of variables such as the severity of trauma, the extent of injuries, the involvement of adjacent skeletal system and globe, time of presentation following trauma, the presence of foreign bodies and even age of the patient. The SPOT classification aids in prognostication. Prognosis in Type IA injury would be better than that in Type IB<sup>2</sup> injury. Similarly, a Type II C<sup>1</sup> injury would have a better prognosis in terms of function and appearance over Type II C<sup>2</sup> injuries. The SPOT classification helps the reconstructive surgeon to explain the trauma severity to the patient, possible therapeutic options, possible outcomes of treatment and expected time for recovery.

We have not been able to fully assess the utility of the classification system for old injuries of the eyelid. We feel that it may not be useful in the post-burn contractures of the eyelid as the extent of primary tissue involvement is not readily visible. The aetiologic component of injury has not been addressed in this classification. This is also one of the limitations of our SPOT classification.

We have noticed several benefits of the SPOT classification proposed by us. First, it brings in uniformity in the

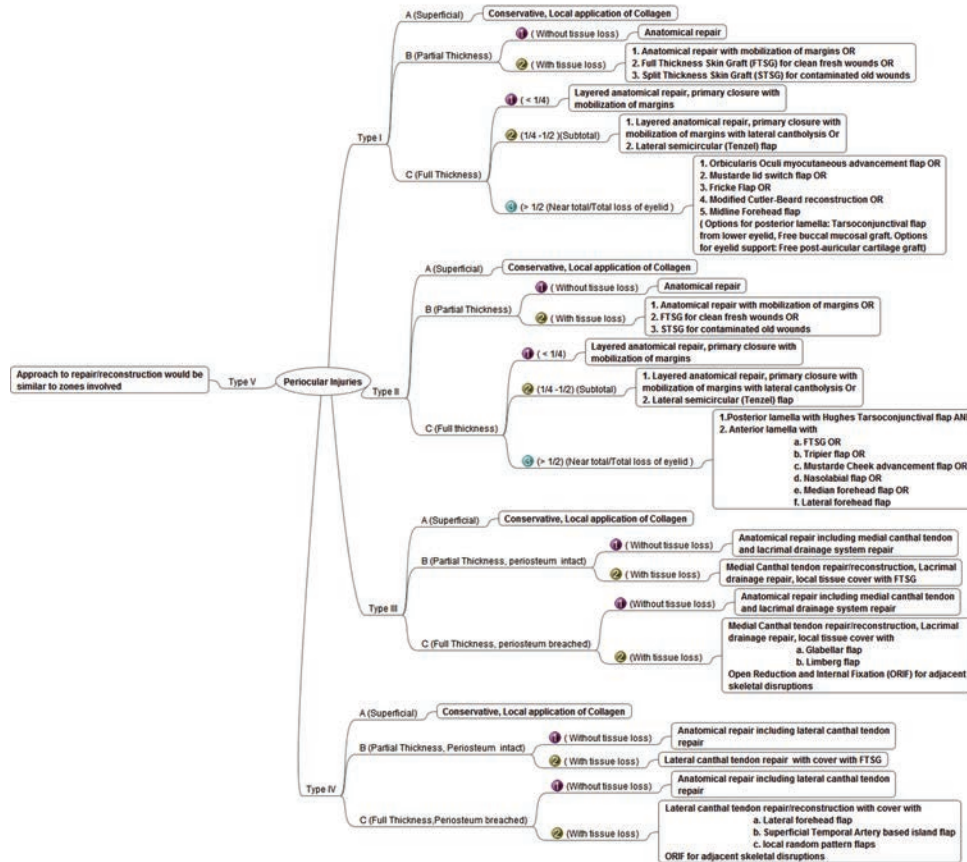

Figure 8: Algorithm for approach to periocular injuries

description of the eyelid injuries among the clinical team members and in planning a treatment strategy. For example, when referring a patient to a specialised centre, a trauma physician can inform the reconstructive surgeon that they are referring a patient with Right Type II C<sup>2</sup> injury which translates into a full thickness lower eyelid injury on the right side with the loss of nearly half of the lower eyelid. In addition to providing a compact description of the injury, this would also help the reconstructive surgeon to plan their treatment and resources appropriately. There are, however, situations, where the traumatised periocular tissues get devitalised over a period following trauma. Hence, the initial injury classification made at presentation may need to be revised, as we have described in clinical scenario 3.

The second advantage of the SPOT classification is to objectively define the injury, predict severity and outcomes of treatment. A compact description aids in documentation. Documenting the diagnosis of a periocular injury as a 'Rt Type III C<sup>3</sup> L' seems more objective and appropriate than just 'medial canthus injury right side' or 'medial canthus

injury with exposed bone and lacrimal canaliculi injury on right side'. The ability to stratify injuries according to severity of injury is helpful in judicious distribution of surgical resources among the injured. In addition, the SPOT classification helped to design an algorithm to address reconstruction of eyelid injuries.

Considering the above mentioned merits, the SPOT classification would have wide applicability not only among plastic surgeons, but also ophthalmologists, trauma care physicians and emergency medical officers.

## CONCLUSION

The SPOT Classification seems to be a reliable system to address eyelid injuries. While further multicentric studies are required to assess the usefulness and promote widespread adoption of the system, the simplicity and comprehensiveness make this system particularly appealing. We believe that this classification scheme would guide the ophthalmic and facial reconstructive surgeons to provide optimal outcomes in such injuries.

### Declaration of patient consent

The authors certify that they have obtained all appropriate patient consent forms. In the form the patient(s) has/have given his/her/their consent for his/her/their images and other clinical information to be reported in the journal. The patients understand that their names and initials will not be published and due efforts will be made to conceal their identity, but anonymity cannot be guaranteed.

### Acknowledgement

We are grateful to Biodigital Human ([www.biodigital.com](http://www.biodigital.com)) for granting us permission to use their images for this manuscript.

### Financial support and sponsorship

Nil.

### Conflicts of interest

There are no conflicts of interest.

### REFERENCES

1. Woo JH, Sundar G. Eye injuries in Singapore – Don't risk it. Do more. A prospective study. *Ann Acad Med Singapore* 2006;35:706-18.
2. Kretlow JD, McKnight AJ, Izaddoost SA. Facial soft tissue trauma. *Semin Plast Surg* 2010;24:348-56.
3. Spinelli HM, Jelks GW. Periocular reconstruction: A systematic approach. *Plast Reconstr Surg* 1993;91:1017-24.
4. Sarabahi S, Kanchana K. Management of ocular and periocular burns. *Indian J Burns* 2014;22:22-32.
5. Pargament JM, Armenia J, Nerad JA. Physical and chemical injuries to eyes and eyelids. *Clin Dermatol* 2015;33:234-7.
6. Audigé L, Bhandari M, Hanson B, Kellam J. A concept for the validation of fracture classifications. *J Orthop Trauma* 2005;19:401-6.
7. World Health Organization. International Statistical Classification of Diseases and Related Health Problems 10<sup>th</sup> Revision (ICD-10)-WHO Version for 2016. Available from: <http://www.who.int/classifications/icd10/browse/2016/en#/S00.2>. [Last accessed on 2016 Dec 12].
8. Manolidis S, Weeks BH, Kirby M, Scarlett M, Hollier L. Classification and surgical management of orbital fractures: Experience with 111 orbital reconstructions. *J Craniofac Surg* 2002;13:726-37.
9. Subramanian N. Reconstructions of eyelid defects. *Indian J Plast Surg* 2011;44:5-13.
10. White WL, Hollsten DA. Burns of the ocular adnexa. *Curr Opin Ophthalmol* 1994;5:74-7.
11. Gilbert L, Pogorzalek N, Jounda G, Barreau E. Traumatic peri-ocular injuries: Closing wounds using 2-octyl-cyanoacrylate medical glue. *J Fr Ophtalmol* 2009;32:341-7.
12. Tintle SM, Levin LS. The reconstructive microsurgery ladder in orthopaedics. *Injury* 2013;44:376-85.
13. Friji MT, Mohapatra D, Kumar DS. The reconstructive microsurgery ladder in orthopedics. *Injury* 2014;45:1020.
14. Sundar G. Lacrimal trauma and its management. In: Javed Ali M, editor. *Principles and Practice of Lacrimal Surgery*. 1<sup>st</sup> ed. New Delhi: Springer India; 2015. p. 159-70.