

Letters to Editor

Shaping the nasal tip: A new approach to transdomal suturing

Sir,

Shaping the nasal tip is one of most challenging parts of rhinoplasty. Evolving experience has shifted nasal tip surgery from alar cartilage-cutting techniques to alar cartilage-sparing surgery.^[1] Hence, intervening in the nasal tip increasingly relies on cartilage relocation and re-orientation, rather than reduction and cutting.^[2]

In this context, transdomal sutures (TDS) are conventionally used to narrow the distance between the domes and increase tip projection. TDS form the tip double break and provide a better tip-columella ratio. Nevertheless, TDS placement is not without problems, especially in cases of very rigid domal cartilages. Personal experience suggests that excessive bulking at the tip area and a round shape of the tip may be the final outcome in such cases. We propose a modified TDS/intercrural suture, aiming to give a more natural shape to the tip, which is easily placed and is highly effective.

The new approach to transdomal suturing includes open rhinoplasty and cephalic trimming. Suturing starts with a right cephalic domal bite in an anticlockwise fashion, continues by stitching the collumelar segment of the medial crus^[3] from the right, then stitches the collumelar segment of the medial crus from the left and ends up with a cephalic domal bite to the left, again in an anticlockwise fashion [Figure 1a and b]. The open approach facilitates symmetric suture placement. The use of single stitch and not two separate ones, while freeing both domes to the same height before suturing, greatly reduces the probability of an undesired outcome. Suturing is performed using a 4.0 polydioxanone suture stitch.

The advantages of the proposed new approach to transdomal suturing become clearer, if one takes into account the problems in shaping the nasal tip, which may be encountered in every day practice.^[4] These problems become especially obvious in case a surgeon decides to change the tip definition, in combination with an overlay technique and cartilage division at the tip area, when lower lateral crus struts are used, and

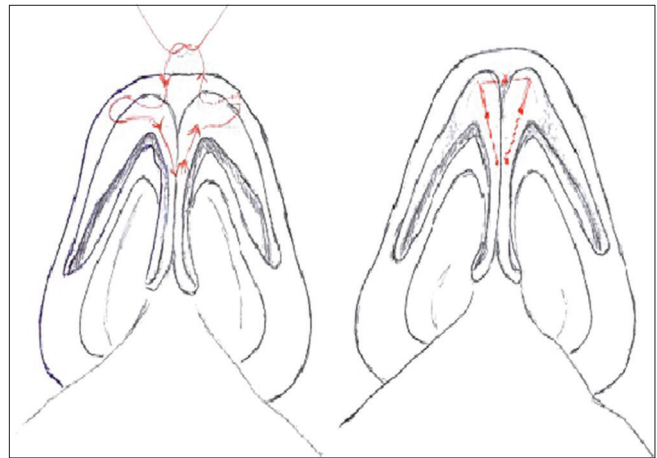


Figure 1: Modified transdomal/intercrural suture placement

in revision cases, where the domal area is damaged and the domal cartilage too thin. Placing the stitch down to the collumelar segment of the medial crus, in the aforementioned cases, is more easily performed compared to the traditional mattress TDS technique, as this area is relatively untouched, and the surgeon may avoid crowding the domal area with knots, which may also add to its friability.

In addition, the modified TDS/intercrural suture avoids parallel pinching of the domes, maintains their natural divergence and may also be helpful regarding tip grafting. Cartilage asymmetries and/or small nasal tips can also be relatively easily hidden. No complications from this type of suturing have been encountered so far, and the postoperative results have remained stable at the 2-year follow-up [Figure 2a and b].

Declaration of patient consent

The authors certify that they have obtained all appropriate patient consent forms. In the form the patient(s) has/have given his/her/their consent for his/her/their images and other clinical information to be reported in the journal. The patients understand that their names and initials will not be published and due efforts will be made to conceal their identity, but anonymity cannot be guaranteed.

Financial support and sponsorship

Nil.

Conflicts of interest

There are no conflicts of interest.

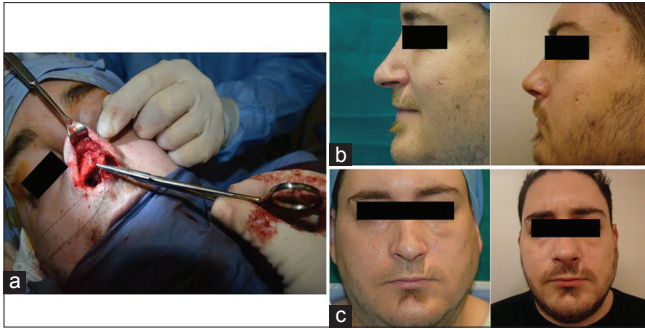


Figure 2: (a-c) Operative technique, pre- and post-operative results following the modified transdomal/intercrural suture placement

**Argyro Kypraiou, Petros V. Vlastarakos¹,
Stefanos Papailiadis**

Departments of Functional and Reconstructive Rhinoplasty
and 'ENT, Mitera Infirmary, Athens, Greece

Address for correspondence:

Dr. Petros V. Vlastarakos,
85 Ethn, Antistaseos Street, Agios Dimitrios, Athens, Greece.
E-mail: pevlast@hotmail.com

REFERENCES

1. Behmand RA, Ghavami A, Guyuron B. Nasal tip sutures part I:

- The evolution. *Plast Reconstr Surg* 2003;112:1125-9.
2. Vuyk HD. Suture tip plasty. *Rhinology* 1995;33:30-8.
3. Daniel RK. Rhinoplasty: Creating an aesthetic tip. A preliminary report. *Plast Reconstr Surg* 1987;80:775-83.
4. Carvalho TB, Thomazi E, Leutz RP, Souza RP, Molina FD, Piatto VB, *et al.* Gradual approach to refinement of the nasal tip: Surgical results. *Braz J Otorhinolaryngol* 2015;81:31-6.

This is an open access journal, and articles are distributed under the terms of the Creative Commons Attribution-NonCommercial-ShareAlike 4.0 License, which allows others to remix, tweak, and build upon the work non-commercially, as long as appropriate credit is given and the new creations are licensed under the identical terms.

| Access this article online | |
|--|----------------------------------|
| Quick Response Code:  | Website: www.ijps.org |
| | DOI: 10.4103/ijps.IJPS_218_17 |

How to cite this article: Kypraiou A, Vlastarakos PV, Papailiadis S. Shaping the nasal tip: A new approach to transdomal suturing. *Indian J Plast Surg* 2018;51:247-8.

© 2018 Indian Journal of Plastic Surgery | Published by Wolters Kluwer - Medknow