

## Original Article

# Management of vascular anomalies: Review of institutional management algorithm

Lalit K. Makhija, Sameek Bhattacharya

Department of Plastic Surgery, PGIMER, Dr. RML Hospital, New Delhi, India

**Address for correspondence:** Dr. Sameek Bhattacharya, Department of Plastic Surgery, PGIMER, Dr. RML Hospital, New Delhi, India.  
E-mail: sameekb@gmail.com

### ABSTRACT

**Introduction:** Vascular anomalies are congenital lesions broadly categorised into vascular tumour (haemangiomas) and vascular dysmorphogenesis (vascular malformation). The management of these difficult problems has lately been simplified by the biological classification and multidisciplinary approach. To standardise the treatment protocol, an algorithm has been devised. The study aims to validate the algorithm in terms of its utility and presents our experience in managing vascular anomalies. **Materials and Methods:** The biological classification of Mulliken and Glowacki was followed. A detailed algorithm for management of vascular anomalies has been devised in the department. The protocol is being practiced by us since the past two decades. The data regarding the types of lesions and treatment modality used were maintained. **Results and Conclusion:** This study was conducted from 2002 to 2012. A total of 784 cases of vascular anomalies were included in the study of which 196 were haemangiomas and 588 were vascular malformations. The algorithmic approach has brought an element of much-needed objectivity in the management of vascular anomalies. This has helped us to define the management of particular lesion considering its pathology, extent and aesthetic and functional consequences of ablation to a certain extent.

### KEY WORDS

Algorithm; management; vascular malformation

### INTRODUCTION

Vascular anomalies are congenital lesions of vascular origin, which have been both confusing and challenging to manage. Most of the confusions pertaining to them have largely been put to rest with the advent of biological classification.<sup>[1]</sup> The classification based on the correlation of physical features, natural

history and histology categorises vascular anomalies into vascular tumours featuring hyperplasia and vascular malformation which results from localised maldevelopment of vascular morphogenesis. This taxonomy has removed the confusing terminologies, which led to improper diagnosis and treatment earlier. However, the challenge involved in the treatment

This is an open access article distributed under the terms of the Creative Commons Attribution-NonCommercial-ShareAlike 3.0 License, which allows others to remix, tweak, and build upon the work non-commercially, as long as the author is credited and the new creations are licensed under the identical terms.

**For reprints contact:** reprints@medknow.com

**How to cite this article:** Makhija LK, Bhattacharya S. Management of vascular anomalies: Review of institutional management algorithm. Indian J Plast Surg 2017;50:193-200.

Access this article online	
Quick Response Code:	Website: www.ijps.org
	DOI: 10.4103/ijps.IJPS_245_15

still remains. Although multidisciplinary approach in management is largely established, we still find patients shuttling between specialities as ‘nomads’. Most of the times, these patients are managed by reconstructive surgeons who play a central role in their management, but still there is a lack of a standard and universally acceptable management protocol for these cases. We have been following an algorithmic approach in the management of vascular anomalies. In this study, we present our data of vascular anomaly patients of over a decade.

**MATERIALS AND METHODS**

This study includes a retrospective review of patients of vascular anomalies treated at our department from 2002 to 2012. The biological classification of Mulliken and Glowacki was used to categorise patients.<sup>[1]</sup> The imaging modalities used were plain radiographs, Doppler study, magnetic resonance (MR) imaging with MR angiography and contrast computed tomography for the evaluation of patients. After diagnosis and classification, the further course of management was on the basis of the protocol [Figure 1a and b].

In cases of haemangiomas, by default, we exercised masterly inaction keeping the patient under regular observation during the proliferative phase. The indications of intervention during this phase were rapidly growing hemangiomas which ulcerate or bleed, encroach upon vital areas like eyes, nose & mouth, compromise oral intake or causing airway obstruction.

- Visual obstruction
- High-output cardiac failure.

If any of the above-mentioned indications was there at presentation or during any time in the proliferative phase, pharmacotherapy was prescribed. The most common indications were rapid growth and ulcerations. From 2002 to 2008, the pharmacological intervention was either systemic prednisolone or intralesional triamcinolone. Intralesional triamcinolone (25 mg/mL) was administered for small localised haemangiomas at a dosage of 3–5 mg/kg every 4–6 weeks. Systemic prednisolone was prescribed for large lesions at a dosage of 2–3 mg/kg/day till the child was 10–12 months of age. The dosage was tailored as the child gained weight. The dosage was tapered slowly every 2–4 weeks before discontinuing prednisolone. In cases where there was rebound growth after discontinuation of corticosteroid, another course of 4–6 weeks was instituted. Since 2009, oral propranolol was the mainstay pharmacotherapeutic agent. It was decided to switch over to propranolol as there was faster response and fewer side effects. It was prescribed at a dose of 2–3 mg/kg/day in three divided dosages. The dose was gradually tapered every 4 weeks and discontinued by about 10–12 weeks of age. In case a rebound growth was noticed after stoppage of propranolol, a 4-week course was repeated. Cases which presented with post-involution residual lesion were addressed surgically.

The protocol for vascular malformation was separate for low- and high-flow varieties. Localised venous, lymphatic and lymphatico-venous malformations (LVMs) in areas where there were no aesthetic and functional consideration were excised. Extensive lesions where significant post-excision functional and/or aesthetic deficit were foreseen, excision was not done initially to

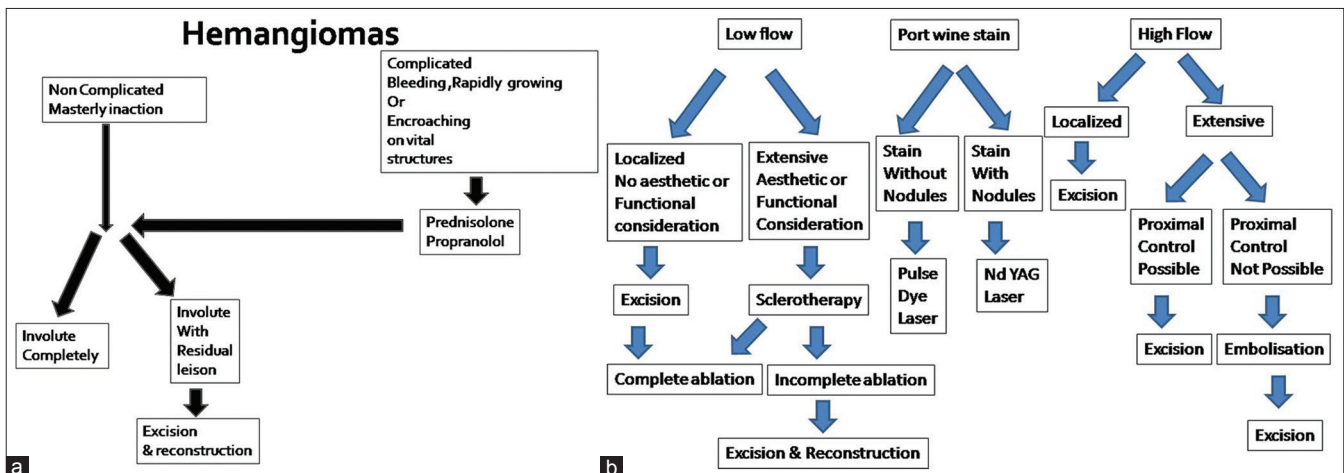


Figure 1: (a) Algorithm for vascular tumours and haemangiomas. (b) Algorithm for vascular malformation

avoid post-excision functional loss and disfigurement, for example, in face and hand. Instead sclerotherapy was done with Sodium tetradecyl sulphate (0.5-2 mL of 1% solution intra-lesionally) or Bleomycin (1 mg/ kg body weight, intralesionally) in venous malformation (VM) and lymphatic malformation (LM), respectively. The number of sclerotherapy sessions was guided by the size of the lesion and the response to the treatment. The endpoint of the therapy was either complete resolution of the lesion or no further reduction in size. In latter cases, the residual malformation was surgically excised. Capillary malformations (CMs) were categorised into flat and nodular lesions. In former cases, pulse dye laser therapy was recommended, and in the latter cases, surgical excision was done in localised and excisable lesions. Camouflage was advised in the rest. Small high-flow vascular malformations were excised after encircling the lesion with haemostatic sutures. Larger lesions were also excised where proximal control was possible with tourniquet. In cases where proximal control was not possible, like in head and neck malformations with intra-abdominal components, preliminary embolisation was done followed by excision or debulking 24 h later.

The data of the patients were maintained in terms of diagnosis, age, sex, site, tissue involved, treatment given and final outcome. The data were compiled and analysed in Microsoft Excel®.

## RESULTS

A total of 784 cases of vascular anomalies were included in the study who presented to this hospital from 2002 to 2012. Out of these, 196 were vascular tumours and 588 were vascular malformations. In the vascular tumour category, 192 were haemangiomas and 4 were haemangioendotheliomas. The distribution of the

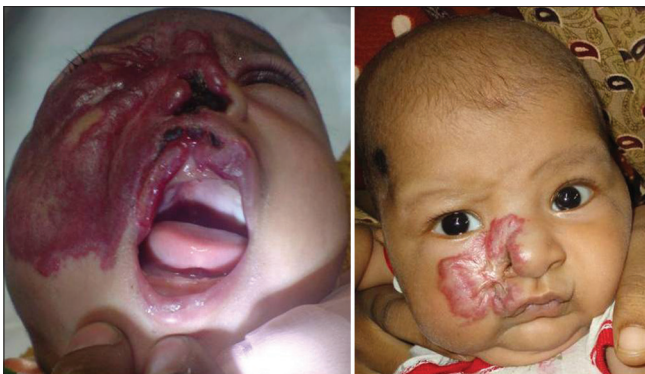

Figure 2: Haemangioma of the face, treated by propranolol

haemangioma patients in terms of gender and site is shown in Table 1. The nature of intervention in relation to haemangioma is shown in Table 2. In majority of the patients (110/196), masterly inaction was followed so that the lesions could involute spontaneously by an age ranging from 5 to 7 years. Thirty-seven cases were operated for residual lesions after involution, out of which 22 were in face and neck area, 9 in extremities and 6 in trunk. Eight patients with facial lesions needed tissue expansion. Rest of the residual lesions were excised and primarily closed. Forty patients needed pharmacological intervention during proliferative phase. The indications for pharmacotherapy are shown in Table 3. The most common indication being rapidly growing tumour leading to ulceration and repeated bleeding. Nineteen patients required systemic prednisolone. Intralesional triamcinolone was given to nine patients. Twelve patients

Table 1: Distribution of hemangiomas according to site

Distribution	Hemagioma		Hemagioendothelioma
	Congenital	Infantile	
	5	187	4
Location	Male	Female	Total
Cervicofacial	27	91	118
Trunk	12	24	36
Extremities	23	19	42
	62	134	196

Table 2: Interventions in hemangioma patients

Interventions	Number
Pharmacotherapy	40
Systemic Prednisolone	19
Intralesional Triamcinalone	9
Propranolol	12
Surgical	9
Intervention for residual lesion	37
None	110

Table 3: Pharmacotherapy in hemangioma patients

Indications for Pharmacotherapy	Number
Bleeding	13
Visual obstruction	4
Nostril obstruction	2
Oral cavity obstruction	6
Bleeding diathesis	5
Rapid growth with Necrosis	10
Total	40

Table 4: Gender distribution of vascular malformations

Lesions	Male	Female	Total
CM	22	45	67
LM	72	58	130
VM and LVM	170	146	316
AM, AVM, AVF	42	33	75
	306	282	588

**Table 5: Distribution vascular malformations according to site**

Lesion	Location																Total			
	Cervicofacial				Total	Trunk				Total	Extremities				Total	Multiple sites				
	ID	SC	IM	SC + IM		ID	SC	IM	SC + IM		ID	SC	IM	SC + IM		ID		SC	IM	SC + IM
CM	32	0	0	0	32	8	0	0	0	8	22	0	0	0	22	5	0	0	0	67
LM	0	31	0	22	53	0	12	0	6	18	0	13	3	38	54	0	4	0	1	130
VM and LVM	0	69		21	90	0	35	0	8	43	0	135	10	32	177				3	316
AM, AVM, AVF	0	27	0	5	32	0	3	0	1	4	0	26	0	13	39	0	0	0	0	75
Total	32	127	0	48	207	8	50	0	15	73	22	174	13	83	292	5	7	0	4	588

**Table 6: Interventions in vascular malformations**

Lesion	Intervention						Total
	Laser	Excision	Sclerotherapy	Sclerotherapy +Excision	Pre-op embolisation +Excision	No or incomplete treatment	
CM	29	23	0	0	0	15	67
LM	0	60	11	24	0	35	130
VM and LVM	0	109	78	108	0	21	316
AM, AVM, AVF	0	37	1	0	29	8	75
Total	29	229	90	132	29	79	588

**Table 7: Surgical intervention in vascular malformations**

Lesion	Surgery						Total
	Pry Closure	Local Flap	Regional Flap	Free Flap	Tissue Expander	Skin grafting	
CM	17	7	0	0	3	5	32
LM	83	9	4	0	0	15	111
VM and LVM	133	33	5	4	0	42	217
AM, AVM, AVF	61	3	3	3	0	2	72
Total	294	52	12	7	3	64	434

were treated with propranolol [Figure 2]. Only nine patients required surgery.

A total of 588 cases of vascular malformation were included in the study. On the whole, 87.24% (513/588) of cases were low-flow and 12.76% (75/588) were high-flow lesions. The distribution of types of vascular malformations as per gender and site is shown in Tables 4 and 5, respectively. The most common malformations were venous and lympho-venous accounting for 53.74% followed by LMs (22.1%), arterial/arterio VM (AVM) (12.76%) and the least common being CMs (11.39%). The overall gender distributions of the lesions were almost similar in both sexes with a slight male preponderance. Male predominance was evident in VM/LVM, LM and arterial malformation (AM)/AVM, but females significantly outnumbered the CM cases. Majority of the CM (47.74%) cases were in the cervico-facial region followed by 33.83% in the extremities. All the CMs were intradermal in location. LM and AM/AVM were distributed equally in cervico-facial area and extremities, but in case of VM/LVM, 56.12% were in extremities and 28.48% were in cervico-facial region. In all types of malformations, trunk was least affected. Most

of the LM cases were either subcutaneous (46.15%) or both subcutaneous and intramuscular (51.54%) involvement and only three had pure muscular involvement. Most of the VM/LVMs (76.58%) were in the subcutaneous plane and 20.25% were in both subcutaneous and muscular planes. However, significantly ten (3.16%) VM/LVM lesions were intramuscular and all of them were in extremities. In cases of AM/AVM, 34.66% were in subcutaneous tissue and 25.33% had involvement of both subcutaneous tissue and muscle. The ablative modalities used for different types of lesions are shown in Table 6, and the reconstructive option used for the post-excision defect is shown in Table 7. CM cases were either referred to the dermatology department for laser or were excised. The former option was exercised in 43.28% (29/67) of cases and 34.33% (23/67) of cases were excised. Excision was done in cases where the lesions were small and localised, and in some cases, the response of laser was suboptimal. Most of them (17) were primarily closed after excision, but seven required local flaps, three were closed by pre-expanded flaps and five defects were skin grafted. Fifteen (22.39%) patients with extensive CM either had incomplete ablation or could not be treated by any modality. Out of 130 LMs, 60 were excised and 11

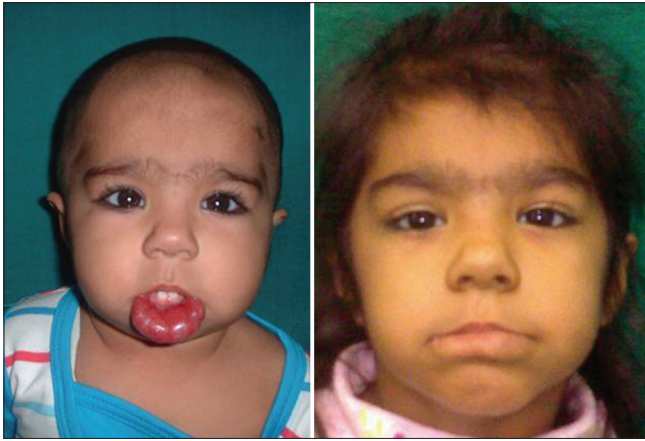


Figure 3: Venous malformation of the lower lip managed by sclerotherapy only

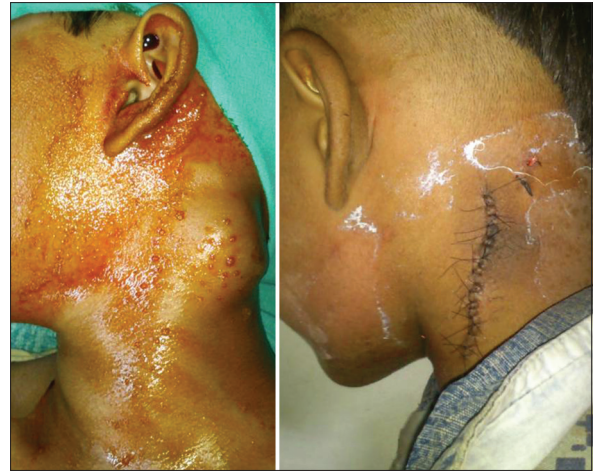

Figure 4: Localised lymphatic malformation of the neck, excised

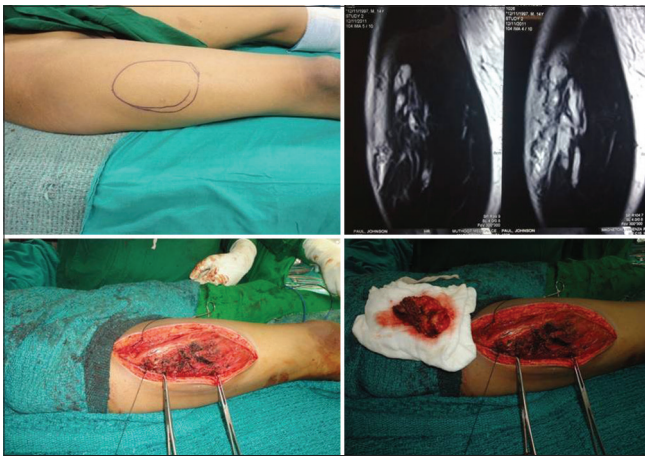


Figure 5: Excision of intramuscular venous malformation

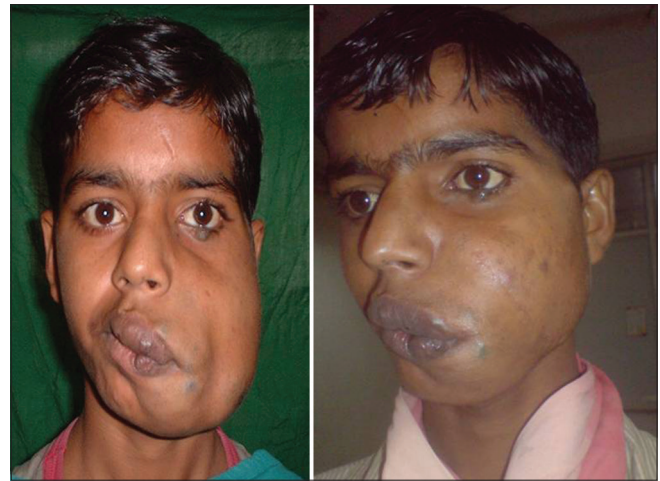


Figure 6: Extensive lymphovenous malformation of the face. Multiple sclerotherapy followed by partial debulking

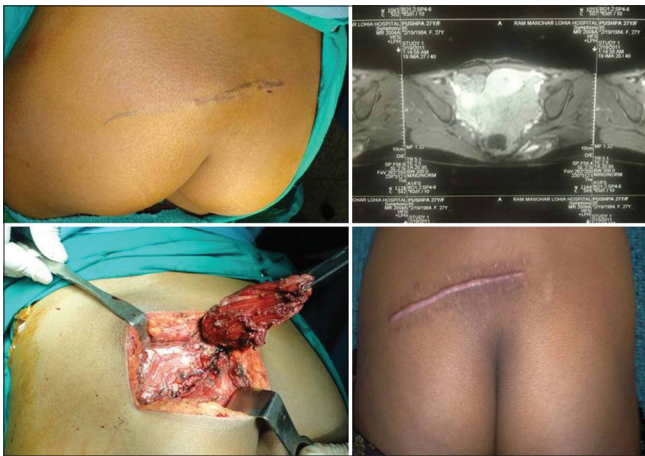

Figure 7: Intramuscular arterial malformation with feeding vessel from internal iliac artery. Preoperative embolisation and per-abdominal ligation of internal iliac artery followed by complete excision

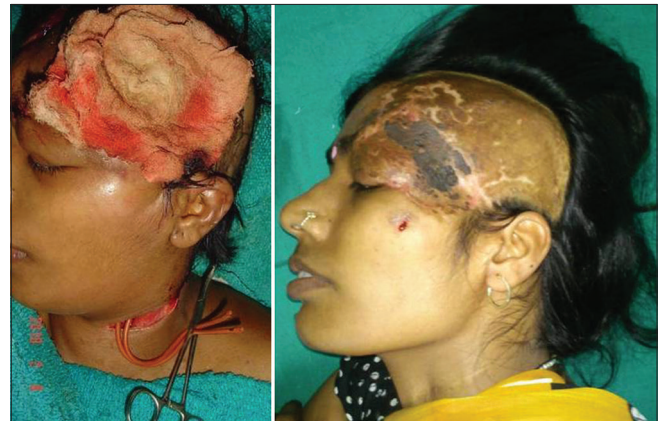

Figure 8: Arterial malformation temporal region with intractable bleeding. Ligation of external carotid artery followed by excision and skin grafting

were sclerosed by bleomycin and 24 patients underwent excision after one or multiple sessions of sclerotherapy. Thirty-five (26.92%) patients had either partial debulking or no excision owing to the extensive nature of the lesion.

In 83 patients, the post-excision defect could be closed primarily whereas nine and four cases required local and regional flaps, respectively, and 15 defects were skin grafted. Venous and lympho-VMs were managed by only excision, only sclerotherapy sclerotherapy followed by

excision. Seventy-eight patients were treated by sclerosant injection only [Figure 3]. Two hundred and seventeen cases were operated upon, and out of that, 109 cases were excised [Figures 4 and 5] and 108 were excised after sclerotherapy. In 21 patients with extensive lesion, partial excision or no ablation was done [Figure 6]. After excision, primary closure was possible in 133 cases, 33 needed local flaps, 5 needed regional flaps and 4 defects were reconstructed by free tissue transfer and 42 defects were skin grafted. Arterial and AVMs were either excised after securing control of the feeding artery or excised following embolisation [Figures 7 and 8]. The option of securing proximal control during operation was tourniquet, clamping or ligation of feeding vessel, encircling haemostatic sutures and occlusion with intestinal non-crushing clamps. Thirty-seven cases could be excised with pre-operative proximal control and 29 were removed after pre-operative embolisation. One patient of multiple arteriovenous fistulae of foot was managed with sclerotherapy under tourniquet. The patient had only temporary relief. In eight patients, ablation was not attempted owing to the extensive nature of the lesion or due to involvement of vital structures. Out of 66 cases of high-flow lesions which were operated upon, the post-excision defect could be primarily closed in 61, local, regional and free flaps were used in three cases each and 2 were skin grafted. In vascular malformations managed by sclerotherapy, the most common complication was overlying skin necrosis. The most common complication of excision in the cases of vascular malformation was haematoma.

## DISCUSSION

The vascular anomalies were first classified by Virchow in 1876.<sup>[2]</sup> Although the classification stood the test of time for nearly a century, it did not allow standardisation of treatment of vascular anomalies mainly because of lack of understanding of the natural behaviour of the lesions and erroneous terminologies. It was in 1982 Mulliken and Glowacki proposed a biological classification based on endothelial characteristics integrating physical findings, natural history and histology.<sup>[1]</sup> This system divided vascular anomalies into vascular tumours and vascular malformations.<sup>[1,3]</sup> The fundamental difference between the two is presence of endothelial proliferation in the former and vascular architectural aberration in the latter. This classification is now accepted worldwide, has brought a lot of clarity in the understanding of these lesions and has paved the way for standardised treatment

protocol. The treatment protocol used in the present study is based on this classification.

In this study, haemangiomas account for 25% and vascular malformations account for 75% of all vascular anomalies. Haemangioma is the most common infantile tumour in Western population where it occurs in 4%–10% of the population and 3–5 times more common in females. Haemangiomas are not as common in our country as the population is racially different. Sachin *et al.* reported that haemangiomas were only 15.56% of the vascular anomalies in their study<sup>[4]</sup> and 31.59% in a study by Ye *et al.*<sup>[5]</sup> The male-to-female ratio among haemangiomas in our study was 1:2.16 which is less than what is seen in European population.<sup>[6]</sup> Lesser female predominance of 1:1.49 was also reported by Ye *et al.*<sup>[5]</sup> Regarding regional predilection, majority (60.2%) of the lesions in the present study were cervico-facial followed by extremities and trunk which is reflected in other studies<sup>[4,5]</sup> as well.

In the present study, 43.88% (86/196) of patients of haemangiomas required some form of interventions, which is in consonance with studies from rest of the world.<sup>[7-11]</sup> Following the advent of use of propranolol, a pharmacotherapeutic agent for haemangioma, propranolol replaced prednisolone in our protocol from 2009 onwards, as it had a faster response and fewer side effects. Although there is a controversy regarding admission for propranolol administration,<sup>[12]</sup> all patients in our study were admitted for propranolol administration. The mechanism of action of propranolol remains vague, but it is believed to be due to regulation of vascular growth factors and haemodynamic cytokines.<sup>[13]</sup> In most studies, the majority of the cases were low flow but the proportion of high flow varied. In the study by Ye *et al.*, high flow accounted for 23.3%.<sup>[5]</sup> Although CMs are the most common malformations reported in literature, in this study, the venous and lympho VMs accounted for majority of cases (53.74%). In the literature, the reported prevalence of CM was 0.3% in children,<sup>[13]</sup> LM was 1: 2000–4000 live births<sup>[14]</sup> and VM was 1: 10000.<sup>[15]</sup> The treatment protocol for vascular malformation was fundamentally governed by three aspects, namely, its type, site and tissues involved. CMs are ideal for laser ablation. The Pulse dye laser is reported to be most efficacious in these although argon, potassium titanyl phosphate and 755 nm laser have also been used in advanced cases.<sup>[16,17]</sup> The laser treatment was done by dermatology department, and only cases with

long-standing CM with tissue hypertrophy were managed by us. Excision was the preferred modality in these cases. No treatment could be offered to six cases of extensive CMs who had presented in adult age and in whom lesions were thick precluding laser therapy, and in nine cases, incomplete removal was only possible. Such situations have been reported in literature as well.<sup>[18]</sup> Lymphatic malformations were mostly excised after sclerotherapy. Since many of the lesions had concomitant skin lesions, most of the extirpation left significant skin defects warranting either skin grafting or flap cover. This aspect of LM warranting complex reconstruction is reported in literature.<sup>[19]</sup> Several sclerotherapy options are available for sclerotherapy of LMs, namely, ethanol, bleomycin, OK-432 and doxycycline.<sup>[20-22]</sup> In our series, we have used bleomycin only. There was no sclerosant-related complications in LMs. Carbon dioxide laser has also been reported to be used in intra-oral LMs.<sup>[23]</sup> The management of VMs is also a multimodality approach which includes surgery, neodymium-doped yttrium aluminium garnet (Nd:Yag) laser and sclerotherapy.<sup>[24]</sup> Nd:Yag laser is reported to be very effective as it causes shrinkage and thrombosis of the aberrant venous channels.<sup>[24]</sup> Sclerotherapy is also an effective modality for VMs, and the sclerosants commonly used are sodium tetradecyl sulphate, ethanol, bleomycin and OK-432.<sup>[25-27]</sup> In our series, complete ablation of most of the VMs was possible with surgical excision either primarily or after sclerotherapy. However, for VMs in superficial plane, especially in face and hand, only sclerotherapy was tried at first to avoid post-surgical scarring and deformity. The gold standard of management of high-flow or AVM is excision with or without pre-operative embolisation of feeding vessel.<sup>[28]</sup> Most of the high-flow malformations in our series were also excised.

## CONCLUSION

The protocol has brought an element of much-needed objectivity in the management of vascular anomalies. This has helped us to define the management of particular lesion considering its pathology, extent and aesthetic and functional consequences of ablation to a certain extent. The basic premise of our management protocol is preservation of form and function vis-à-vis complete ablation. It is always wise to lean towards sclerotherapy in cases of LM and VM of face and hand. Sometimes, it is prudent to settle for a suboptimal excision to preserve aesthetic and function.

The algorithmic protocol also helps in counselling of patients regarding the course of management and possible outcome. The study reiterates the importance of seamless coordination of surgeon, reconstructive surgeon, intervention radiologist, cardiologist and laser therapist in managing these complex lesions. In a significant number of patients where no treatment could be offered underlines the fact that the final frontier in the management of vascular anomalies is yet to be reached.

## Declaration of patient consent

The authors certify that they have obtained all appropriate patient consent forms. In the form the patient(s) has/have given his/her/their consent for his/her/their images and other clinical information to be reported in the journal. The patients understand that their names and initials will not be published and due efforts will be made to conceal their identity, but anonymity cannot be guaranteed.

## Financial support and sponsorship

Nil.

## Conflicts of interest

There are no conflicts of interest.

## REFERENCES

1. Mulliken JB, Glowacki J. Hemangiomas and vascular malformations in infants and children: A classification based on endothelial characteristics. *Plast Reconstr Surg* 1982;69:412-22.
2. Balakrishnan G. Vascular anomalies of upper limb. *Ind J. Plast Surg.* 2011;44:276-82.
3. Finn MC, Glowacki J, Mulliken JB. Congenital vascular lesions: Clinical application of a new classification. *J Pediatr Surg* 1983;18:894-900.
4. Sachin K, Rashmi S, Manish S, Siddhartha W, Uday L. Haemangiomas and venous malformations of the head and neck: A retrospective analysis of endovascular management in 358 patients. *Indian J Plast Surg* 2013;46:109-16.
5. Ye CS, Pan LX, Huang YB, Han AJ, Ye RY, Li SQ, *et al.* Clinical analysis of vascular anomalies: A hospital-based retrospective study of 592 patients in Southeast China. *Chin Med J (Engl)* 2011;124:3008-12.
6. Hemangioma Investigator Group, Haggstrom AN, Drolet BA, Baselga E, Chamlin SL, Garzon MC, *et al.* Prospective study of infantile hemangiomas: Demographic, prenatal, and perinatal characteristics. *J Pediatr* 2007;150:291-4.
7. North PE, Waner M, Brodsky MC. Are infantile hemangiomas of placental origin? *Ophthalmology* 2002;109:633-4.
8. Yu Y, Flint AF, Mulliken JB, Wu JK, Bischoff J. Endothelial progenitor cells in infantile hemangioma. *Blood* 2004;103:1373-5.
9. Khan ZA, Boscolo E, Picard A, Psutka S, Melero-Martin JM, Barch TC, *et al.* Multipotential stem cells recapitulate human infantile hemangioma in immunodeficient mice. *J Clin Invest* 2008;118:2592-9.

10. Ronchese F. The spontaneous involution of cutaneous vascular tumors. *Am J Surg* 1953;86:376-86.
11. Metry D, Heyer G, Hess C, Garzon M, Haggstrom A, Frommelt P, *et al.* Consensus statement on diagnostic criteria for PHACE syndrome. *Pediatrics* 2009;124:1447-56.
12. Cushing SL, Boucek RJ, Manning SC, Sidbury R, Perkins JA. Initial experience with a multidisciplinary strategy for initiation of propranolol therapy for infantile hemangiomas. *Otolaryngol Head Neck Surg* 2011;144:78-84.
13. Richter GT, Friedman AB. Hemangiomas and vascular malformations: Current theory and management. *Int J Pediatr* 2012;2012:645678.
14. Perkins JA, Manning SC, Tempero RM, Cunningham MJ, Edmonds JL Jr., Hoffer FA, *et al.* Lymphatic malformations: Current cellular and clinical investigations. *Otolaryngol Head Neck Surg* 2010;142:789-94.
15. Boon LM, Mulliken JB, Enjolras O, Vikkula M. Glomovenous malformation (glomangioma) and venous malformation: Distinct clinicopathologic and genetic entities. *Arch Dermatol* 2004;140:971-6.
16. Chapas AM, Eickhorst K, Geronemus RG. Efficacy of early treatment of facial port wine stains in newborns: A review of 49 cases. *Lasers Surg Med* 2007;39:563-8.
17. Izikson L, Aderson RR. Treatment endpoint of resistant portwine stain with a 755 nm laser. *J Cosmetic Laser Therapy* 2009;11:52-5.
18. Tark KC, Lew DH, Lee DW. The fate of long-standing port-wine stain and its surgical management. *Plast Reconstr Surg* 2011;127:784-91.
19. Zeng RS, Liu XQ, Wang AX, Wang DW, Wang JN. Sequential treatment of giant lymphatic malformation of the tongue combined with severe oral and maxillofacial deformities. *J Oral Maxillofac Surg* 2008;66:2364-71.
20. Smith MC, Zimmerman MB, Burke DK, Bauman NM, Sato Y, Smith RJ; OK-Collaborative Study Group. Efficacy and safety of OK-432 immunotherapy of lymphatic malformations. *Laryngoscope* 2009;119:107-15.
21. Nehra D, Jacobson L, Barnes P, Mallory B, Albanese CT, Sylvester KG. Doxycycline sclerotherapy as primary treatment of head and neck lymphatic malformations in children. *J Pediatr Surg* 2008;43:451-60.
22. Okada A, Kubota A, Fukuzawa M, Imura K, Kamata S. Injection of bleomycin as a primary therapy of cystic lymphangioma. *J Pediatr Surg* 1992;27:440-3.
23. Glade RS, Buckmiller LM. CO2 laser resurfacing of intraoral lymphatic malformations: A 10-year experience. *Int J Pediatr Otorhinolaryngol* 2009;73:1358-61.
24. Glade RS, Richter GT, James CA, Suen JY, Buckmiller LM. Diagnosis and management of pediatric cervicofacial venous malformations: Retrospective review from a vascular anomalies center. *Laryngoscope* 2010;120:229-35.
25. Perkins JA, Manning SC, Tempero RM, Cunningham MJ, Edmonds JL Jr., Hoffer FA, *et al.* Lymphatic malformations: Review of current treatment. *Otolaryngol Head Neck Surg* 2010;142:795-803, 803.e1.
26. Berenguer B, Burrows PE, Zurakowski D, Mulliken JB. Sclerotherapy of craniofacial venous malformations: Complications and results. *Plast Reconstr Surg* 1999;104:1-11.
27. Wang YA, Zheng JW, Zhu HG, Ye WM, He Y, Zhang ZY. Sclerotherapy of voluminous venous malformation in head and neck with absolute ethanol under digital subtraction angiography guidance. *Phlebology* 2010;25:138-44.
28. Bradley JP, Zide BM, Berenstein A, Longaker MT. Large arteriovenous malformations of the face: Aesthetic results with recurrence control. *Plast Reconstr Surg* 1999;103:351-61.