

Case Report

Birth palsy in congenital varicella syndrome: A lesson in anatomy

Ajeesh Sankaran, Praveen Bhardwaj, Hari Venkatramani, Shanmuganathan Raja Sabapathy

Department of Plastic Surgery, Hand and Microsurgery, Ganga Medical Centre and Hospitals, Coimbatore, Tamil Nadu, India

Address for correspondence: Dr. Ajeesh Sankaran, Department of Plastic Surgery, Hand and Microsurgery, Ganga Medical Centre and Hospitals, 313, Mettupalayam Road, Coimbatore - 641 013, Tamil Nadu, India. E-mail: ajaxsankaran@gmail.com

ABSTRACT

While brachial plexus palsy sustained due to birth trauma is well known, congenital palsies are decidedly rare. We report such a case caused by congenital varicella syndrome, with associated congenital Horner's syndrome and heterochromia iridis. The surprising juxtaposition of a classic upper plexus palsy and a Horner's syndrome raises points of interest. Similar reports in literature are reviewed, and the genesis of a very characteristic group of findings is discussed.

KEY WORDS

Brachial plexus neuropathy; congenital varicella syndrome; congenital Horner's syndrome; heterochromia iridis

INTRODUCTION

Brachial plexus palsy presenting from birth is almost always attributed to trauma sustained during childbirth. Rarely, however, the paralysis may be due to *in utero* causes including agenesis of the cervical spinal nerve roots and various maternal infections. Maternal varicella (chickenpox) infection is well established to be a cause of various foetal deformations that are grouped under the moniker of 'Congenital Varicella Syndrome' (CVS). CVS involves the skin, the eyes, the limbs and the nervous system.^[1] Brachial plexus palsy has been described in two cases.^[2]

We describe a child with CVS with associated upper brachial plexus palsy and Horner's syndrome. Of note

was a characteristic set of features that defined the patho-anatomy of the viral infection clearly. The possible site of origin of, and the literature on, each feature is then reviewed.

CASE REPORT

A 17-month-old first-born female child presented to the brachial plexus clinic with complaints of weakness of the right shoulder and elbow, noticed from birth. Hand and wrist movements were present at birth. No improvement in the movements over these 17 months was reported. The paresis was accompanied by a prominent scar over the entire limb from the shoulder to the thumb. Both the

This is an open access journal, and articles are distributed under the terms of the Creative Commons Attribution-NonCommercial-ShareAlike 4.0 License, which allows others to remix, tweak, and build upon the work non-commercially, as long as appropriate credit is given and the new creations are licensed under the identical terms.

For reprints contact: reprints@medknow.com

How to cite this article: Sankaran A, Bhardwaj P, Venkatramani H, Sabapathy SR. Birth palsy in congenital varicella syndrome: A lesson in anatomy. Indian J Plast Surg 2018;51:238-42.

Access this article online	
Quick Response Code:	Website: www.ijps.org
	DOI: 10.4103/ijps.IJPS_56_18

thumb and index finger were also hypoplastic, apart from the scarring [Figure 1a]. The skin scar was reported to be bright red at birth (no pictures were available) that had lightened over time. The child also had a ptosis of the right eye with lighter pigmentation of the iris as compared to the other eye. The iris was reported to be paler at birth and had apparently improved in pigmentation with growth. The reported developmental milestones were appropriate for her age.

The mother had developed chickenpox after the 3rd month of pregnancy (week 13) that had been treated symptomatically. No antivirals or immunisation had been administered. The family history was non-contributory.

On examination, the general development was confirmed appropriate for age. The following clinical features were noted:

- The eye: Ptosis, miosis and enophthalmos were present in the right eye [Figure 1b]. The iris was light brown in colour compared to black on the left side
- The skin: The skin over the entire pre-axial border of the upper limb was scarred from the shoulder to the hand, including the hypoplastic thumb and index fingers
- Right upper limb: The limb was held in the classic 'waiter's tip' position described for an upper brachial plexus palsy. No active shoulder abduction or external rotation was present. Adduction and internal rotation were present but weak. The elbow was held fully extended with no active flexion and had good extension power. The wrist and the fingers showed full movements. The motor profile, as per the Active Movement Scale, is summarised in Table 1. Of note was the complete absence of co-contractions. Given the age, a reliable sensory examination could not be carried out.

With a provisional diagnosis of CVS with brachial plexus palsy, we performed a magnetic resonance scan to rule out cervical root agenesis or cervical cord anomalies. It confirmed no anomaly in the plexal elements and revealed severe atrophy of the biceps and shoulder musculature.

Given the age of the child, an exploration of the brachial plexus was not indicated. However, an Oberlin's nerve transfer could possibly be performed to attempt restoration of elbow flexion. Hence, the arm was explored for the status of the musculocutaneous nerve. During surgery, the biceps was found to be completely pale and had

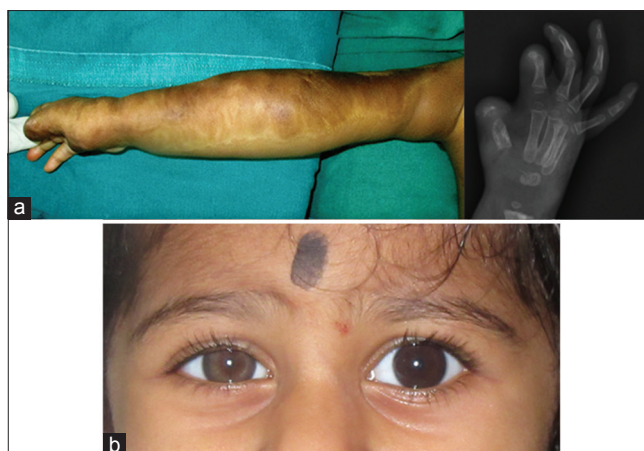

Figure 1: (a) Cicatricial skin lesion along the pre-axial border of the right upper limb, with X-ray of the right hand showing hypoplasia of the thumb and index finger. (b) Hypochromia of the right iris

Table 1: The motor power profile, with a description of the Active Movement Scale

Joint	AMS	Active Movement Scale
Shoulder		Gravity eliminated
Abduction	0/7	No movement: 0
Adduction	7/7	Flicker of contraction: 1
External rotation	0/7	<50% of range: 2
Internal rotation	7/7	>50% of range: 3
Flexion	6/7	Full: 4
Elbow		Against gravity
Extension	7/7	<50% of range: 5
Flexion	0/7	>50% of range: 6
Forearm		Full: 7
Supination	0/7	
Pronation	7/7	
Wrist		
Flexion	7/7	
Extension	7/7	
Fingers		
Flexion	7/7	
Extension	7/7	
Thumb		
Flexion	7/7	
Extension	7/7	

undergone a severe fatty degeneration [Figure 2a]. Hence, the plan of nerve transfer was abandoned. The thumb was made more functional by phalangisation [Figure 2b]. The first web was released by a Gilles' hatchet flap, and a full-thickness graft was placed.

To restore elbow flexion, a provisional free functioning muscle transfer is planned after the age of 4 years. Tendon transfer options for the shoulder, like a Trapezius transfer, need to be assessed as the child grows up. Similarly, the cosmetic correction of the skin scar and the ptosis is planned for later.

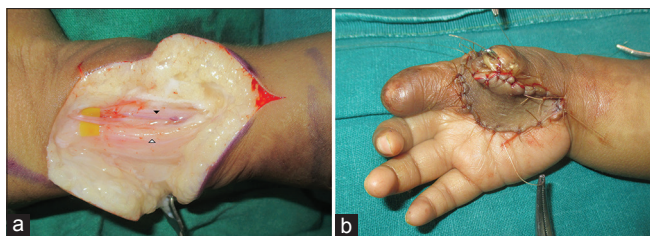


Figure 2: (a) Findings on exploration of the arm. White arrowhead is on the severely atrophic biceps muscle. Yellow marker has been placed underneath the musculocutaneous nerve. Black arrowhead points to the normal brachial artery. Right hand after a phalangisation of the thumb, with full-thickness skin graft in the first web

DISCUSSION

After the first case of CVS was described in 1947, 130 cases had been described by 2013.^[3] The mechanism of development of CVS is still not clearly understood. The varicella zoster virus (VZV) is a member of the human herpes virus group and known to be neurotropic and lymphotropic. It has been found distributed throughout foetal tissue, possibly due to an early viremia.^[4]

Most intrauterine infections with VZV do not lead to any signs/symptoms. A few affected children develop herpes zoster postnatally. More fulminant infections lead to foetal death and abortion. CVS is, therefore, a rare outcome of maternal varicella.^[1]

The risk of developing CVS varies with gestational age at infection. A prospective study of 1739 maternal varicella conducted in Germany and the UK found the highest risk in the 13–20 weeks' gestational period (2.0%).^[5] Another study found the trimester-wise risk of developing CVS, after maternal infection, to be 0.55%, 1.4% and 0% for the first, second and third trimesters, respectively. Females are more commonly affected, with 66%–85% of all cases in various series being female children.^[6]

CVS leads to a wide variety of clinical features, affecting most organ systems. Skin lesions are cicatricial, hyperpigmented and appear to be dermatomal in pattern. Ocular features include cataracts, chorioretinitis, Horner's syndrome, iris pigmentation defects and microphthalmia. Typical limb defects include hypoplasia, scarring and malformed digits. Many children have microcephaly, associated with cortical atrophy and varying degrees of mental retardation. Autonomic disturbances such as a neurogenic bladder or oesophageal reflux may also be present.

VZV is known to grow in the neurons of the spinal cord. The anterior horn motor cells develop by 12 weeks of intrauterine life, while the muscular structures are largely in place by 9 weeks.^[2] Hence, it is quite possible to develop muscles that have never been innervated. A profound lower-motor neuron paralysis would be the resulting clinical picture. Since no neuroma formation or recovery is possible in such a scenario, no co-contractions can be expected to develop. The atrophy that results from this involvement would be striking due to a complete lack of innervation/recovery. Pertinent to note is that such a lesion cannot technically be classified as a brachial plexus palsy, with the insult situated at the cord level resembling poliomyelitis.

Congenital brachial plexus paralyses are underappreciated and studied, no doubt due to their rarity. They can be expected to present with a striking atrophy, no recovery and no co-contractions. An electromyogram (EMG) carried out immediately after birth can theoretically show a denervation pattern of the upper-limb muscles in such intrauterine insults. Such changes are expected to be noted in muscles after at least 10 days, in case of birth trauma.

It has long been argued that not all upper-limb paralyses noted at birth can be directly attributed to birth trauma.^[7] Apart from agenesis of the plexal elements and intrauterine infections, several other aetiological factors are known to present similarly. Some of these are as follows:

1. Familial congenital brachial plexus palsy – At least three families of multiple affected members with brachial plexus palsy from birth have been reported.^[8] The exact cause and inheritance pattern have not been elucidated. However, it is assumed that an intrinsic decreased resistance of peripheral nerve to stretch can cause paralysis with even normal uterine forces during delivery
2. Intrauterine maladaptation – Sustained pressure on the brachial plexus due to poor foetal upper-limb positioning has been theorised to account for birth palsy with minimal or no birth trauma. Joint contractures at birth, hypoplastic forearm and hand, osteoporosis of the humerus and EMG evidence of denervation immediately after birth are the clinical features. Rarely, a documented maternal uterine malformation has also been held accountable.^[7] The mechanism here appears to be similar to a compression neuropathy of the peripheral nerves. However,

the most controversial of all intrauterine causes is placental insufficiency. Jain *et al.* showed from a mathematical model that a 50% decrease in placental surface area produces ischaemia of the posteriorly situated left shoulder^[9]

3. Bony causes – Osteomyelitis of the humerus or the cervical vertebrae can present with sudden-onset painful paresis of the upper limb, usually a few days after birth.^[7] Unlike a ‘pseudoparesis’ due to pain, the movements do not recover immediately following resolution of the infection. Ischaemia of the plexal elements has been blamed as the pathology in such cases
4. Tumours – Neoplasms of the brachial plexus *per se* are rare in newborns and include rhabdoid tumours, myofibromas and neurofibromas. Haemangiomas of the shoulder region can present with a compressive or ischaemic brachial plexus palsy^[7]
5. Mimics – CVS, including our case, cannot be considered as birth palsy in the traditional sense as it is a cord-level insult. Similar conditions which appear superficially like a brachial plexus palsy include amyoplasia, pseudoparesis, congenital cervical spinal atrophy and pyramidal tract lesions.

While Horner’s syndrome accompanying brachial plexus palsy is nothing new, a congenital Horner’s syndrome is particularly rare. The route that the sympathetic system takes from the hypothalamus to the face and the eye is reviewed in Figure 3a. It should be noted that the usual Horner’s syndrome is a sign of avulsion of the lower roots (C8, T1), while this child had intact motor function of these myotomes. Hence, the disruption must be localised to the Level I neuron or central neuron at the C5 and C6 levels rather than the usual Level II or pre-ganglionic neuron at C8-T1 level. The sympathetic input to the iris also maintains the growth of melanosomes in the

superficial stroma of the iris.^[10] Lack of this stimulus during development leads to hypochromia of the iris.

Pharmacologic tests have been described to confirm and localise the lesion in patients with Horner’s syndrome. While they can differentiate between a pre-ganglionic and post-ganglionic insult, there are no known tests that can reliably differentiate between a central and pre-ganglionic one. Only the associated clinical features can provide a clue to the level of neurologic involvement. In our case, the upper plexus palsy indicates the level to be central [Figure 3b]. In addition, the hypochromia fixes the time to be intrauterine rather than perinatal.

al-Qattan and Thomson have reported two cases of CVS with brachial plexus palsy: one with Horner’s syndrome and one without Horner’s syndrome.^[2] Hypochromia has not been mentioned as a feature. Interestingly, both these patients had involvement of the lower roots with poor hand function that did not recover.

CONCLUSION

CVS is a rare result of a foetal VZV infection and is then only unusually known to produce upper-limb paresis. What could easily have been passed off as another ‘Erb’s palsy’ presented three singular features: a hypochromia iridis, an association of Horner’s syndrome with pure C5 and C6 paralysis and a dermatomally defined cutaneous lesion. These features localise the insult spatially to the cervical spinal cord and temporally to the early foetal period.

Declaration of patient consent

The authors certify that they have obtained all appropriate patient consent forms. In the form the patient(s) has/have given his/her/their consent for his/her/their images and other clinical information to be reported in the journal.

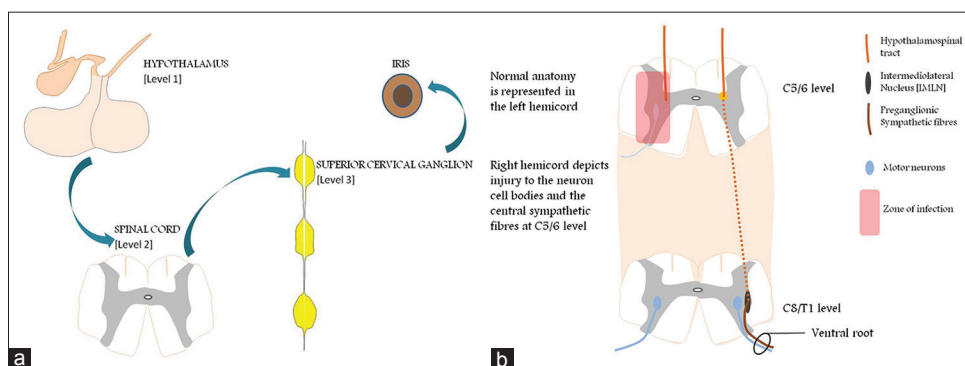


Figure 3: (a) Diagrammatic representation of the sympathetic pathway from the hypothalamus to the iris. (b) Diagrammatic representation of the possible location of the lesion

The patients understand that their names and initials will not be published and due efforts will be made to conceal their identity, but anonymity cannot be guaranteed.

Financial support and sponsorship

Nil.

Conflicts of interest

There are no conflicts of interest.

REFERENCES

1. Smith CK, Arvin AM. Varicella in the fetus and newborn. *Semin Fetal Neonatal Med* 2009;14:209-17.
2. al-Qattan MM, Thomson HG. Congenital varicella of the upper limb. A preventable disaster. *J Hand Surg Br* 1995;20:115-7.
3. Ahn KH, Park YJ, Hong SC, Lee EH, Lee JS, Oh MJ, *et al.* Congenital varicella syndrome: A systematic review. *J Obstet Gynaecol* 2016;36:563-6.
4. Nikkels AF, Delbecq K, Pierard GE, Wienkotter B, Schalasta G, Enders M, *et al.* Distribution of varicella-zoster virus DNA and gene products in tissues of a first-trimester varicella-infected fetus. *J Infect Dis* 2005;191:540-5.
5. Enders G, Miller E, Craddock-Watson J, Bolley I, Ridehalgh M. Consequences of varicella and herpes zoster in pregnancy: Prospective study of 1739 cases. *Lancet* 1994;343:1548-51.
6. Tan MP, Koren G. Chickenpox in pregnancy: Revisited. *Reprod Toxicol* 2006;21:410-20.
7. Alfonso DT. Causes of neonatal brachial plexus palsy. *Bull NYU Hosp Jt Dis* 2011;69:11-6.
8. Zaki MS, el Sabbagh MH, Aglan MS. Familial congenital brachial palsy: A report of two affected Egyptian families. *Genet Couns* 2004;15:27-36.
9. Jain V, Sebire NJ, Talbert DG. Kaiser Wilhelm syndrome: Obstetric trauma or placental insult in a historical case mimicking Erb's palsy. *Med Hypotheses* 2005;65:185-91.
10. McCartney AC, Riordan-Eva P, Howes RC, Spalton DJ. Horner's syndrome: An electron microscopic study of a human iris. *Br J Ophthalmol* 1992;76:746-9.