

Original Article

Application of embryonic equivalents in male-to-female sex reassignment surgery

Balakrishnan Margabandu Thalaivirithan, Maithreyi Sethu, Dinesh Karuvakkurichi Ramachandran, Mahadevan Kandasamy, Jaganmohan Janardhanam

Department of Plastic Reconstructive and Faciomaxillary Surgery, Madras Medical College, Chennai, Tamil Nadu, India

Address for correspondence: Dr. Balakrishnan Margabandu Thalaivirithan, Old No. 15, New No. 10, Thiruvalluvar Street, Rangarajapuram, Kodambakkam, Chennai - 600 024, Tamil Nadu, India. E-mail: thalaiviri.b@gmail.com

ABSTRACT

Introduction: The feeling of incongruence between phenotypic sex and psychological recognition of self-gender is termed gender dysphoria. Transsexualism is the most extreme form of this disorder. **Aims and Objectives:** The aims and objectives of the study are to evaluate the esthetic and functional outcome of embryonic equivalents-based male-to-female sex reassignment surgery in transwomen using the institutional scoring system. **Materials and Methods:** Thirty transwomen who had undergone male-to-female embryonic equivalents-based sex reassignment surgery (MFEEbSRS) from October 2012 to March 2016 were retrospectively studied. The outcome was evaluated by two independent plastic surgeons, based on interview with the individuals, visual assessment, and measurements. **Surgical Technique:** Clitoris was created from reduced glans on dorsal penile pedicle mounted on the crura of the conjoined corpora cavernosa. De-gloved unfurled proximal penile skin formed the introitus, hood for clitoris and labia minora. Neo-external urethral meatus was fashioned from the distal portion of the bulbar urethra. Distal de-gloved inverted penile tube flap was used for the creation of neovagina. Reduced scrotal flaps formed the labia majora. **Observation and Results:** The maximum length of neovagina in the study was 12 cm, and the average length was 9.8 cm. Based on our institutional scoring system for the assessment of esthetic and functional outcome, we got excellent results in all transwomen. **Conclusion:** The esthetic and functional outcome in all the patients was good. All patients were relieved of their primordial feminine tension and satisfied with the surgery. Their personality, lifestyle, and self-esteem improved remarkably following surgery.

KEY WORDS

De-gloved penile inversion flap; male to female embryonic equivalents-based sex reassignment surgery; transgenders; transwomen; vaginoplasty

Access this article online	
Quick Response Code: 	Website: www.ijps.org
	DOI: 10.4103/ijps.IJPS_62_18

This is an open access journal, and articles are distributed under the terms of the Creative Commons Attribution-NonCommercial-ShareAlike 4.0 License, which allows others to remix, tweak, and build upon the work non-commercially, as long as appropriate credit is given and the new creations are licensed under the identical terms.

For reprints contact: reprints@medknow.com

How to cite this article: Thalaivirithan BM, Sethu M, Ramachandran DK, Kandasamy M, Janardhanam J. Application of embryonic equivalents in male-to-female sex reassignment surgery. Indian J Plast Surg 2018;51:155-66.

INTRODUCTION

Gender Dysphoria (GD) is seen in some diversified individuals who have varying degrees of disgruntlement of their anatomical, phenotypic sex, and genderness. In addition, they have intense desire to possess secondary sexual properties of the opposite sex. GD is a unique human condition that is classified behaviorally but treated medically by hormones and surgery. In 2010, the World Professional Association for Transgender Health (WPATH)^[1] declared GD to be dissociated from functional and psychological disorders. This has led to a vast change in the social and political scenario for the GD worldwide. The treatment includes self-rehabilitation through a multidisciplinary team approach and the traditional triadic sequence; the final step of which being sex reassignment surgery in this complete human transformation.^[2]

In 1966, the influential book by Benjamin, *The Transsexual Phenomenon*,^[3] made many clinicians aware of the potential benefits of sex reassignment surgery. In 1973, the diagnosis of “GD syndrome” was introduced by Fisk^[4] to define the distress resulting from conflicting gender identity and sex of assignment. “Transsexualismus,” the term was coined by Magnus Hirschfeld in 1923. The term “transsexualism” first appeared officially in the widely used Diagnostic and Statistical Manual of Mental Disorders Edition in 1980.^[5] In the recent edition, the term transsexualism was replaced by the term GD.

The feeling of incongruence between phenotypic sex and psychological recognition of self-gender is termed GD. Transsexualism is the most extreme form of this disorder.

Meerwijk and Sevelius in their meta-analysis study published in 2017 revealed in the USA that 390/100,000 adults are estimated to be transgender.^[6] No definite figures are available for India,^[7] but transgender population is palpably on the rise.

Androgen produced by the male fetus brings about changes in the fetal brain, which are essential for the development of male gender identity. Gender identity is reinforced by the gender role the child is exposed to, in the early years.

Transsexuals, however, identify themselves with the psychological sex, which is opposite to their physical sex, and hence feels trapped in the wrong body. Recent research indicates that genetic factors, as well as fetal

neurodevelopment, contribute to this. Many sexually dimorphic nuclei have been found in the hypothalamus.^[8] One of these is the central subdivision of Bed nucleus of Stria Terminalis.^[9] In human males, the volume of this nucleus and its number of neurons is twice compared to females. In transwomen, it was similar to female controls.

This article explores an anatomical approach of converting and harmonizing the external genitalia according to the mind of these transwomen.

Aims and objectives

The aims and objectives of the study are to evaluate the esthetic and functional outcome of male-to-female embryonic equivalents-based sex reassignment surgery (MTFEEbSRS) using the institutional scoring system [Table 1].

MATERIALS AND METHODS

Thirty transwomen who had undergone MTFEEbSRS between October 2012 and March 2016 were retrospectively studied [Table 1]. Preoperative counseling and pertinent legal issues were explained, and informed consent was obtained from each transwoman. Institutional Ethical Committee permission was obtained for this study.

Tools used for the assessment of esthetic and functional outcome

Institutional scoring system for the evaluation of esthetic and functional outcome was used and each transwoman was assigned a score at the end of the follow-up period by two independent plastic surgeons, and the average was obtained [Table 1].

- Age of the patients ranged from 21 to 42 years (average of 31.5 years)
- There were no comorbid conditions associated with the patients except that 15 individuals tested positive (for human immunodeficiency virus I and II), but their CD4 count was >400 cells/mm³.

Inclusion criteria

- 30 Transsexuals who fulfilled the Benjamin criteria^[3] and had undergone male to female SRS were only included in the study
- Individuals who had completed the prescribed period of cross-living and hormonal therapy
- Individuals with stable mental status, assessed by psychiatrists
- Those who wanted to have a serviceable vagina.

Table 1: The clinical details of operated transwomen

Serial number of transwomen	Age	HIV status	Length of neovagina created (cm)	Complications [#]	Secondary procedure	Institutional Score of esthetic outcome*	Institutional score of functional outcome**
1	22	-	9	E	None	3	3
2	31	+	8.7	E	None	3	3
3	36	-	11.5	E	None	3	3
4	26	+	12	E	None	3	3
5	24	-	9.5	E	None	3	3
6	40	-	7.5	E	None	3	3
7	30	+	10	E	SR	2	2
8	33	+	8	E	None	3	3
9	25	-	10.5	E	None	3	3
10	33	+	9	E	None	3	3
11	24	-	10	E	None	3	3
12	41	-	12	E	None	3	3
13	28	+	9.5	E	None	3	3
14	32	-	10.5	E	None	3	3
15	29	-	12	E	None	3	3
16	26	+	11	MI+MC+E	None	3	3
17	39	-	10.5	E	None	3	3
18	35	+	9.8	E	None	3	3
19	27	+	9	E	None	3	3
20	21	-	8.6	E	None	3	3
21	33	+	10	E	None	3	3
22	34	-	8.5	E	None	3	3
23	38	+	9.8	MI+MC+E	None	3	3
24	32	-	8	E	None	3	3
25	39	+	10.2	E	None	3	3
26	24	+	12	E	None	3	3
27	32	+	9.2	E	None	3	3
28	28	-	10	E	None	3	3
29	35	-	9	E	None	3	3
30	30	+	9.5	E	None	3	3
Average	31.5		9.8			2.9	2.9

[#]All these were minor complications managed conservatively except SR in one individual. *The following institutional grading system was used for the assessment of esthetic outcome assigned at the end of an average follow up period of 18 months. Grade 1: Poor outcome-Hyper pigmented/hypo pigmented widened scar; ill-defined introitus; severely distorted submerged clitoris; severely contracted neo-vaginal pouch. Grade 2: Intermediate outcome-Scars hypertrophic; introitus moderately defined; moderately projected clitoris on the crural mount; Mild to moderately contracted neo-vaginal pouch. Grade 3: Excellent outcome-Imperceptible scar merged in the esthetic subunits of external genitalia; well-defined introitus; desired clitoral projection at the proximal end of the introitus commissure, hooded by the scrotal flap and degloved penile flap junction; capacious vaginal introitus. **The following institutional grading system was used for the assessment of functional outcome assigned at the end of an average follow up period of 18 months. Grade 1: Poor outcome-Painful clitoris and scars with no ergogenic response; poor, distorted urinary stream with external urethral meatal stenosis; inadequate severely contracted vagina causing dyspareunia. Grade 2: Intermediate outcome-esthetic clitoris with inadequate ergogenic response; able to micturate in squatting position but distorted urinary stream with wetting of perineum; pain free; mildly contracted neo-vagina. Grade 3: Excellent outcome-Excellent ergogenic response; able to pass urine in the squatting posture with good stream; adequate and well serviceable vagina. E: Edema, MC: Mild collection, MI: Mild Infection, SR: Scrotal flap reduction, HIV: Human Immunodeficiency virus

Exclusion criteria

- Patients who had undergone SRS previously following any other technique
- Retroviral (HIV)-positive patients with CD4 count <400 cells/mm³
- Other psychiatric illness.

Preoperative preparations

Patients were examined [Figure 1] to rule out local surgical or medical problems (i.e., hydrocele, hernia, and fungal infections). Routine investigations and additional investigations were:

- Liver function tests

- Serum lipid profile
- Coagulation profile, which included bleeding time, clotting time, prothrombin time (INR ratio <1.5), and platelet count (>100,000/mm³) (as these individuals were on hormone therapy)
- They were screened for sexually transmittable diseases. Retroviral (HIV)-positive patients were subjected to CD4 count to ensure that it is >400 cells/mm³. Details of hormone treatment taken by the patients were recorded.

Operative procedure

All patients were operated under spinal anesthesia. Universal precautions were strictly followed. Patient in

lithotomy position, lower abdomen, perineum, and both thighs were prepared and draped. Prepuce was retracted. Circular marking was done around the corona glandis, at the junction of the glans penis and the prepuce. Another hemicircular marking was placed on the ventral surface of the penis at the junction of the penis and the scrotum. From the mid-point of this marking an incisional marking was carried out along the median raphe of the scrotum up to its posterior end. Tumescant (1:200,000 adrenalin in normal saline) was injected in all the markings. The incision was started first in the corona glandis area, and the whole penile body skin was de-gloved by dissecting in a plane deep to the Bucks fascia and superficial to the tunica albuginea. The tunica albuginea with the embedded deep dorsal vein of the penis flanked on each side by the dorsal artery and nerve of the penis was maintained on the dorsum of the penis during this dissection. This was relatively avascular plane and can be easily achieved with a combination of sharp and blunt dissection. The hemi-circle incision at the penoscrotal junction was deepened to the level of tunica albuginea. The incision was further extended up to the posterior scrotal skin, halving the scrotum into two parts. High orchiectomy was carried on either side at the level of the external superficial inguinal ring, preserving the scrotal flaps, which contained the skin, dartos, and Colles fascia [Figure 2]. The body of the penis with the glans was delivered in a retrograde fashion through the hemi-circular incision leaving the de-gloved penile skin, which was subsequently inverted, from the glandular end [Figure 3]. The superficial external pudendal artery formed the vascular basis of the pedicled inverted penile tube flap, which also retained its innervation from branches of the dorsal nerve of penis.

Dissection was started at the junction between the body of the penis and the root of the penis by dissecting away

the distal fibers of the bulbospongiosus just distal to the transition of bulb of penis to the corpus spongiosum. Working on the tunica albuginea and dissecting between the ventral surfaces of the conjoint septum of corpora cavernosa, proximal 1.5 cm length of the corpus spongiosum was isolated by dividing it from the rest of the body of the penis [Figure 4].

0.75 cm × 0.75 cm × 0.50 cm of glans in the dorsal median plane was harvested along with a long strip of tunica albuginea enclosing the central deep dorsal vein of the penis flanked on either side by the dorsal artery of penis and dorsal nerve of penis. This surgical step was based on good vascular communication between the arteries of the bulb with the dorsal artery of the penis at the corona glandis.^[10] Both the corpora with the conjoint septum was ligated in continuity and divided at the level of the transition from crus to corpus to create a crural mount [Figure 5]. The small glandular erectile tissue was recruited on the long strip of the tunica albuginea vascular pedicle was fixed over this crural mount after removing the rest of the body of the penis and the glans. This formed the neo-clitoridis, which was the embryological equivalent of glans penis (both are the embryonic derivatives of gonadal tubercle) [Figures 6, 7 and Table 2].

Dissection was done in the posterior midline of the urogenital diaphragm posterior to the bulb of the penis by dividing the central tendinous portion of superficial and deep transverse perinei muscles and dissecting through the perineal body posterior to the membranous urethra and the prostate up to the medial most fibers of the levator ani (levatores prostate). This existed as a normal dehiscence beyond the superficial fascia of the deep perineal pouch. This dissection creates a space for the neovaginal pouch.



Figure 1: Preoperative

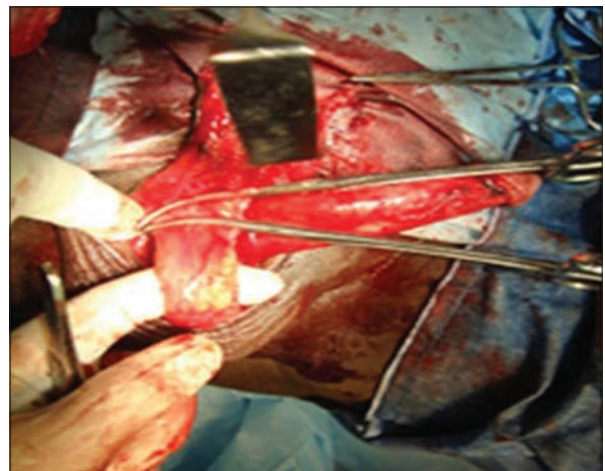


Figure 2: Intra-operative picture showing high orchiectomy

Table 2: Embryonic equivalents observed by the author

<i>Undifferentiated gonads (exists up to 6 weeks of embryonic life)</i>	<i>Male derivative</i>	<i>Female derivative</i>	<i>MTFEEbSRS technique</i>
Genital tubercle	Glans penis	Glans clitoridis	Reduced glans on dorsal penile pedicle
Urethral folds	Corpus spongiosum and penile skin	Labia minora and introitus	De-gloved unfurled proximal penile skin forms the introitus and labia minora
Urogenital sinus	Bulbar urethra, prostatic urethra, membranous urethra	Female urethra Sino vaginal bulb-develops as an off shoot, establishes connection with the distal end of the fused mesonephric duct to form the vagina and the fornices	External urethral meatus is derived from the distal portion of the bulbar urethra De-gloved inverted penile tube, which is the equivalent of ectodermal growth of the urogenital sinus, is used for the creation of neo-vagina
Labioscrotal swelling	Scrotum	Labia majora	Reduced scrotal flaps forms the labia majora

MTFEEbSRS: Male to female embryonic equivalents-based sex reassignment surgery

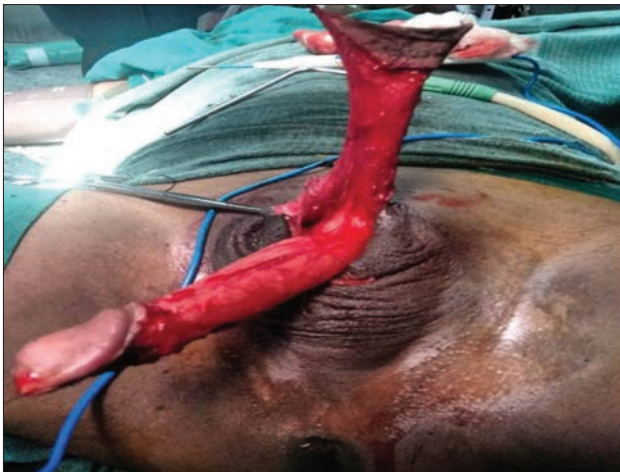

Figure 3: Intra-operative picture showing the de-gloved penile flap

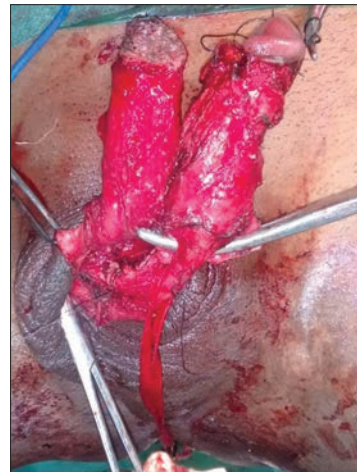

Figure 4: Intra-operative picture showing separation of corpus spongiosum from the corpora cavernosa

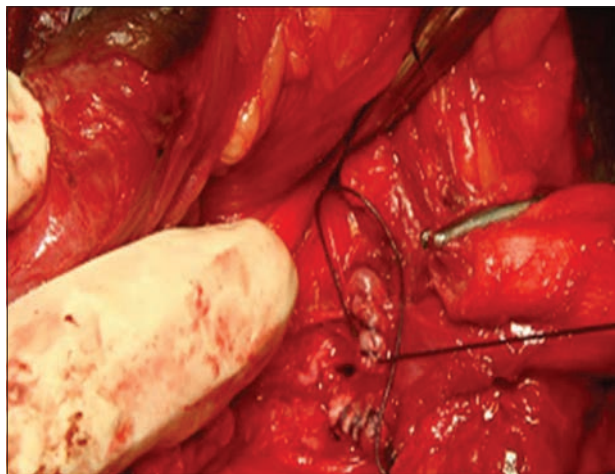


Figure 5: Intra-operative picture showing base fashioned from the crura of the corpora cavernosa cranial to catheterised bulbar urethra for reduced clitoral flap

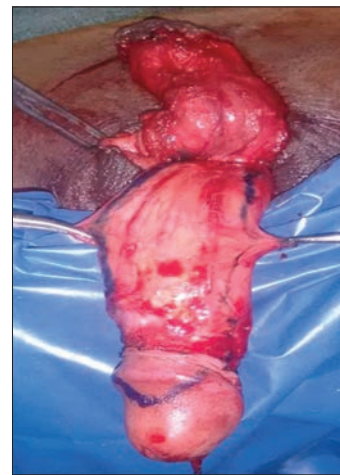

Figure 6: Intraoperative picture showing marking for the harvest of reduced neo-clitoris based on the dorsal penile pedicle

The inverted glandular end of the pedicled penile tube flap was closed with absorbable sutures. Two

stout sutures were passed through this closed end, and these were anchored to either pillar of

the levatores prostate close to the apex of the perineal body. Moreover, thus neovaginal pouch was created [Figures 8 and 9].

When the neovaginal pouch was created, the proximal unfurled penile skin was automatically drawn and applied over neo-clitoridis and corpus spongiosal stump. Carefully dissecting on any one side of the superficial dorsal vein of the penis (These ports are created on one side of superficial dorsal vein of penis and superficial external pudendal vessels which travel in the midline which are the pedicle for the inverted penile flap. Therefore, the pedicle has to be protected during the port creation. Failure to do so may precipitate necrosis of the neovaginal vault, without causing injury to the pedicle, two ports were created, one for the delivery of the neo-clitoridis proximally and the other for the creation of neo-external urethral meatus (inferior to the neo-clitoridis). Through the inferior

port, which was a vertical slit of size 1.75 cm on an average incorporating two triangular flap of penile skin the corpus spongiosum/bulb stump was delivered [Figure 10]. 18F Foleys catheter was inserted, and the bulb was inflated to retain it in position. The stump was obliquely divided to create a large circumference, flush with the draped penile skin [Figure 11]. The stump was spatulated at 12 o'clock and 6 o'clock positions to receive the triangular flap [Figure 10]. The oblique division of the urethral stump and the triangular skin flap interdigitation prevents neo-external urethral meatal stenosis. The rest of the urethra was fixed to the skin by absorbable sutures through full thickness bites through the urethra and the skin.

Based on the superficial external pudendal vessel supply, anteriorly and superiorly based reduced

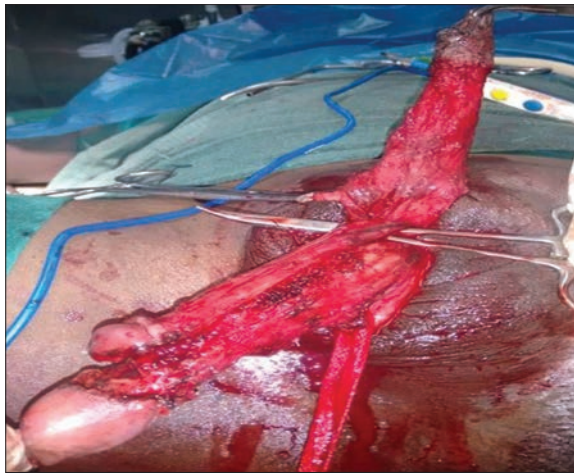


Figure 7: Intraoperative picture showing harvest of reduced glans clitoridis on the dorsal pedicle in progression

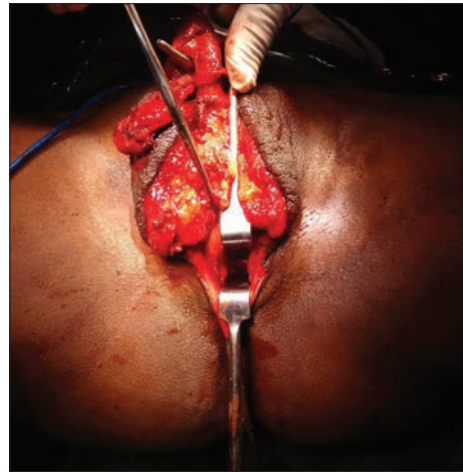


Figure 8: Intraoperative picture showing pocket creation by dissection through the perineal body for the neo-vagina

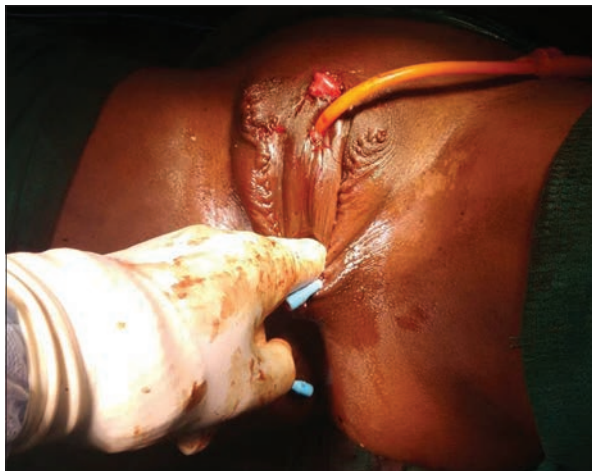

Figure 9: Intraoperative picture showing reconstructed neovaginal pouch, which is fixed to the levatores prostate at its apex

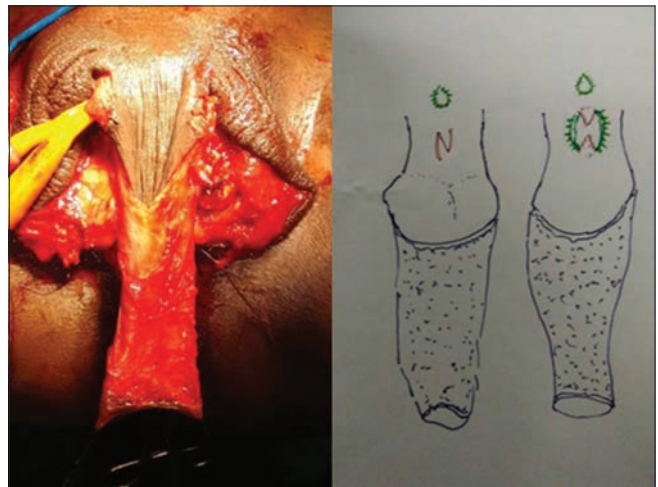


Figure 10: Intraoperative picture showing inverted penile flap just before neo-external urethroplasty (left). Schematic diagram showing rising of triangular flaps in the proximal unfurled penile skin, which is to cover the introitus (intermediate) (Right) interdigitation of the triangular flaps at 12 and 6 o'clock position back cut in the neo-urethra

scrotal flaps are brought on to either side of the folded penile skin to create the labia minora folds and the introitus. Apices of the reduced scrotal flaps were sutured to the inverted penile skin tube from 3 to 9 o'clock, through the 6 o'clock position. The inverted unmarred vaginal skin formed the 3–9 o'clock through the 12 o'clock opening of the neovagina. In addition, medialising penile skin provides hood for the neo clitoris [Figure 12]. Perfect hemostasis was secured. Few Segmullar drains were kept in the suture lines [Figure 13]. Cottony fluffy supporting T-Bandages were applied. Custom-made finger glove stuffed with wet cotton was used to splint the neovagina for the initial 5 days only. This was followed by regular saline washes and repeated splinting with custom-made splint from British dental compound for 21 days in toto. In unmarried transwomen were instructed to use custom-made splint for 3 months.

Bath and ambulation were allowed in the 3rd postoperative day. Short step gait, avoiding abduction was advised. Foley catheter was removed on the 10th day. They were discharged between days 10 and 14.

They were observed by two independent plastic surgeons at the end of 3, 6, and 12 months [Figure 14]. The follow-up period ranged from 9 to 25 months; the mean follow-up period is 17.5 months. Computations of functional and esthetic scores were done for each of them. Transwomen satisfaction was separately analyzed. The author's operative technique is essentially reverse embryogenesis explained in Table 2.

RESULTS AND OBSERVATIONS AT THE END OF FOLLOW-UP

All the transwomen [Table 1 and Graphs 1-4] were followed on an average of 18 months (endpoint of the study).

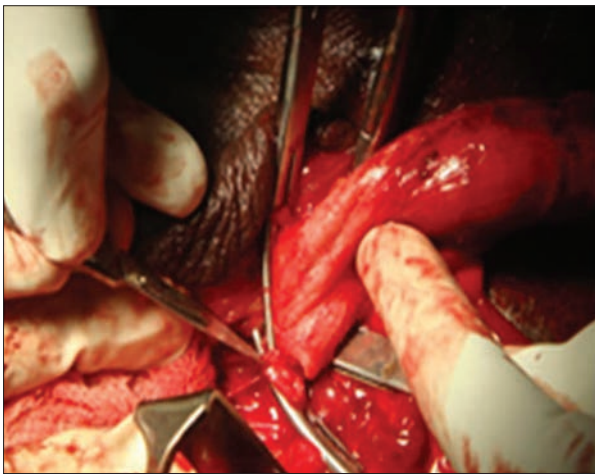


Figure 11: Intraoperative picture showing oblique division of the bulbar urethra after mobilization

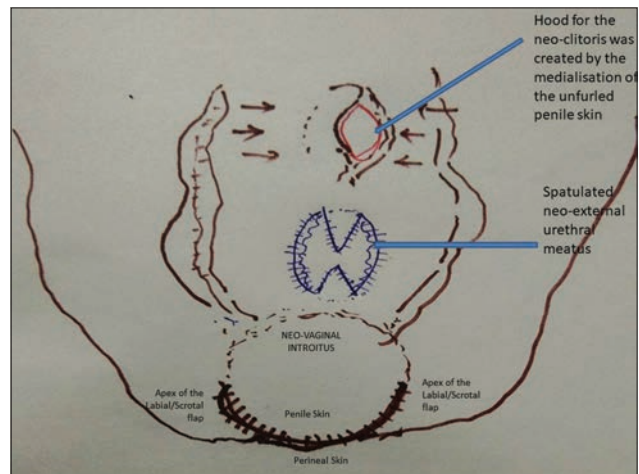


Figure 12: Schematic diagram showing the Author's technique of providing the hood to the neo-clitoris

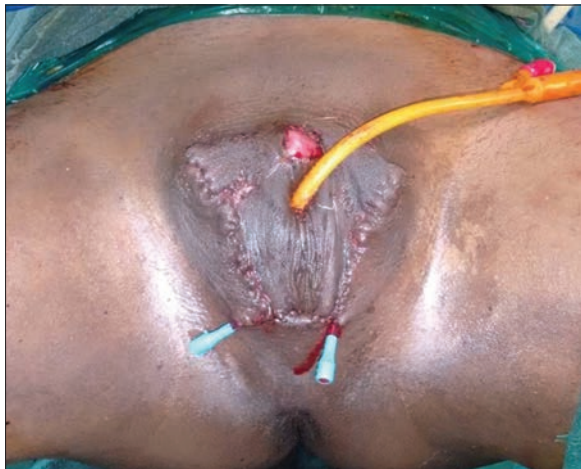

Figure 13: Immediate postoperative picture

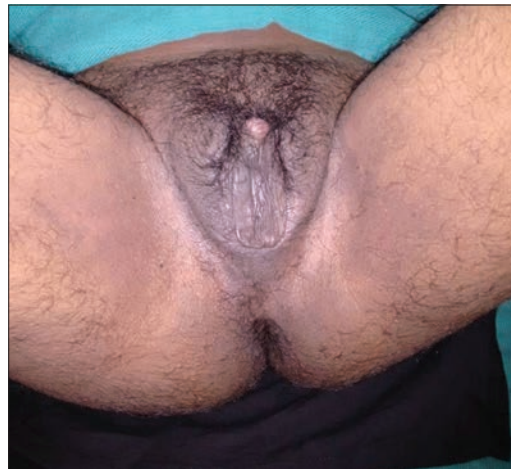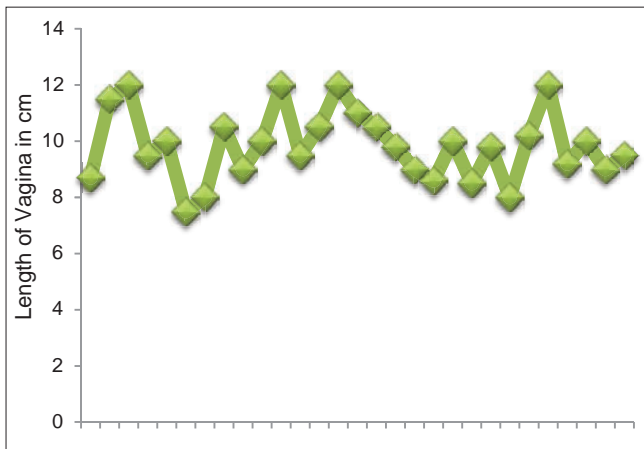


Figure 14: Late postoperative picture

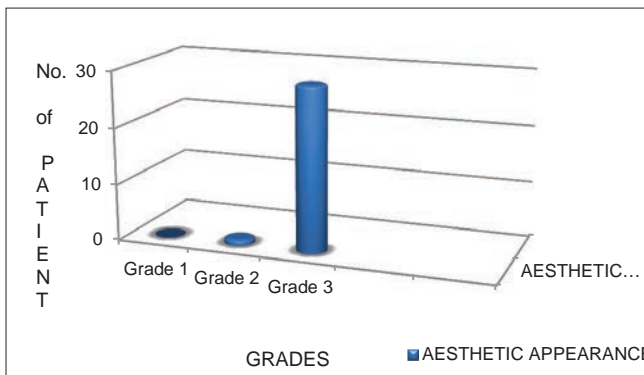
- The maximum length of neovagina created was 12 cm, with minimum being 7.5 cm with an average of 9.8 cm [Graph 1]
- The average vaginal introitus dimension was 2.75 cm
- Postoperative edema was universally seen in all cases, but it settled uneventfully. One transwoman had labio/scrotal flap excess deformity, and she underwent reduction surgery after 6 months. This was the only secondary procedure in our study. Mild infection and mild collection were encountered only in 2 transwomen (6.7%)
- These were managed conservatively
- No other complications were encountered.

Two independent plastic surgeons interviewed and assessed the transwomen at the end of the follow-up, and esthetic and functional scores were obtained from them [Table 1].

The esthetic outcome in 30 transwomen ranged from Grade 2: Intermediate result (one case) to Grade 3: Excellent score (in 29 cases). The average functional outcome in 30 transwomen was Grade 3 – excellent score.



Graph 1: Length of Neovagina in 30 transwomen



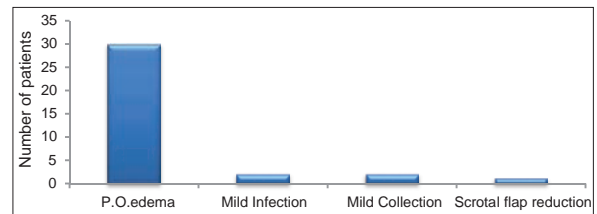
Graph 3: Aesthetic grading chart in thirty transwomen

Transwomen satisfaction assessment

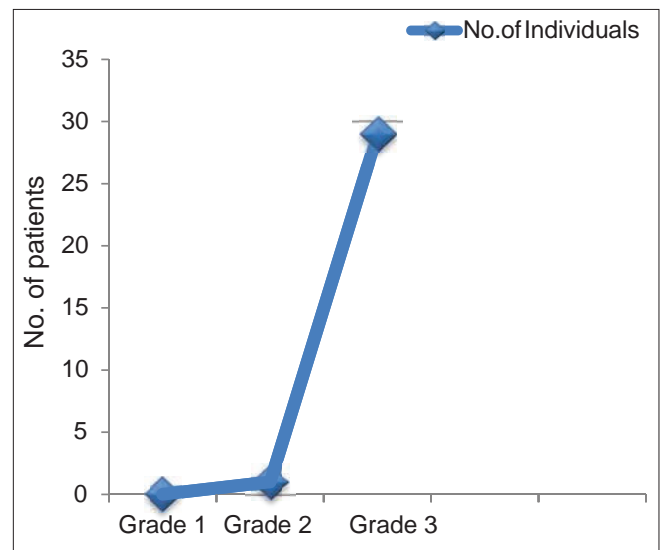
Satisfaction of transwomen with the appearance of the labia, vulva, clitoris, and sexual function was good to very good in 98% (5-point score from unsatisfactory, and poor to very good was used). The frequency of sexual activities increased significantly postoperatively for orogenital stimulation and decreased significantly for the frequency of anal intercourse ($t = -4.81$; $P < 0.001$). Orgasmic function was reported by 85% of participants. The psychological adjustment was good to very good, with low depression scores (another scoring given based on the leading questions to unearth clinical depressions). Sexual satisfaction was statistically and positively correlated with vaginal function and depth, clitoral sensation, appearance of the vulva and labia minora, and natural lubrication and negatively correlated with depression scores.

DISCUSSION

As affirmed by Karim^[11] the goal of genital reassignment surgery in male-to-female transsexuals is “to create a perineo-genital complex as feminine in appearance and



Graph 2: Post operative complications



Graph 4: Functional grading in thirty transwomen

function as possible which is free of poorly healed areas, scars, and neuromas.”

Vaginoplasty in transwomen is classified into the following five categories.

- a. Nongenital skin grafts
- b. Penile skin as graft
- c. Penile-scrotal skin flaps^[12]
- d. Nongenital skin flaps
- e. Pedicled intestinal transplant.

In 1931, Abraham reported that in his patient, penectomy was performed 9 years after castration.^[13] Subsequently, the lining of a neovagina was created with a skin graft draped inside-out over a sponge in accordance with the technique first published by Abbe^[14] and later popularized by McIndoe and Banister.^[15] In 1956, Fogh-Andersen was the first to report the use of a full-thickness skin graft harvested from the penile skin to line the neovagina.^[16] In 1957, Gillies and Millard reported the use of penile skin as a pedicled flap for vaginoplasty.^[17]

Modifications developed can be classified into the following three groups:

- The inverted penile skin with a small triangular scrotal skin flaps to “break” the circular introitus^[18]
- The pedicled penile skin tube may be split open to form a rectangular flap, posteriorly pedicled scrotal skin flap^[19]
- The inverted penile skin tube may be applied based on an inferior pedicle.^[20]

These flaps demonstrated lesser tendency to contract; were covered with vascularized tissue; local innervation is provided; and the flap is virtually hairless.

The author utilized the unfurled proximal pedicled penile flap for introitus covering as well as its distal inverted portion was used as a stable lining for the well-vascularized wall bound space created at perineal body level (neovagina). Author technique of mesializing the unfurling proximal pedicled penile flap skin provides the hood for neoclitoris, overcomes the exposed clitoris problem mentioned by Bouman,^[18] Jones *et al.*,^[19] Edgerton and Bull^[20] (due to paucity of penile skin) [Figures 12 and 14]. In 1980, Cairns and de Villiers reported the use of a medial thigh flap for vaginoplasties in four transsexuals who had previously undergone penile skin inversion vaginoplasty with the inadequate result.^[21] Huang^[22] used two inguinopudendal flaps. The inverted

penile tube flap provides a sufficient length of neovagina in all the transwomen in this study group. The first reported use of an intestinal transplant for vaginoplasty in a nontranssexual patient was provided by Sneguireff^[23] in 1892 using the rectum and Baldwin^[24] in 1904 using the ileum. However, the technique of colocolpoplasty was first used in transsexuals only in 1974, when Markland and Hastings used both cecum and sigmoid transplants.^[25] However, these intestinal transplants were associated with high amounts of troublesome discharge and mucosal prolapse. Though the well-vascularized inverted penile pedicled flap does not have secretions, which envisage lubrication, these were not pronounced as a concern of transwomen in this study. Author technique of neovagina with pedicled distal inverted penile tube flap was capacious enough repudiating the need for any augmentation with depilated scrotal flap.^[19] A natural-appearing clitoris with maintained erogenous sensation is the ultimate surgical aim. Neoclitoroplasty techniques described in literature were of two types: (a) pedicled flap neoclitoroplasty and (b) inert full thickness graft neoclitoroplasty. The penile skin is dissected off the erectile corporal tissue. Surgically the urethra and glans are gently lifted from the corpus cavernosum; the neurovascular bundles are skeletonized, the glans can be inset, with care taken not to kink the neurovascular bundle. A high rate of erogenous sensibility is maintained with this technique. Karim^[26] reported that 57 of 59 patients retained erogenous sensibility, of this 47 were able to reach orgasm. Edgerton *et al.*^[27] and later Marten-Perolino *et al.*^[28] suggested preserving all the glans penis and the neurovascular bundle with the overlying penis cutis placed at the bottom of the neovagina. Malloy *et al.* used the glans to form a substitute of uterine cervix.^[29] Meyer and Kesselring in 1980 used a small bud of corpus spongiosum covered by penile skin.^[30] Rubin used corpus spongiosum as vascular pedicle for constructing the neoclitoris, but urine leakage was a complication.^[31-34] Hage *et al.* made a neoclitoris from the glans and sculptured its final appearance during vaginoplasty using a free composite graft of the tip of the penile glans to cover the shortened dorsal neurovascular bundle.^[35] Since 1992, the use of a small dorsal portion of the glans with preservation of the dorsal penile neurovascular bundle has become the standard procedure for clitoroplasty in male to female sex reassignment.^[33,34] This technique was first described by Hinderer.^[36,37] Brown applied the same technique later.^[38] Many alternative techniques for the configuration of a neoclitoris have been proposed including the use of a preputial flap.^[39]

Author's anatomically conceived technique for pedicled flap neoclitoroplasty was not only reverse embryogenesis but also based on the anastomosis between deep artery and dorsal artery of penis at the coronal glandis.^[10] By this, the neo-clitoris, which was mounted on the conjoint crural mount, provides good projection of clitoris and complete sensation reinforced with full erogenic capacity (refer surgical technique). Author's technique of inverted penile flap provided intact skin bound vaginal introitus between 3 and 9 o'clock through 12 o'clock. The confluence of labial/scrotal flaps, perineal skin and cut proximal end of pedicled penile flap formed the suture line from 3 to 9 o'clock position through 6 o'clock. This reduces the scar contracture of the vaginal introitus. The expanded full preputial skin provides adequate boxy expansion at the apex of neo-vagina. The author observed gross reduction of scrotum to form a triangular superiorly based scrotal/labial flap provided esthetic fourchette.

An average 9.8 cm neovagina was created in our transwomen population [Table 1]. When compared to the study of Amend *et al.*^[40] where neovaginas of length 11 cm have been created on an average, among the German population, this may be of mildly reduced length. This was because the anthropometry of the Asian population and average body mass index of transwomen in our study was 23.5 with most of them having an android pelvis. This is the best possible length that could be created in our transwomen population. with 95% of satisfaction of the serviced vagina stands as an evidence for this. External urethral meatus stenosis was nil in our series. This is attributed to the author's technique of oblique division of the stump and interdigitation of the triangular flaps. There is 96% overall esthetic satisfaction of external appearance of the genitalia. This stands evidence for the success of the reverse embryonic approach-MTFEEbSRS that we have followed in this study. The erectile and sensate neo-clitoral flap and sensate inverted penile tubular flap in our cases add to the satisfaction of our transwomen. All 360° well-vascularized penile skin tubular flaps easily adhere to the tunnel created establishing a stable neovagina, which needs only 3 weeks of initial splinting. They are advised to have vaginal intercourse after 3 weeks. Karim *et al.*^[41] in their study advised about trimming and reduction of bulb (as it may cause the erogenic impingement on the vaginal introitus during intercourse), but what the author found out was excising the bulbospongiosus muscle alone radically had the same effect and can be executed without any bloody

dissection of bulb. Therefore, less need for prolonged splinting, more stable vagina creation, sensate introitus, and neo clitoris adds to the more satisfactory outcome, appreciated by all our transwomen.

The wide neo-external urethral meatus, which was created through a vertical slit, facilitate patients' squatting urination. Moreover, this resulted in extreme relief of their anxiety to have a feminine type of micturition. This also added to a more satisfactory score attained in our series. Fifteen out of 30 patients (50%) in our series were retroviral positive cases undergoing treatment for their disease. We have followed universal precautions for all our patients, during the operative and postoperative follow up. Due to our selection criteria to take transwomen with Cd4+ count >400 cell/mm³ none of our patients had wound failure and troublesome invasive infection in the postoperative period. All 30 transwomen expressed satisfactory coitus with little lubrication. None of them required any secondary procedures except for one transwoman who required reduction of labia; rest of them did not require any secondary procedure. Even though they were on hormone therapy, none of them developed complications such as deep vein thrombosis and pulmonary embolism, probably because of preoperative screening of coagulation profile (which was normal in all cases) and early ambulation in the postoperative period.

The "final endpoints" of genital reassignment surgery in male-to-female transsexuals are:

- To create a perineo-genital complex feminine in appearance and function. It should also be free of poorly healed areas, scars, and painful neuromas. All the transwoman in the study had an average grade 3 score [Table 1]
- The urethra should be shortened in such a way that the direction of the urinary stream is downward in the squatting position and it should be free from stenosis or fistulas. All transwoman in our study achieved this endpoint
- The neovagina should ideally be lined with moist, elastic, and hairless epithelium. All had serviceable vagina
- Sensations should be sufficient to provide satisfactory erogenous stimulus during sexual intercourse. All transwoman in the study expressed the good sexual erogenous stimulation during intercourse
- Ideally, all these requirements should be met without major surgical intervention necessitating long and distressful postoperative treatment, and addressing

them should not create new lesions or donor area morbidity. Except for one patient who required the secondary reduction procedure for the labial excess all had achieved the desired results in one stage transforming surgery.

The above-mentioned goals were achieved by applying genitalia embryonic equivalents in the reconstruction of external genitalia of transwomen using inverted pedicled penile flap for neovaginal lining.

- Our technique of creating neourethrostomy by cutting the urethra short (about 0.5 cm in length from triangular ligament of perineum) and approximating the cut end through a slit hole created in the penile flap just inferior to the clitoral mount enabled the patient to direct the urinary stream downward in squatting position. A cut in corpus spongiosum with urethra was given in a slanting direction so that a wide circumference was available for creating neourethrostomy, thus avoiding urethral stenosis
- Creation of clitoral mount using proximal cut ends of both corpora cavernosa under the penile flap proximal to urethrostomy site and preservation of dorsal nerve of the penis while dissecting out filleted penile flap provided erogenous stimulus during intercourse.

CONCLUSION

Anatomically construed MTFEEbSRS in accordance with WPATH 2012,^[42] shaped and harmonized body according to the mind of transwomen with lasting comfort, reinforced with facilitated sexuality and function. Anatomical approach reinforced with embryological equivalent reconstruction paved the way for good results. Although our size of our study is small in size, it may serve as a useful armamentarium in sex reassignment surgery for male or female transsexuals. From our analysis, neovagina, which was reconstructed amidst erogenous tissue and erogenous clitoral mount, paved adequate sexual satisfaction. Near perfect looking neo-external genitalia with urethrostomy free from complications was obtained and this also helped the transwomen in their complete gender identification. Their personality, lifestyle, and self-esteem improved well.

Financial support and sponsorship

Nil.

Conflicts of interest

There are no conflicts of interest.

REFERENCES

1. World Professional Association for Transgender Health. The Standards of Care for Health of Transsexual, Transgender, Gender-Nonconforming People 7th version. New York World Professional Association for Transgender Health: 2012.
2. Kaufman D, Maasdam JV, Laub DR. Plastic surgery. In: Stephen J, editor. *Mathes-Surgery for Gender Identity Disorder*. 2nd ed., Ch. 156 Philadelphia Saunders Elsevier; 2006. p. 1305-16.
3. Benjamin H. The transsexual phenomenon. *Trans N Y Acad Sci New York* 1967;29 (4 seriesII) 428-430 [Doi: 10.1111/j.2164-0947.1967.tb02273.x].
4. Fisk NM. Gender dysphoria syndrome (the how, what and why of a disease). In Laub DR, Gandy PP, editors. *Proceedings of the Secondary Interdisciplinary Symposium on Gender Dysphoria Syndrome*. Stanford, California: Division of Reconstructive and Rehabilitation Surgery, Stanford University Medical Center; 1973.
5. Robert L. Spitzer. *Diagnostic and Statistical Manual of Mental Disorders*. 3rd ed. Washington, D.C: American Psychiatric Association; 1980.
6. Meerwijk EL, Sevelius JM. Transgender population size in the United States: A Meta-regression of population-based probability samples. *Am J Public Health* 2017;107:e1-8.
7. Gupta R, Murarka A. Treating transsexuals in India: History, prerequisites for surgery and legal issues. *Indian J Plast Surg* 2009;42:226-33.
8. Kruijver FP, Zhou JN, Pool CW, Hofman MA, Gooren LJ, Swaab DF, *et al.* Male-to-female transsexuals have female neuron numbers in a limbic nucleus. *J Clin Endocrinol Metab* 2000;85:2034-41.
9. Chung WC, De Vries GJ, Swaab DF. Sexual differentiation of the bed nucleus of the stria terminalis in humans may extend into adulthood. *J Neurosci* 2002;22:1027-33.
10. McMinn RM. *Last's Anatomy Regional and Applied*. 9th ed. Edinburgh Churchill Livingstone; 1994. p. 408-10.
11. Karim RB, Hage JJ, Mulder JW. Neovaginoplasty in male transsexuals: Review of surgical techniques and recommendations regarding eligibility. *Ann Plast Surg* 1996;37:669-75.
12. McGregor IA. *Fundamental Techniques of Plastic Surgery and Their Surgical Applications*. 8th ed. Edinburgh: Churchill Livingstone; 1989. p. 39-63.
13. Abraham F. *Genitalumwandlung an zwei männlichen Transvestiten*. *Sexwiss Sexpol* 1931;18:223.
14. Abbe R. New method of creating a vagina in a case of congenital absence. *Med Rec* 1898;54:836.
15. McIndoe AH, Banister JB. An operation for the cure of congenital absence of vagina. *J Obstet Gynaecol* 1938;45:490.
16. Fogh-Andersen P. Transsexualism, an attempt at surgical management. *Scand J Plast Reconstr Surg* 1969;3:61-4.
17. Gillies H, Millard RD Jr. *Genitalia. The Principles of Art of Plastic Surgery*. London: Butterworth; 1957. p. 368-88.
18. Bouman FG. Sex reassignment surgery in male to female transsexuals. *Ann Plast Surg* 1988;21:526-31.
19. Jones HW Jr., Schirmer HK, Hoopes JE. A sex conversion operation for males with transsexualism. *Am J Obstet Gynecol* 1968;100:101-9.
20. Edgerton MT, Bull J. Surgical construction of the vagina and labia in male transsexuals. *Plast Reconstr Surg* 1970;46:529-39.
21. Cairns TS, de Villiers W. Vaginoplasty. *S Afr Med J* 1980;57:50-5.
22. Ettner R, Monstrey S, Coleman E. Huang pudendal flap. *Principles of Transgender Medicine and Surgery*. 2nd ed. (2016) New York; Routledge. p. 268.
23. Sneguireff WF. Zwei Falle von Restitutio Vaginae per Transplantationen. *Ani Recti Central Gynakol* 1904;28:772.

24. Baldwin JF. XIV. The formation of an artificial vagina by intestinal transplantation. *Ann Surg* 1904;40:398-403.
25. Selvaggi G, Ceulemans P, De Cuyper G, VanLanduyt K, Blondeel P, Hamdi M, *et al.* Gender identity disorder: General overview and surgical treatment for vaginoplasty in male-to-female transsexuals. *Plast Reconstr Surg* 2005;116:135e-145e.
26. Karim RB. *Vaginoplasty in Transsexuals*. Amsterdam: VU University Press; 1996.
27. Edgerton MT, Knorr NJ, Callison JR. The surgical treatment of transsexual patients: Limitations and indications. *Plast Reconstr Surg* 1970;45:38-44.
28. Marten-Perolino R, Cocimano V, Marino G. Male-female transsexualization with glandular preservation. *Arch Ital Urol Nefrol Androl* 1990;62:101-5.
29. Malloy TR, Noone RB, Morgan AJ. Experience with the 1-stage surgical approach for constructing female genitalia in male transsexuals. *J Urol* 1976;116:335-7.
30. Meyer R, Kesselring UK. One-stage reconstruction of the vagina with penile skin as an island flap in male transsexuals. *Plast Reconstr Surg* 1980;66:401-6.
31. Rubin SO. A method of preserving the glans penis as a clitoris in sex conversion operations in male transsexuals. *Scand J Urol Nephrol* 1980;14:215-7.
32. von Szalay L. Construction of a neo-clitoris in male-to-female transsexuals. *Handchir Mikrochir Plast Chir* 1990;22:277-8.
33. Fang RH, Chen CF, Ma S. A new method for clitoroplasty in male-to-female sex reassignment surgery. *Plast Reconstr Surg* 1992;89:679-82.
34. Eldh J. Construction of a neovagina with preservation of the glans penis as a clitoris in male transsexuals. *Plast Reconstr Surg* 1993;91:895-900.
35. Hage JJ, Karim RB, Bloem JJ, Suliman HM, van Alphen M. Sculpturing the neoclitoris in vaginoplasty for male-to-female transsexuals. *Plast Reconstr Surg* 1994;93:358-64.
36. Hinderer UT. Aesthetic plastic correction of incomplete testicular feminization. *Aesthetic Plast Surg* 1979;3:201-17.
37. Hinderer UT. Reconstruction of the external genitalia in the adrenogenital syndrome by means of a personal one-stage procedure. *Plast Reconstr Surg* 1989;84:325-37.
38. Brown J. Creation of a functional clitoris and aesthetically pleasing introitus in sex conversion. In: Marchac D, Hueston JT, editors. *Transactions of the Sixth International Congress of Plastic and Reconstructive Surgery*. Paris: Masson; 1976. p. 654.
39. Mollard P, Juskiwenski S, Sarkissian J. Clitoroplasty in intersex: A new technique. *Br J Urol* 1981;53:371-3.
40. Amend B, Seibold J, Toomey P, Stenzl A, Sievert KD. Surgical reconstruction for male-to-female sex reassignment. *Eur Urol* 2013;64:141-9.
41. Karim RB, Hage JJ, Bouman FG, Dekker JJ. The importance of near total resection of the corpus spongiosum and total resection of the corpora cavernosa in the surgery of male to female transsexuals. *Ann Plast Surg* 1991;26:554-6.
42. Neligan PC. *Plastic surgery: Lower extremity trunk and burns*. In: Loren S, Song DH, editors. *Schechter Surgery for Gender Dysphoria*. 4th ed., Vol. 4. London: Elsevier Inc.; 2018. p. 33.