

## Original Article

# First two bilateral hand transplantations in India (Part 2): Technical details

Mohit Sharma, Subramania Iyer<sup>1</sup>, Kishore P, Jimmy Mathew, Raghuveer Reddy, Janarthanan Ramu, Sundeep Vijayaraghavan, Abhijeet Wakure, Chetan Mali S M, Visakh Varma, Ashish Chaudhari, Swapnil Dhake, Akshay Omkumar, Jerry Paul<sup>2</sup>, Sunil Rajan<sup>2</sup>, Ayyappan Nair<sup>3</sup>, Druvan Shaji<sup>3</sup>

Departments of Plastic and Reconstructive Surgery, <sup>1</sup>Anaesthesiology, <sup>2</sup>Critical Care and <sup>3</sup>Orthopaedics, Amrita Institute of Medical Sciences, Kochi, Kerala, India

**Address for correspondence:** Prof. Subramania Iyer, Department of Plastic and Reconstructive Surgery/Head and Neck Surgery/Cranio-Maxillofacial Surgery, Amrita Institute of Medical Sciences, Tower 1, 4<sup>th</sup> Floor, AIMS Ponekkara P.O., Kochi - 682 041, Kerala, India. E-mail: [subu.amrita@gmail.com](mailto:subu.amrita@gmail.com)

## ABSTRACT

**Introduction:** This article deals with two patients who underwent bilateral hand transplantation following amputation of both upper limbs at the distal third of the forearm. **Materials and Methods:** The first patient had a history of loss of hands in a train accident, with possibility of a run over element during the injury. The second patient lost his both hands in a mine blast. The preoperative work up included detailed clinical and psychological evaluation. The donor retrieval was similar in both the cases and the donors were housed in our own institution. The donor preparation, recipient preparation and the transplant procedure was similar except for the need of primary tendon transfers in the left hand of the first patient. **Results:** The first patient needed a free flap transfer to cover compromised skin flap on the left hand on the second day. The second hand transplant was uneventful. Both the recipients are now back to their normal daily routines. **Conclusions:** Hand transplantation is a potentially life altering procedure, but to optimise the results, it is imperative that there is a meticulous planning and diligent execution with utmost importance to the detail coupled with a synchronised team effort.

## KEY WORDS

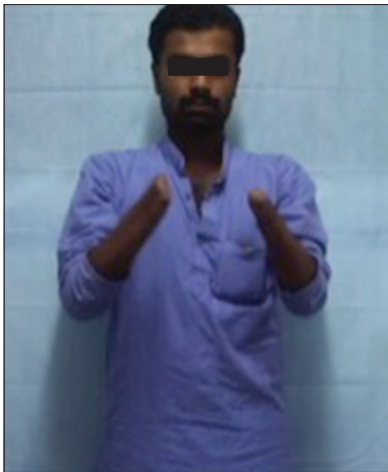Composite tissue allotransplantation; hand transplantation; technical details; vascular composite tissue allotransplantation

Access this article online	
Quick Response Code: 	Website: <a href="http://www.ijps.org">www.ijps.org</a>
	DOI: 10.4103/ijps.IJPS_94_17

This is an open access article distributed under the terms of the Creative Commons Attribution-NonCommercial-ShareAlike 3.0 License, which allows others to remix, tweak, and build upon the work non-commercially, as long as the author is credited and the new creations are licensed under the identical terms.

**For reprints contact:** [reprints@medknow.com](mailto:reprints@medknow.com)

**How to cite this article:** Sharma M, Iyer S, Kishore P, Mathew J, Reddy R, Ramu J, *et al.* First two bilateral hand transplantations in India (Part 2): Technical details. *Indian J Plast Surg* 2017;50:153-60.



**Figure 1:** Pre-operative photograph of our bilateral first hand transplant patient



**Figure 2:** Second bilateral hand transplant patient before the procedure

**Table 1: Details of pre-operative evaluation**

Details	Case 1	Case 2
<b>Recipient</b>		
Sex	Male	Male
Age	31 years	31 years
Blood group	A ve+	O ve+
Comorbidities	Nil	Nil
Cause of amputation	Traumatic amputation	Mine blast injury
Time since amputation	2 years	3 years
Dominant hand	Right	Right
Prior use of prosthesis	Not used	Yes, but not satisfied
Psychological evaluation	Stable	Stable
MRI	Not done	Done
CMV	Not done	Not done
EBV	Not done	Not done
<b>Matching</b>		
Lymphocyte crossmatch	Favourable (<10%)	Favourable (<10%)
HLA	Complete mismatch (0/6 allele positive)	Complete mismatch (0/6 allele positive)
PRA	Not done	Not done
DSA	Not done	Not done

MRI: Magnetic resonance imaging, CMV: Cytomegalovirus, EBV: Epstein-Barr virus, HLA: Human leukocyte antigen, PRA: Panel reactive antibody, DSA: Donor specific antibody

## PRE-TRANSPLANT ASSESSMENT AND WORK UP

Both the patients underwent an exhaustive pre-operative clinical, laboratory, radiological and psychiatric evaluation. The general details about the patients are provided in Table 1. Both were healthy young adults and had a post-amputation interval of >2 years [Figures 1 and 2]. Both had been suggested

to use prosthetic limbs and were not happy with it when they tried it. Both of them were right-handed dominant persons and were using their stumps to various activities, but living predominantly with the help of family members. The psychological evaluation showed both of them of stable personalities with realistic aspirations and expectations. The counselling by the social worker team revealed a stable and adequate family and social support for the prolonged rehabilitation as well as lifelong immunosuppression treatment. The immunology team after multiple counselling sessions with the patient and the family was comfortable with the level of understanding as well as the commitment from them regarding compliance to immunosuppression.

The second patient had some peculiar social issues to be dealt with. He and his family were from Afghanistan and knew neither the local language nor English. Hence, an interpreter's help was needed in the initial period to help in the counselling sessions. They could relocate to our city for a prolonged time in anticipation for the transplant as well as for the rehabilitation, at least for a year post-transplant. The other issue of concern was to have sustained follow-up for the immunosuppression and the rejection episodes if they occur after relocation to Afghanistan. This was solved by getting the help from a plastic surgeon located in Kabul, who offered to come and spend time with our team before the patient relocated after the transplant

The laboratory evaluations were for assessing the fitness for prolonged general anaesthesia and the presence of hepatitis and HIV infections. Radiological assessment for quality and length of the residual bone was made. MRI scan to assess the muscles and scarring was not done

**Table 2: The details of the donors**

<b>Donor details</b>	<b>Case 1</b>	<b>Case 2</b>
Sex	Male	Male
Age	24 years	52 years
Blood group	A ve+	O ve+
Comorbidities	Nil	Nil
CMV	IgG positive	Not done
EBV	Not done	Not done

CMV: Cytomegalovirus, EBV: Epstein–Barr virus

**Table 3: Selection criteria of donors for hand transplant in Indian scenario**

<b>Inclusion criteria</b>	<b>Exclusion criteria</b>
Essential	Age: <18 or >60 year old
Documented brain death	Congenital/traumatic upper extremity deformities
Haemodynamic stability	Connective tissue disorder
Blood group match	Peripheral neuropathy
Favourable lymphocyte cross matching	Cancer
Gender	Non-correctable acute traumatic injuries
Desirable	
Same race	
Size/skin tone	
Negative CMV/EBV screening	

CMV: Cytomegalovirus, EBV: Epstein–Barr virus

in the first case. However, the intra-operative finding of extensive scarring in the left forearm in the first case prompted us to do an MRI in the second patient. This along with assessment of cytomegalovirus/EpsteinBarr virus (CMV/EBV) status and pre-transplantation panel reactive antibody estimation has been added as routine work-up measures in the subsequent patients.

The donors had to fulfil the criteria that were needed for solid organ donation and some additional criteria specific for vascular composite tissue allotransplantation as shown in Tables 2 and 3.

They had to be of the same sex and blood group. The immunological screening and matching is given in detail in the next section.

## SURGICAL DETAILS

After the confirmation of the compatibility with the donor, the recipients were started off with the induction immuno-suppression in the anteroom after securing the arterial and central venous lines. Detailed description of this is given in the subsequent section.

The donor was admitted in the intensive care unit of the same hospital when they were declared brain dead, in both the cases. The first donor was 24-year-old male patient and

the second was 52-year-old male patient. Two teams each for the donor and recipient started off simultaneously.

As the hand transplant was being done for the first time, the other teams were explained about our procedure and taken into confidence that hand retrieval would not affect harvest of other organs and as we used tourniquets and we assured them that the patient would not become haemodynamically unstable. We suggested them to complete their exposure of abdomen, and then we retrieved the hand quickly which was followed by other solid organ retrieval. There were a total of five teams (two teams for donor hand retrieval, two teams for recipient side and one team on standby, each consisting of two surgeons and a scrub nurse)

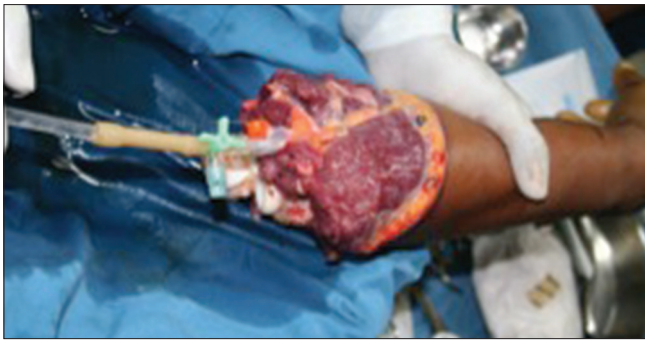The donor hands once procured were brought into the adjacent operating room and procedures carried out simultaneously. The recipient was given general anaesthesia. This was augmented with supraclavicular blocks for vasodilatation and post-operative analgesia.

## DONOR LIMB RETRIEVAL

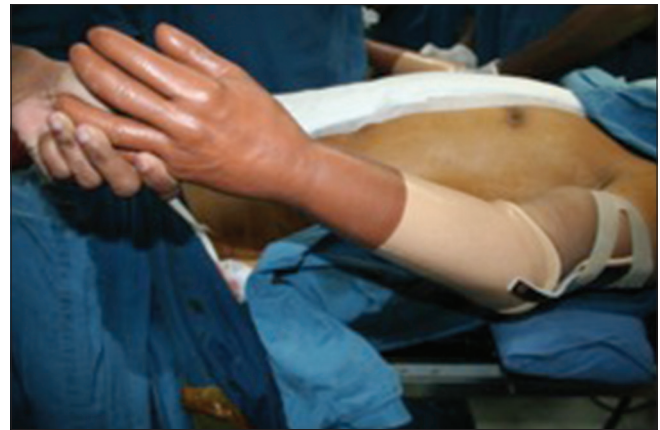Donor hands were harvested at the level of the elbow with a fish-mouth incision given below the elbow [Figure 3]. The brachial artery was identified, ligated proximally and cannulated distally for infusion. Cephalic and basilic veins were identified and divided. After infusion of 1 l of University of Wisconsin solution, the limbs were retrieved by disarticulating the forearm through the elbow joint. Wounds were closed and the prostheses attached to the amputated stumps [Figure 4]. The retrieved limbs were immediately placed in a tray with ice slush avoiding direct contact with the skin and transferred to the bench for preparation [Figure 5].

## DONOR LIMB PREPARATION

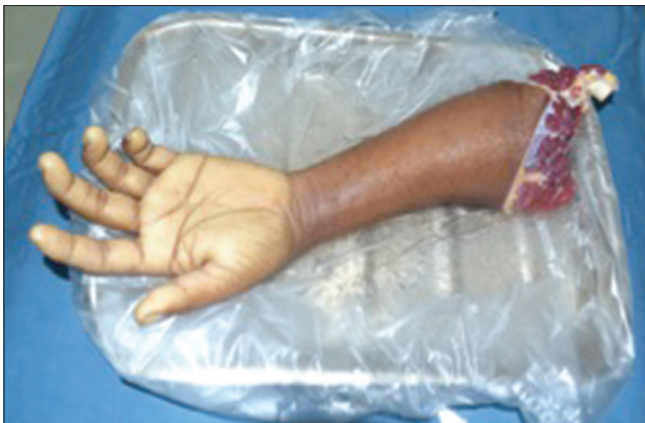The incisions were placed such that the flaps raised on both the donor and recipient limbs interdigitate to accommodate the post-operative oedema, to avoid constriction and scar contracture at the site of closure. The donor's forearms were given midaxial incisions on the extensor and flexor aspect with added carpal tunnel release to avoid compression neuropathy post-operatively. The skin flaps were raised preserving the skin perforators of the distal forearm on both the ulnar and radial aspects. All the structures were identified and tagged. Most of the muscles were excised leaving behind only the tendinous part to reduce the



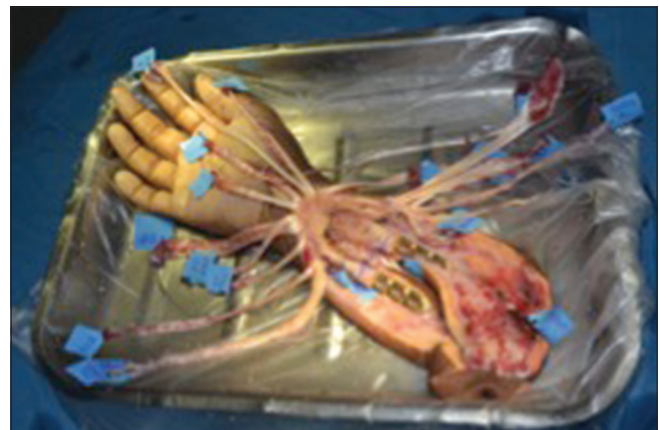**Figure 3:** Cannulated disarticulated forearm after infusion of University of Wisconsin solution



**Figure 4:** Donor limb after applying prosthesis



**Figure 5:** Donor forearm kept in ice slush



**Figure 6:** Donor limb ready for transplantation

muscle mass and the severity of reperfusion injury. Aggressive periosteal stripping was avoided, and the bones were plated with 3.5 mm locking compression plates [Figure 6]. In our first donor, there was an open dislocation of proximal interphalangeal joint of the middle finger of the right hand which was reduced, and the laceration was sutured.

### RECIPIENT LIMB PREPARATION

The superficial veins were marked under venous tourniquet control using low pressure (100 mm of Hg) without exsanguination [Figure 7]. Once the vein marking was done, the tourniquet was deflated and then reinflated after exsanguination with the pressure at 250 mm of Hg. Mid lateral incisions were given and the skin flaps were raised on dorsal and volar aspects. All the available musculotendinous units and neurovascular structures were identified, tagged and the missing structures noted [Figure 8]. The sequence of repair was bone, one artery, one venae comitantes, one superficial vein, all extensor tendons, all flexor tendons, another artery, venae comitantes, superficial veins, all the nerves and skin.

### BONE FIXATION

The bones were fixed with 3.5 mm locking compression plates with 3 holes on each side while maintaining an ideal forearm length, matching the width of the bone for proper congruence and retaining a minimum length of 5 cm of the bone in the donor's hand for plating [Figure 9]. Plating was done on volar aspect in the first patient and on the dorsal aspect in the second patient [Table 4].

### VASCULAR ANASTOMOSIS

Radial artery, one venae comitantes and one superficial vein were anastomosed immediately after bone fixation to reduce the total ischaemia time. The ulnar artery, one venae comitantes, and one superficial vein were anastomosed after completing the extensor tendon repairs [Table 5]. In our first case, reestablishment of vascularisation did not occur after the radial artery anastomosis probably due to the arterial line inserted in the radial artery of donor

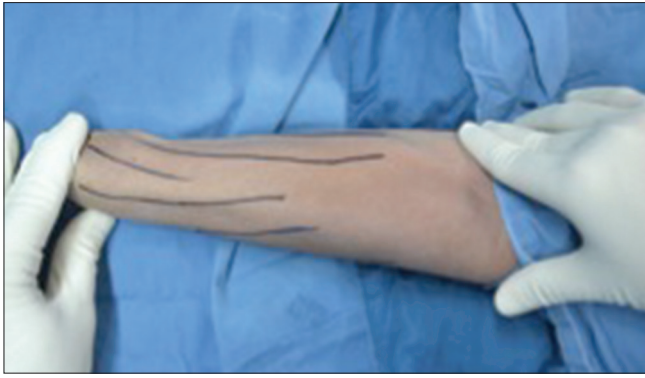

Figure 7: Marking of superficial veins

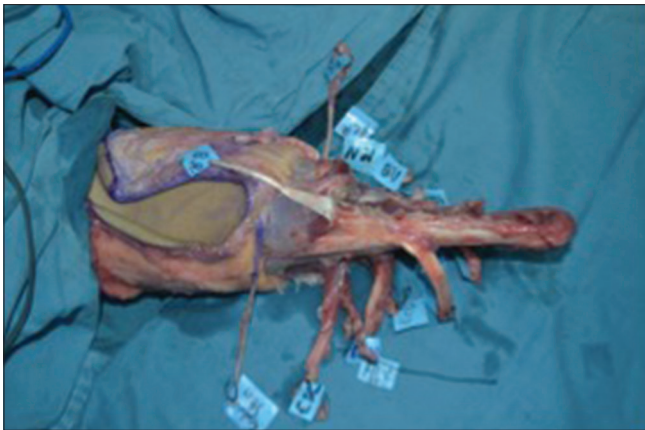


Figure 8: Identification and tagging of available musculotendinous and neurovascular structures

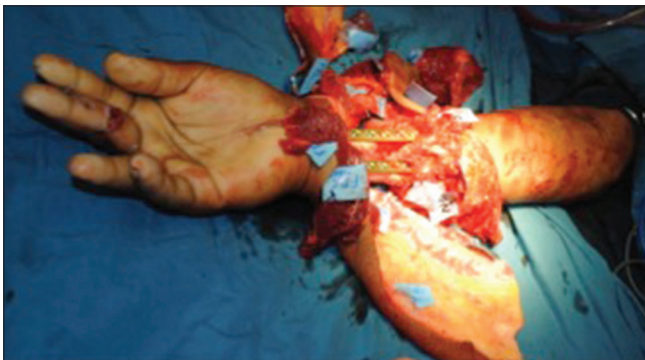

Figure 9: Bone fixation with 3.5 mm locking compression plate

hand. Hence, the ulnar artery had to be anastomosed immediately, which re-established the vascularity of the limb. In our second case, on the left hand, the ulnar artery was anastomosed first to avoid a similar situation.

### TENDON REPAIR

The tendon repairs were carried out by Pulvertaft weave technique. The extensor repairs were done such that with the wrist is in 20° flexion, the fingers achieved full extension.<sup>[1]</sup> On the flexor aspect, the

Table 4: Bone length details

Bone parameter details	Case 1		Case 2	
	Right	Left	Right	Left
Available forearm bone length in recipient (cm)	29	25	25	20
Bone shortening in recipient forearm bone (cm) (planned shortening)	5	2	5	2
Donor forearm bone length (cm) (planned length)	5	6	7	9
Total forearm length achieved (cm)*	29	31	27	27

\*On account of an executional discrepancy there was a 2 cm length difference between the two limbs in the first case

Table 5: Details of the vascular anastomoses

Vessels anastomosed	Case 1		Case 2	
	Right	Left	Right	Left
Artery	Radial artery	Radial artery	Radial artery	Ulnar artery
	Ulnar artery	Ulnar artery	Ulnar artery	Radial artery
VC	One radial VC	Two radial VC	One radial VC	Two radial VC
	One ulnar VC	One ulnar VC	Two ulnar VC	Two ulnar VC
Superficial vein	Cephalic vein	Cephalic vein	Cephalic vein	Cephalic vein
	Basilic vein	One additional vein		

VC: Venae comitantes

tension was adjusted such that a normally graded finger flexion cascade was achieved.<sup>[1]</sup> Tendon transfers were performed to tackle the problem of absent tendons in the recipient limbs on account of the prior trauma and debridements [Table 6].

### NERVE COAPTATION

As both of our patients had transplantation at distal forearm level, the median nerve, ulnar nerve and superficial branch of the radial nerve were co-apted with epineural sutures and reinforced with tissue glue after revascularisation and tendon repairs.

### WOUND CLOSURE

The skin flaps on both the donor and recipient limbs were interdigitated to give a loose wound closure in a single layer over suction drains (16Fr) after trimming the excess flap on the donor limb [Figure 10] In our first case, since the skin flap on the ulnar aspect of left recipient hand was showing signs of venous congestion at the time of wound closure, a vein draining the flap was anastomosed to a superficial vein. Skin graft was harvested from the excess skin flaps of the donor's forearm and was used to

**Table 6: Details of tendon availability and tendon transfers**

Tendon details	Case 1		Case 2	
	Right	Left	Right	Left
Tendons missing	None	Flexors - FDP, FPL, FCR, FCU Extensors - EPL, EPB, EIP, EDM, ECRL, ECRB and ECU	None	None
Flexor tendon transfers	None	PL to APL, FDS (1) to FPL, FDS (2, 3, 4) to FDP (1, 2, 3, 4)	None	None
Extensor tendon transfers	None	APL to ECRB, EDC to EDC, BR to EPL	BR to EPL	None

FDP: Flexor digitorum profundus, FPL: Flexor pollicis longus, FCR: Flexor carpi radialis, FCU: Flexor carpi ulnaris, EPL: Extensor pollicis longus, EPB: Extensor pollicis brevis, EIP: Extensor indicis proprius, EDM: Extensor digiti minimi, ECRL: Extensor carpi radialis longus, ECRB: Extensor carpi radialis brevis, ECU: Extensor carpi ulnaris, PL: Palmaris longus, APL: Abductor pollicis longus, EDC: Extensor digitorum communis, BR: Brachioradialis, FDS: Flexor digitorum superficialis

**Table 7: Ischaemia times**

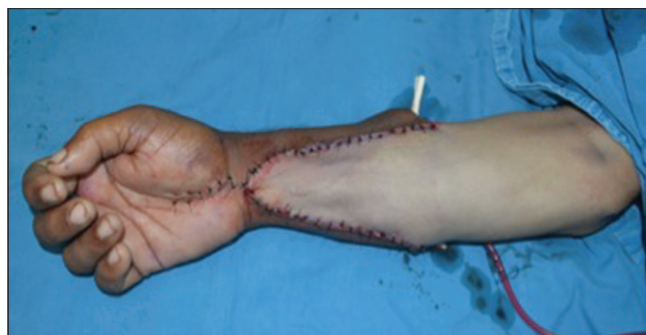
Ischaemia time	Case 1		Case 2	
	Right	Left	Right	Left
Warm ischaemia time	20 min	24 min	28 min	15 min
Cold ischaemia time	5 h	5 h	5 h	5 h
	20 min	40 min	17 min	30 min

cover a small raw area over the distal forearm over the flexor aspect.

### ISCHAEMIA TIMES

Warm ischaemia time is the time from clamping the brachial artery to completion of infusion of University Wisconsin solution, 1 l for each hand. Cold ischaemia time is the period between post-perfusion of cold preservative (UW solution) till revascularisation of the hand.

The first transplantation lasted for 17 h and the second for 16 h [Table 7]. The intraoperative period was uneventful in both the patients except for the blood loss and need for volume replacement. The first patient was transfused with 5 units of blood and the second patient with 4 units of blood intraoperatively. Both the patients also received 3 units and 2 units, respectively, in their post-operative period. Post-operatively, they were shifted to the transplant ICU and electively extubated. In the first case, the ulnar skin flap of the left hand which had shown some intra-operative congestion started to show signs of congestion within the first 48 h [Figure 11]. It was decided that immediate debridement of the devitalised tissue and providing a cover for the same would be more prudent on account of the risk of infection an potential life-threatening sepsis in an already immune-suppressed patient. The patient was then taken up for excision of the devitalised tissue [Figure 12]. Moreover, re-surfacing of the raw area with an anterolateral thigh flap [Figure 13] under regional anaesthesia as the patient was just recovering from a major procedure under general anaesthesia. The anastomosis of the flap was done in the end to side



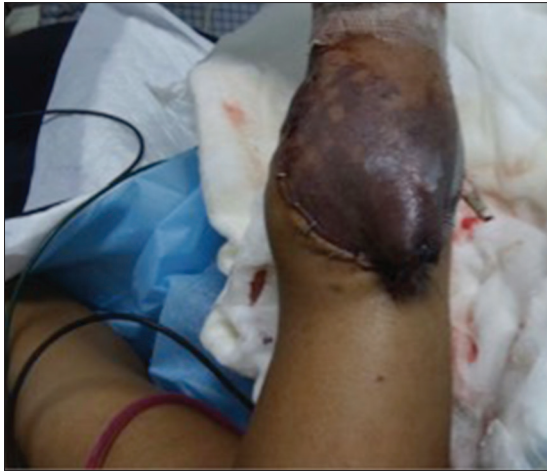**Figure 10:** Appearance after final closure

fashion to the radial artery and to the superficial vein on the flexor aspect of the forearm. The donor area on the thigh was closed primarily. Following that, the immediate post-operative period was uneventful. The further details of the post-operative phase, recovery and rehabilitation are detailed in the subsequent paper on recovery and rehabilitation in this issue of IJPS.

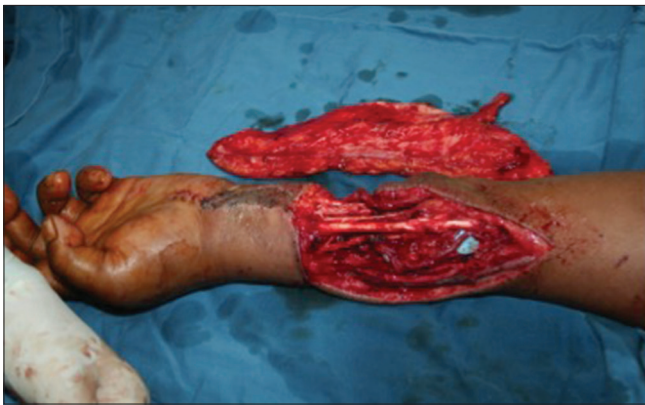### DISCUSSION

Race, size of the limb and skin tone was considered as non-essential criteria by us. Since our second case was from Afghanistan it almost impossible to find the same race. The size of the limb really does not matters as both of our patients underwent transplantation at distal forearm level. Colour matching of the skin was not ideal in the second transplant, but we proceeded with the transplant as the recipient was not bothered about the disparity in the colour.

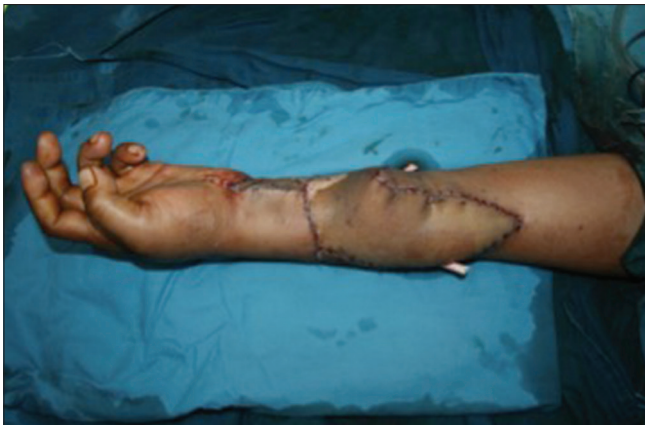The deleterious effect which is caused by the CMV in a transplant individuals includes opportunistic infection, acute or chronic rejection, allograft injury and post-transplant lymphoproliferative disorder.<sup>[2,3]</sup> Due to this, the ideal is donor negative for CMV status irrespective of the recipient status as the incidence of CMV in case of mismatch (donor +/-recipient-) is 50%–75% in solid organ transplantation. However



**Figure 11:** Congestion of the ulnar skin flap of left hand - 48 h post-operative



**Figure 12:** Defect after immediate debridement of the devitalised tissues and harvested anterolateral thigh flap



**Figure 13:** After resurfacing the defect with anterolateral thigh flap

in India considering the prevalence of CMV which is 80%–90%, and the scarcity of donors for hand transplant, it will be difficult task to get a negative donor if the recipient is also negative for CMV. Both of our patients were treated with prophylactic antiviral therapy with Ganciclovir.

Meticulous planning for the peri-operative, intra-operative and post-operative requirements is important for the successful execution of a hand transplantation. For a double hand transplant, at least four surgical teams are required, and a very good coordination between the teams is required.<sup>[4]</sup>

If the donor is present within the same hospital, the retrieval and recipient hand preparation could be done simultaneously in the adjacent operating theatres, but if the donor's hands are coming from a different hospital greater coordination is required between the organ retrieving team and the team preparing the recipient. Recipient preparation should start only after ascertaining the healthiness of the donor limbs and the time that will be needed for transport of the limbs to the recipient center. In case of donor multi-organ harvest, the priority should be given to harvest the life-saving organs, particularly in a hemodynamically unstable donor in the operating room.<sup>[4]</sup> However, in both of our cases, we were able to harvest the hands first after interacting with the solid organ harvest team as both of our donors were stable hemodynamically.

Apart from the need for immunosuppression, transplants have the merit of excess availability of the tissues, bone lengths which help in achieving an ideal relative tendon tension and an ideal limb length suitable for the recipient. In replantation, there may be lack of tissue for adequate tension free coaptation of nerves, vessels and particularly tendons necessitating bone shortening to salvage the limb.<sup>[5]</sup>

The sequence of repair may be tailored according to the collective wisdom of the team. The sequence we followed was-bone fixation, radial artery, its venae comitantes and one superficial vein, followed by the extensor tendons, flexor tendons, ulnar artery, one venae comitantes and one superficial vein and then finally the nerve repair. As there is very little muscle mass distal to distal one-third of forearm, it is possible to delay the vascular anastomosis in the transplant sequence.<sup>[6]</sup> However, various groups have their preferred sequences and rationale for the same.<sup>[1]</sup>

The blood loss requiring multiple transfusion of blood in both the patients were due to diffuse continuous oozing mostly from the donor limb after revascularisation and also from the recipient limb after tourniquet release. Since the donor limb is non-vascularised at the time of preparation, it may not be easy to identify the bleeding

areas, and hence, it is prudent to coagulate the tissues properly while dissecting which may reduce the number of blood transfusions.

Periosteal flaps may be left long to reinforce the osseous junctions. The second transplant patient underwent dorsal plating on insistence from our orthopaedician, but the radial plate appears to be impinging on the ulna restricting the supination and pronation, we would conclude that if the plating is performed accurately, there should be no problem with either volar or dorsal plating. In a significant number of cases, the radial artery of the donor may have been subjected to cannulation for arterial access in the post-traumatic period. In such a scenario, it may be prudent to anastomose the ulnar artery first to reperfuse the limb which will avoid prolongation in the ischaemia time. Post-operatively, patency of the radial artery was confirmed by Doppler scan.

## CONCLUSIONS

Hand transplantation is a potentially life altering procedure, but to optimise the results, it is imperative that there are a meticulous planning and diligent execution with utmost importance to the detail coupled with a synchronised team effort.

### Declaration of patient consent

The authors certify that they have obtained all appropriate patient consent forms. In the form the

patient(s) has/have given his/her/their consent for his/her/their images and other clinical information to be reported in the journal. The patients understand that their names and initials will not be published and due efforts will be made to conceal their identity, but anonymity cannot be guaranteed.

### Financial support and sponsorship

Nil.

### Conflicts of interest

There are no conflicts of interest.

## REFERENCES

1. Azari KK, Imbriglia JE, Goitz RJ, Shores JT, Balk ML, Brandacher G, *et al.* Technical aspects of the recipient operation in hand transplantation. *J Reconstr Microsurg* 2012;28:27-34.
2. Ho M. Immunology of cytomegalovirus: Immunosuppressive effects during infections. *Birth Defects Orig Artic Ser* 1984;20:131-47.
3. Margreiter R, Brandacher G, Ninkovic M, Steurer W, Kreczy A, Schneeberger S, *et al.* A double-hand transplant can be worth the effort! *Transplantation* 2002;74:85-90.
4. Datta N, Yersiz H, Kaldas F, Azari K. Procurement strategies for combined multiorgan and composite tissues for transplantation. *Curr Opin Organ Transplant* 2015;20:121-6.
5. Dubernard JM, Owen E, Herzberg G, Lanzetta M, Martin X, Kapila H, *et al.* Human hand allograft: Report on first 6 months. *Lancet* 1999;353:1315-20.
6. Schneeberger S, Ninkovic M, Gabl M, Ninkovic M, Hussl H, Rieger M, *et al.* First forearm transplantation: Outcome at 3 years. *Am J Transplant* 2007;7:1753-62.