

Congenital biotinidase deficiency - MRI findings in two cases

Rahul S Ranjan, Sunil Taneja¹, Anil Singh, Vikas Gupta²

Department of Radiodiagnosis, Rama Medical College, Mandhana, ¹Ex. Consultant at G. S. V. M. Medical College, ²Consultant Radiologist, Vikas Diagnostics, Kanpur, Uttar Pradesh, India

Correspondence: Dr. Rahul S Ranjan, Department of Radiodiagnosis, Rama Medical College, Mandhana, Kanpur - 209217, Uttar Pradesh, India. E-mail: rahulranjanradio10@gmail.com

Abstract

Congenital biotinidase deficiency is a rare inborn error of metabolism that most commonly presents in infantile age group. Diffusion changes on magnetic resonance imaging (MRI) are sparsely described in the literature. We are presenting diffusion-weighted MRI findings in two confirmed cases of congenital biotinidase deficiency in infantile age group with review of literature.

Key words: Biotinidase deficiency; developmental delay; neurometabolic disorder; seizures

Introduction

Congenital biotinidase deficiency is one of the rare congenital neurometabolic disorders with autosomal recessive inheritance. Early diagnosis is key to prevention of clinical manifestations including mental and physical developmental delay. These cases usually present in infantile age group with signs and symptoms which are common to multiple other inborn errors of metabolism. Therefore, magnetic resonance imaging (MRI) plays an important role in establishing the diagnosis which is confirmed by biochemical assay. Sporadic cases of congenital biotinidase deficiency have been reported in literature with most of reports showing brain atrophy and delayed myelination as imaging findings. Here, we are presenting MRI findings in two proven cases of biotinidase deficiency, including findings other than brain atrophy and delayed myelination.

Case 1

A 5-month-old male child, first born baby of consanguineous marriage, presented with failure to thrive, alopecia, and

multiple episodes of generalized tonic-clonic seizures. His milestones were delayed and neck holding was still absent. His routine blood investigations were within normal limit. MRI brain (noncontrast) was done which revealed extensive areas of restricted diffusion seen as hyperintensity on diffusion-weighted images (with increasing brightness on higher b-value) and low signal intensity on apparent diffusion coefficient, in bilateral cerebral white matter – in periventricular location extending along pyramidal tracts in bilateral cerebral peduncles [Figures 1A-C, 2, and 3]. There was involvement of central tegmental tracts, posterior limb of internal capsule, splenium of corpus callosum, and pyramidal tracts in brain stem [Figures 1A-C, 2, and 3]. Periventricular cerebellar white matter and middle cerebellar peduncles were also involved [Figure 2]. Medial temporal lobe, optic radiation, and parahippocampal region were also involved. Delayed myelination was noted with mild cerebral atrophy especially in bilateral frontal lobes. The areas of restricted diffusion revealed T2 and FLAIR hyperintense signal [Figure 1]. Based on these findings, possibility of inborn error of metabolism was raised and

This is an open access journal, and articles are distributed under the terms of the Creative Commons Attribution-NonCommercial-ShareAlike 4.0 License, which allows others to remix, tweak, and build upon the work non-commercially, as long as appropriate credit is given and the new creations are licensed under the identical terms.

For reprints contact: reprints@medknow.com

Cite this article as: Ranjan RS, Taneja S, Singh A, Gupta V. Congenital biotinidase deficiency – MRI findings in two cases. Indian J Radiol Imaging 2019;29:99-103.

Access this article online

Quick Response Code:



Website:
www.ijri.org

DOI:
10.4103/ijri.IJRI_159_18

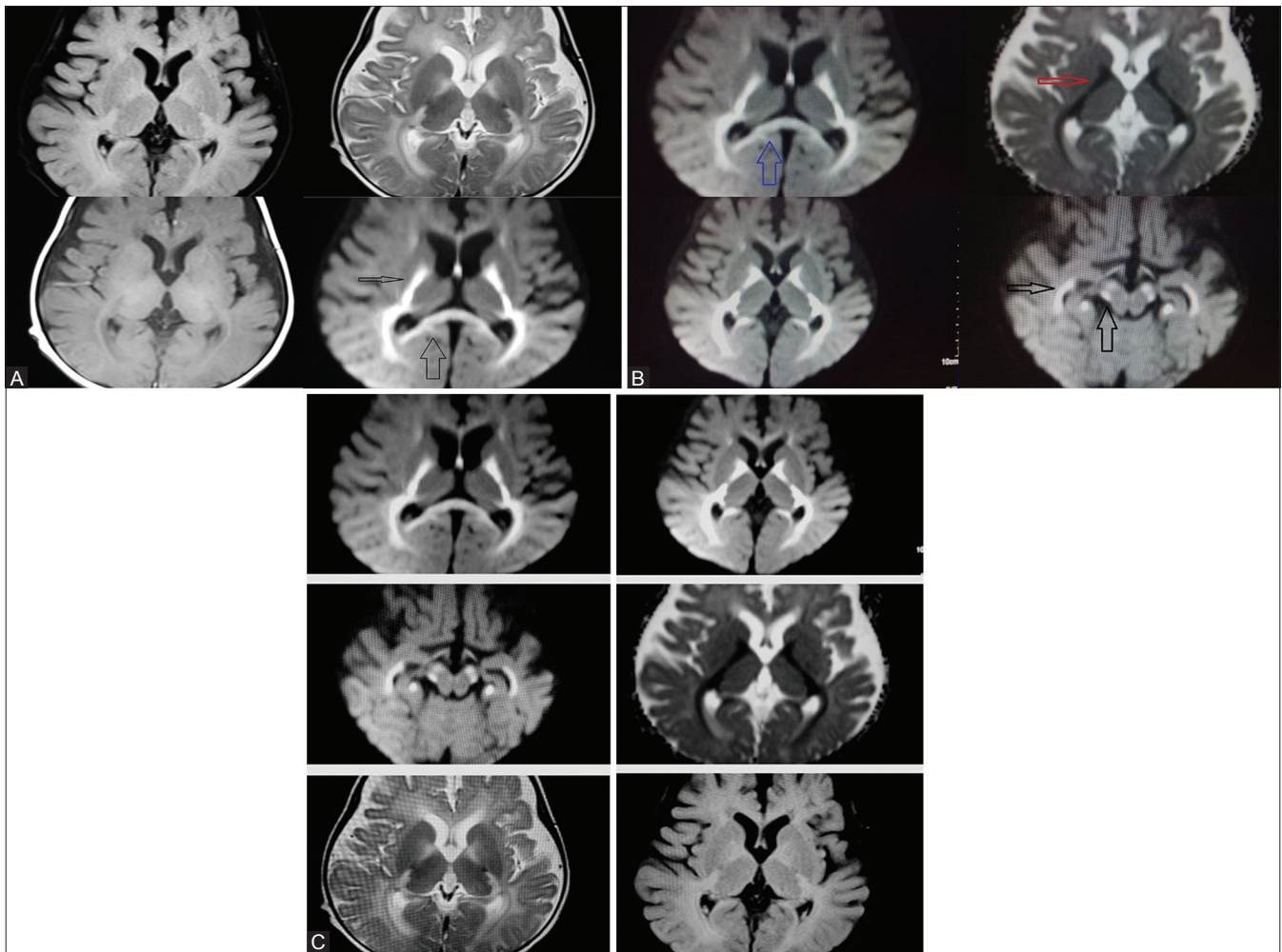


Figure 1 (A-C): (A) Case 1. DWI showing restricted diffusion in posterior limb of internal capsule (thin arrow), optic radiation, and splenium of corpus callosum (thick arrow). T1 and T2W/FLAIR image showing delayed myelination and cerebral atrophy with T2 hyperintense signal in involved area. (B) Case 1. DWI with corresponding ADC map showing restricted diffusion in posterior limb of internal capsule (red arrow), optic radiation (thin black arrow), splenium of corpus callosum (blue arrow), and cerebral peduncle (thick black arrow). (C) Case 1. Diffusion-weighted image with corresponding ADC map showing restricted diffusion in posterior limb of internal capsule, optic radiation, splenium of corpus callosum, and cerebral peduncle. T1- and T2-weighted image showing delayed myelination and cerebral atrophy with T2 hyperintense signal in involved area

differential diagnosis of maple syrup urine disease (MSUD) and biotinidase deficiency was given, although age of presentation of patient was older for MSUD. His urine examination was negative for MSUD. Biochemical assay of blood revealed congenital biotinidase deficiency.

Case 2

Another 7-month-old female child, first baby of nonconsanguineous marriage, presented with seizure, hypotonia, and neurodevelopmental delay. Her milestones were delayed and neck holding was still incomplete. Her routine blood investigations were within normal limits. Noncontrast MRI brain revealed similar changes in T2 and FLAIR hyperintense signal with restricted diffusion as seen in case 1, but involvement of periventricular cerebral white matter and splenium of corpus callosum was less marked, with noninvolvement of cerebellar white matter [Figures 4 and 5]. Delayed myelination was also noted with more prominent cerebral atrophy especially

involving frontal lobes. Biochemical assay of blood was positive for biotinidase deficiency.

Discussion

Biotin is an important vitamin found in some foods. It plays an important role as cofactor for pyruvate, propionyl-CoA, beta-methylcrotonyl-CoA, and two isoenzymes of acetyl-CoA carboxylase in gluconeogenesis, amino acid catabolism, and fatty acid synthesis.^[1]

Biotinidase deficiency is a rare and treatable inherited neurometabolic disorder^[2] with an estimated incidence of 1:61,067 population. This disorder in its severe form is much rarer with incidence of 1:1,37,401.^[3] Clinical findings of this disorder include neurological (seizure, ataxia, hypotonia, neurodevelopmental delay), dermatological (eczematous skin rash, seborrheic dermatitis), immunological, ophthalmological, respiratory

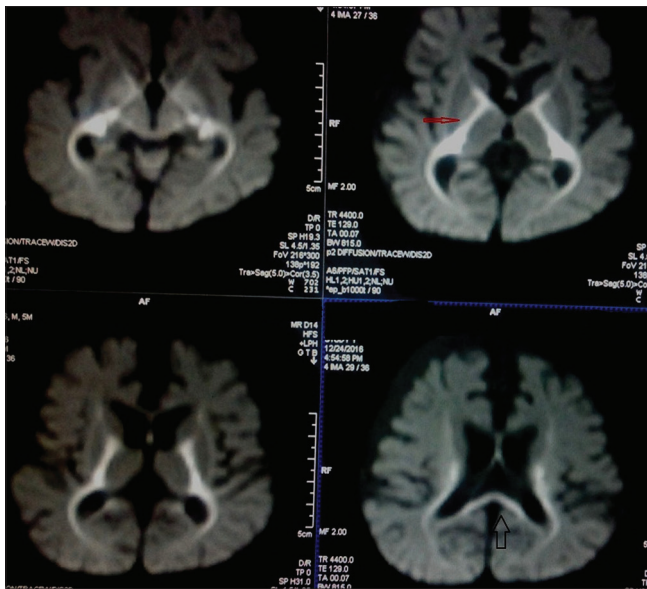


Figure 2: Case 1. Diffusion-weighted images showing restricted diffusion in posterior limb of internal capsule (red arrow), splenium of corpus callosum (black arrow), and periventricular white matter (blue arrow)

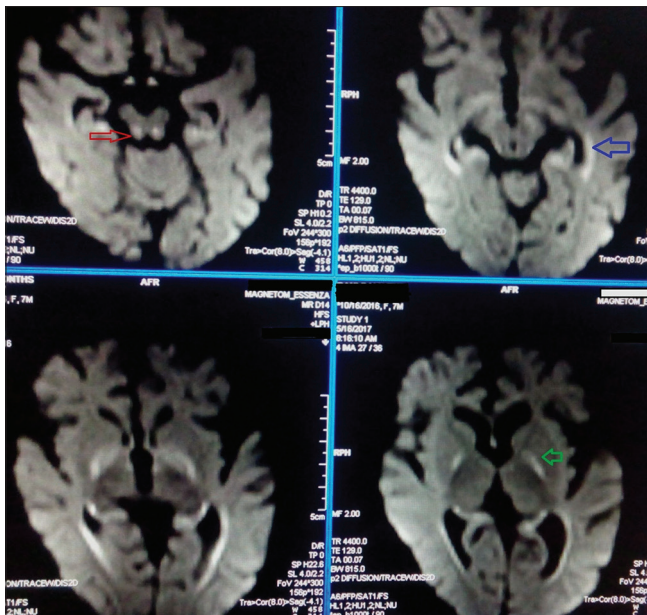


Figure 4: Case 2. Diffusion-weighted images showing restricted diffusion in dorsal mid brain (red arrow), posterior limb of internal capsule (green arrow), and medial temporal gyri and periventricular white matter/optic radiation (blue arrow)

problems (hyperventilation, apnea and laryngeal stridor), and alopecia.^[1,4] Laboratory findings include abnormal organic acids in the urine, metabolic acidosis, and elevated lactate and pyruvate levels in blood. Diagnosis can be confirmed by measuring blood biotinidase activity.^[5,6]

Most of the literature have reported MRI findings in biotinidase deficiency as cerebral atrophy, cerebral edema, and bilateral compensatory ventriculomegaly.^[4] Apart

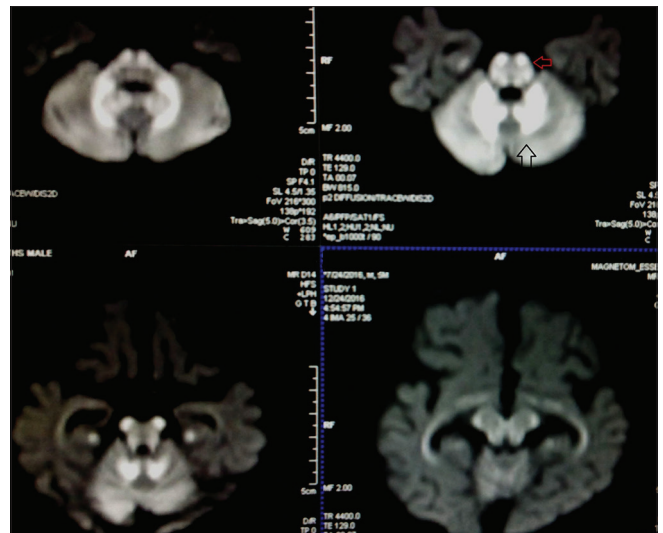


Figure 3: Case 1. Diffusion-weighted images showing restricted diffusion in brain stem (red arrow), middle cerebellar peduncle (blue arrow), and cerebellar white matter (black arrow)

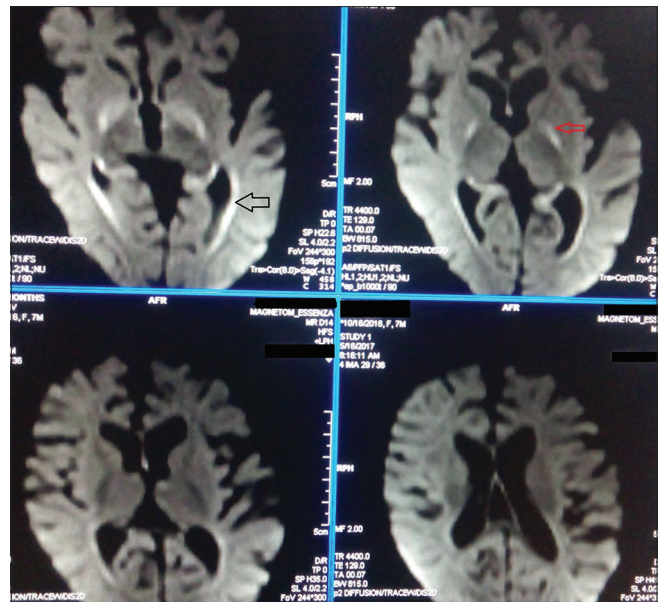


Figure 5: Case 2. Diffusion-weighted images showing restricted diffusion in posterior limb of internal capsule (red arrow) and medial occipital gyri and periventricular white matter/optic radiation (black arrow)

from it, delayed myelination has also been reported. But these changes are seen late in the course of disease, and there are few reports of imaging studies in biotinidase deficiency in early stage. In late course of disease, MRI shows loss of brain volume, with increased ventricular size and increased subarachnoid spaces. Subdural hygromas or hematomas may also develop.^[7] T1- and T2-weighted images show delayed myelination, with reduced diffusion and increased fractional anisotropy in the deep white matter of the cerebral hemispheres.^[6] One report suggests that uncommonly, cortical injury may occur.^[7] Proton magnetic resonance spectroscopy (MRS) at long and intermediate (135

ms) echoes shows marked elevation of lactate with decreased N-acetylaspartate (NAA) and choline. All these abnormalities reverse rapidly if therapy is started early.^[7,8]

Karimzadeh *et al.*^[8] in their study of 16 patients of biotinidase deficiency reported that 12 patients had abnormal neuroimaging. Of these, nine patients had generalized brain atrophy and myelination delay on brain imaging. Computed tomography (CT) scan showed multiple calcifications in one case. One patient had left hemiatrophy, two showed demyelination in white matter, and one had abnormal signal changes in basal ganglia.

Two infants with early presentation of biotinidase deficiency (age 3 weeks and 2 weeks) were described by Haagerup *et al.*^[9] On admission, both children had severe neurological symptoms. In the first patient, MRI of the brain showed frontal and temporal atrophy, and in the second patient, CT of the brain showed diffuse periventricular hypodensities, particularly in the frontal region.

Few studies have described findings on diffusion-weighted MRI in early stage of biotinidase deficiency. Bhat *et al.*^[10] have described unique MRI features in patients with biotinidase deficiency with brain MRI demonstrating symmetrical diffusion restriction in bilateral hippocampi, parahippocampal gyri, central tegmental tracts, and cerebellar white matter. Similar findings were also seen in our cases, especially in case 1.

A description of diffusion-weighted MRI findings in a case of biotinidase deficiency by Desai *et al.*^[6] demonstrated markedly reduced diffusion in the brain stem, middle cerebellar peduncles, splenium of the corpus callosum, posterior limbs of the internal capsules, corona radiata, and parieto-occipital white matter. Similar findings were also seen in our first case.

Diffusion-weighted imaging ($b = 1000 \text{ s/mm}^2$) and diffusion tensor imaging findings in cases of biotinidase deficiency have also been described by Soares-Fernandes *et al.*^[11] Their study revealed symmetric moderately reduced diffusion with abnormally increased fractional anisotropy in the centrum semiovale and periventricular white matter. However, corpus callosum was not involved, although there was involvement of posterior limb of internal capsule. Similar findings were observed in case 2; however, diffusion tensor imaging was not performed in our case.

Therefore, overall the MRI findings that have been described in literature in cases of congenital biotinidase deficiency and seen in our cases include the following: (1) early presentation – symmetrical diffusion restriction in bilateral hippocampi, parahippocampal gyri, corona radiata, posterior limb of internal capsule, splenium of corpus callosum, central tegmental tracts, cerebellar white matter,

brain stem, and middle cerebellar peduncles with features of delayed myelination. (2) Late presentation – brain atrophy especially in temporal and frontal lobes. (3) Rare features – subdural hygromas and abnormal signal intensity changes in basal ganglia. (4) MR spectroscopy findings – on long and intermediate (135 ms) echoes, marked elevation of lactate with decreased NAA and choline. (5) Diffusion tensor imaging findings of abnormally increased fractional anisotropy in the centrum semiovale and periventricular white matter.

Imaging differentials of congenital biotinidase deficiency include MSUD and Leigh's syndrome. Most close differential diagnosis is MSUD which shows marked diffusion restriction in white matter tracts, however, with involvement of thalami and basal ganglia as well. In addition, MSUD presents at an earlier age in neonatal period with symptoms of poor feeding, vomiting, poor weight gain, increasing lethargy, and maple-syrup-like urine odor.^[12] In Leigh's syndrome, involvement of grey matter nuclei is more marked when compared with white matter tract involvement. Also, diffusion restriction is less marked in Leigh's syndrome when compared with biotinidase deficiency and seen predominantly during acute phase.^[13,14]

Conclusion

Biotinidase deficiency is a rare neurometabolic disorder that has clinical features common to other inborn errors of metabolism. In addition to findings of delayed myelination and brain atrophy, diffusion-weighted MRI findings as seen in our cases and few other previous case series would be helpful in early diagnosis of disease and thus early institution of treatment leading to prevention of devastating clinical manifestations.

Acknowledgement

The authors are thankful to Mr. Mohan Chandra, Medical Transcriptionist, Rama Medical College, in helping to prepare the article.

Declaration of patient consent

The authors certify that they have obtained all appropriate patient consent forms. In the form the patient(s) has/have given his/her/their consent for his/her/their images and other clinical information to be reported in the journal. The patients understand that their names and initials will not be published and due efforts will be made to conceal their identity, but anonymity cannot be guaranteed.

Financial support and sponsorship

Nil.

Conflicts of interest

There are no conflicts of interest.

References

1. Wolf B. Disorders of biotin metabolism. In: Scriver CR, Beaudet AL, Sly W, *et al.* editors. *The Metabolic and Molecular Bases of Inherited Disease*. 8th ed, New York: McGraw-Hill; 2001. p. 3935-62.
2. Rathi N, Rathi M. Biotinidase deficiency with hypertonica as unusual feature. *Indian Pediatr* 2009;46:65-7.
3. Wolf B. Worldwide survey of neonatal screening for biotinidase deficiency. *J Inher Metab Dis* 1991;14:923-7.
4. Dahiphale R, Jain S, Agrawal M. Biotinidase deficiency. *Indian Pediatr* 2008;45:777-9.
5. Heard GS, SecorMcVoy JR, Wolf B. A Screening method for biotinidase deficiency in newborns. *Clin Chem* 1984;30:125-7.
6. Desai S, Ganesan K, Hegde A. Biotinidase deficiency: A reversible metabolic encephalopathy – Neuroimaging and MR spectroscopic findings in a series of four patients. *Pediatr Radiol* 2008;38:848-56.
7. Barkovich AJ, Raybaud C. *Pediatric Neuroimaging*. 5th ed. Philadelphia, PA: Lippincott Williams & Wilkins; 2012. p. 108-9.
8. Karimzadeh P, Ahmadabadi F, Jafari N, Jabbehdari S, Alaei MR, Ghofrani M, *et al.* Biotinidase deficiency: A reversible neurometabolic disorder (An Iranian Pediatric Case Series). *Iran J Child Neurol* 2013;7:47-52.
9. Haagerup A, Andersen JB, Blichfeldt S, Christensen MF. Biotinidase deficiency: Two cases of very early presentation. *Dev Med Child Neurol* 1997;39:832-5.
10. Bhat MD, Bindu PS, Christopher R, Prasad C, Verma A. Novel imaging findings in two cases of biotinidase deficiency – A treatable metabolic disorder. *Metab Brain Dis* 2015;30:1291-4.
11. Soares-Fernandes JP, Magalhães Z, Rocha JF, Barkovich AJ. Brain diffusion-weighted and diffusion tensor imaging findings in an infant with biotinidase deficiency. *AJNR Am J Neuroradiol* 2009;30:E128.
12. Jain A, Jagdeesh K, Mane R, Singla S. Imaging in classic form of maple syrup urine disease: A rare metabolic central nervous system. *J Clin Neonatol* 2013;2:98-100.
13. Warmuth-Metz M, Hofmann E, Büsse M, Solymosi L. Uncommon morphologic characteristics in Leigh’s disease. *AJNR Am J Neuroradiol* 1999;20:1158-60.
14. Arii J, Tanabe Y. Leigh syndrome: Serial MR imaging and clinical follow-up. *AJNR Am J Neuroradiol* 2000;21:1502-9.