

Evaluation of patella alta using MRI measurements in adolescents

Barış Yılmaz, Guzelali Ozdemir¹, Evrim Sirin, Esin D Cicek², Burcu S Anil², Goncagul Bulbun²

Department of Orthopedic Surgery and Traumatology and ¹Department of Radiology, Fatih Sultan Mehmet Education and Research Hospital, Istanbul, ²Department of Orthopedic Surgery and Traumatology, Ankara Numune Education and Research Hospital, Ankara, Turkey

Correspondence: Dr. Barış Yılmaz, Department of Orthopedic Surgery and Traumatology, Fatih Sultan Mehmet Education and Research Hospital, Istanbul, Turkey. E-mail: drbyilmaz@yahoo.com

Abstract

Purpose: To determine whether or not there were any differences in the measurement techniques used by orthopedic and radiology specialists in the evaluation of magnetic resonance (MR) images for the diagnosis of patella alta in adolescents. **Materials and Methods:** Evaluations were performed by three orthopedic specialists (Group I) and three radiology specialists (Group II) regarding the presence of patella alta in 40 adolescents cases using the Insall–Salvati, Caton–Deschamps, Blackburne–Peel, and modified Insall–Salvati indices on MR images obtained to diagnose patellar instability. **Results:** The Fleiss Kappa conformity levels for Insall–Salvati, Caton–Deschamps, Blackburne–Peel, and modified Insall–Salvati measurements were 0.531, 0.559, 0.246, and 0.272, respectively, in Group I, and 0.699, 0.346, 0.516, and 0.394, respectively, in Group II. **Conclusion:** The radiology specialists were found to have greater conformity in the evaluation of all patella alta indices, which was probably due to their greater familiarity with radiological measurements than that of the orthopedic specialists.

Key words: Blackburne–Peel; Caton–Deschamps; Insall–Salvati; modified Insall–Salvati; patella alta

Introduction

One of the reasons for a change in the contact of the patella with the trochlea is patella alta, which occurs when the patella is located higher than normal in the patellofemoral joint. The clinical importance of this is greater than previously believed. It has been reported that patella alta is present in 24% of patellar instability cases and accompanies a stable patella in only 3% of cases.^[1] Diagnosis is ideally made using indices defined on magnetic resonance imaging (MRI) or a lateral radiograph of the knee at 30° flexion.

Many indices have been defined for measuring the height of the patella. There is still no consensus on whether

these indices should use the patella or tibia as a reference point. There are both positive and negative aspects of each of the indices, and the most commonly used indices are the Insall–Salvati (IS), modified Insall–Salvati (MIS), Caton–Deschamps (CD), and Blackburne–Peel (BP) indices.^[2–5] Of these, the Insall–Salvati index is known to be the most useful technique for orthopedic and radiology specialists. Because it is difficult to keep the knee in a standard position at 30° flexion for every lateral X-ray view, it would seem to be more appropriate to measure these indices on MRI sections. However, this is a more complicated evaluation compared to lateral X-ray evaluation because the length of the patella and the patellar tendon differ on each MRI section. One method is to take these measurements using a single midsagittal

This is an open access article distributed under the terms of the Creative Commons Attribution-NonCommercial-ShareAlike 3.0 License, which allows others to remix, tweak, and build upon the work non-commercially, as long as the author is credited and the new creations are licensed under the identical terms.

For reprints contact: reprints@medknow.com

Cite this article as: Yılmaz B, Ozdemir G, Sirin E, Cicek ED, Anil BS, Bulbun G. Evaluation of patella alta using MRI measurements in adolescents. Indian J Radiol Imaging 2017;27:181-6.

Access this article online

Quick Response Code:



Website:
www.ijri.org

DOI:
10.4103/ijri.IJRI_222_16

image; the length of patella is determined by the distance between the anteroinferior and posterosuperior edges of the patella, and the length of the patellar tendon is measured by drawing a line parallel to the deepest edge of the patellar tendon.^[6]

In the current study, the diagnosis of patellofemoral instability in adolescents was made by MRI examination because MRI is an imaging method with a high sensitivity that can be used in the visualization of anatomic variations, such as patella alta, which leads to patellar instability.^[6] The aim of the current study was to determine whether or not there were differences in the measurement values of the measurement techniques used by radiology specialists aiming to make a diagnosis and orthopedic specialists focusing on treatment in cases of patella alta.

Materials and Methods

A retrospective review was made of radiology department records to obtain details of adolescents aged 10–16 years with previously lower extremity MRI. The study included 40 randomly selected cases suitable for radiological and MRI examination. Informed consent was obtained from the patients and their legal guardians. Patients aged >16 years or who had undergone previous proximal or distal patellar realignment surgery, or with a previous patellar fracture or a metabolic, oncological, or rheumatological problem around the knee, and patients who were unable to express their problems by themselves were excluded from the study. All patients underwent routine 1.5-T MRI (450W gem suite, General Electric Healthcare), with all images obtained using a Picture Archiving and Communications System (PACS) system.

Patella alta evaluations were performed on 40 adolescent patients by three orthopedic specialists (Group I) and three radiology specialists (Group II), each with a minimum of 5 years of professional experience, who all worked at our hospital. The Insall–Salvati (IS), modified Insall–Salvati (MIS), Caton–Deschamps (CD), and Blackburne–Peel (BP) indices were used for the evaluations on MRI obtained for the purpose of patellar instability diagnosis. The IS indices were calculated from patellar bone length and patellar tendon length, the latter being defined as the distance between the proximal point of the tibial tuberosity and the inferior pole of the patella [Figure 1]. The CD indices were calculated from the patellar articular cartilage length and the distance between the lowest point of the part of the patella in contact with the femur to the top of the tibial plateau [Figure 2]. The BP indices were calculated from the patellar articular cartilage length and the distance between the tibial plateau line and the inferior pole of the patellar articular cartilage [Figure 3], and the MIS indices were calculated from the patellar articular cartilage length and the distance between the the proximal point of

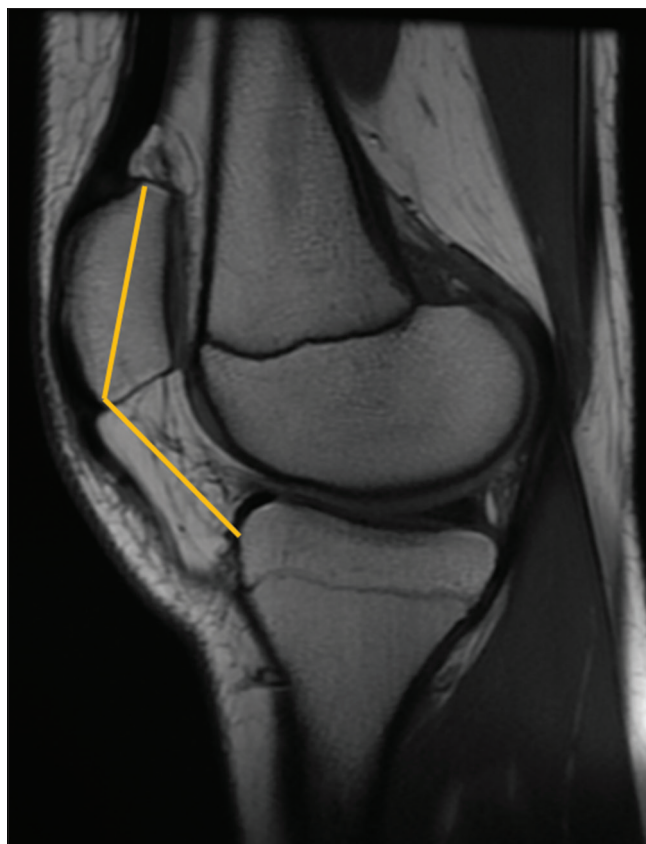

Figure 1: Insall–Salvati indices: from patellar bone length and patellar tendon length, the latter of which was defined as the distance between the proximal point of the tibial tuberosity and the inferior pole of patella

the tibial tuberosity and the inferior pole of the patellar articular cartilage [Figure 4].

Magnetic resonance imaging datasets of 40 adolescent knees were acquired as approved by the Institutional Review Board (Research Ethics Committee no. FSM EAH-KAEK 2013/20).

When evaluating the findings obtained in the present study, statistical analyses were performed using the IBM SPSS Statistics 22 (IBM, SPSS, Turkey) program. The Kappa coefficient was used to determine the paired conformity levels between observers, and the Fleiss Kappa coefficient was calculated when determining the general conformity levels among three observers. Values of $P < 0.05$ were accepted as statistically significant.

Results

The study group included 20 (50%) males and 20 (50%) females with a median age of 14.2 years. The results are summarized in Tables 1 and 2. The Insall–Salvati measurements were all found to be statistically significant in both Groups I and II ($P < 0.01$) [Table 1 and 2]. The Fleiss Kappa conformity level for the IS measurements was 0.531 in Group I and 0.699 in Group II.

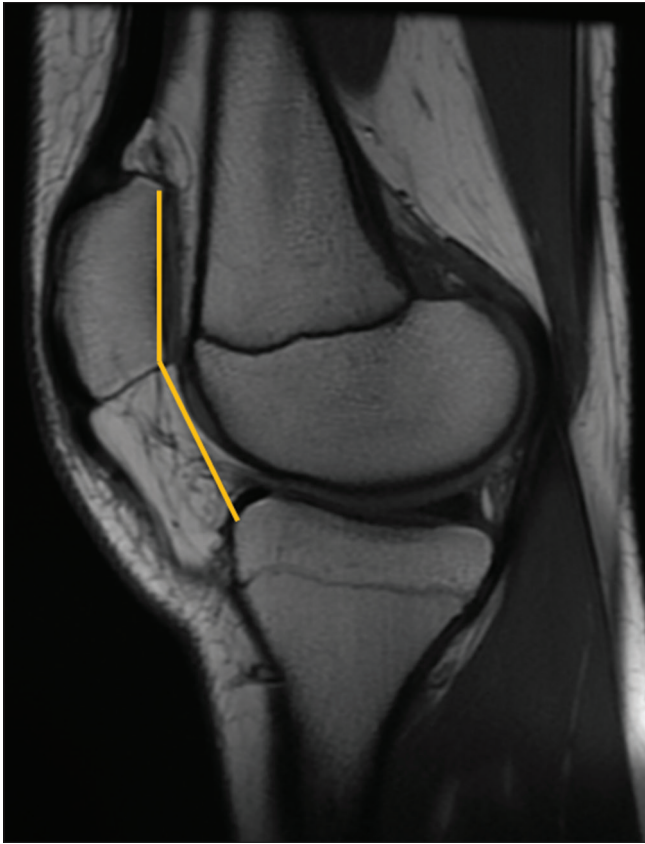

Figure 2: Caton–Deschamps indices: from patellar articular cartilage length and the distance between the lower point of the part of the patella that makes contact with the femur to the top of the tibial plateau

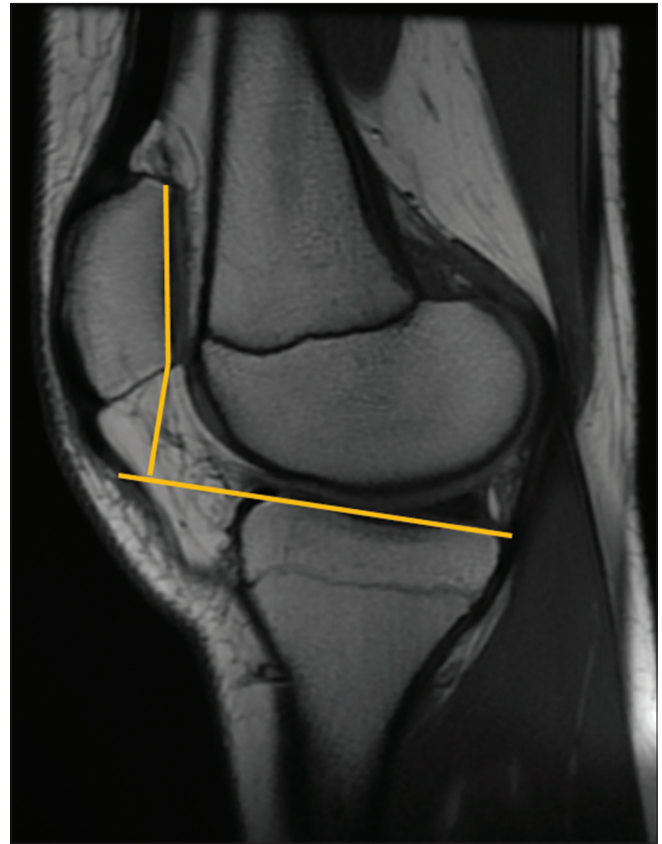


Figure 3: Blackburne–Peel indices: from patellar articular cartilage length and the distance between the tibial plateau line and the inferior pole of patellar articular cartilage

Table 1: The levels of conformity for all the measurements of the orthopaedists (Group I)

	Kappa	P
Insall-Salvati		
01-02	0.536	0.001**
01-03	0.511	0.001**
02-03	0.563	0.001**
Blackburne-Peel		
01-02	0.212	0.109
01-03	0.140	0.165
02-03	0.518	0.001**
Caton-Deschamps		
01-02	0.648	0.001**
01-03	0.436	0.005**
02-03	0.595	0.001**
Modified Insall-Salvati		
01-02	0.477	0.003**
01-03	0.236	0.056
02-03	0.118	0.358

* $P < 0.05$, ** $P < 0.01$. 0: Orthopaedists

The Caton–Deschamps measurements were all found to be statistically significant in Group I ($P < 0.01$) [Table 1]. In Group I, the Fleiss Kappa conformity level was 0.559 for the CD measurements. In Group II, the conformity level

between observers 1 and 2 was 10.9% and between observers 1 and 3 was 15.7%; these results were not statistically significant ($P > 0.05$). The conformity between observers 2 and 3 was 68.9%, which was found to be statistically significant ($P < 0.01$) [Table 2]. In this group, the Fleiss Kappa conformity level was 0.346 for the CD measurements.

In the Blackburne–Peel measurements, the conformity level in Group I was 14% between observers 1 and 2 and 21.2% between observers 1 and 3; these results were not statistically significant ($P > 0.05$). The conformity level between observers 2 and 3 was 51.8%, which was found to be statistically significant ($P < 0.01$) [Table 1]. In this group, the Fleiss Kappa conformity level was 0.246 for the BP measurements. In Group II, the BP measurements were all found to be statistically significant [Table 2]. In this group, the Fleiss Kappa conformity level was 0.516 for the BP measurements.

For the modified Insall–Salvati measurements, the conformity level in Group I was 23.6% between observers 1 and 2 and 11.8% between observers 2 and 3; these were not statistically significant ($P > 0.05$). The conformity level between observers 1 and 3 was 47.7%, which was found to be statistically significant ($P < 0.01$) [Table 1]. In Group I, the Fleiss Kappa conformity level was 0.272 for the MIS

Table 2: The levels of conformity for all the measurements of the radiologists (Group II)

	Kappa	P
Insall-Salvati		
R1-R2	0.597	0.001**
R1-R3	0.650	0.001**
R2-R3	0.850	0.001**
Blackburne-Peel		
R1-R2	0.262	0.036*
R1-R3	0.262	0.036*
R2-R3	1.000	0.001**
Caton-Deschamps		
R1-R2	0.109	0.339
R1-R3	0.157	0.215
R2-R3	0.689	0.001**
Modified Insall-Salvati		
R1-R2	0.063	0.527
R1-R3	0.076	0.465
R2-R3	0.939	0.001**

**P<0.01, R: Radiologists

Table 3: Fleiss Kappa interpretation table

Fleiss kappa	Interpretation
< 0	No conformity
0.0-0.20	Insignificant conformity
0.21-0.40	Moderate conformity
0.41-0.60	General conformity
0.61-0.80	Significant conformity
0.81-1.00	Almost excellent conformity

measurements. In Group II, the conformity level between observers 1 and 2 was 6.3% and between observers 1 and 3 was 7.6%; these were not statistically significant ($P > 0.05$). The conformity level between observers 2 and 3 was 93.9%, which was found to be statistically significant ($P < 0.01$) [Table 2]. In Group II, the Fleiss Kappa conformity level was 0.394 for the MIS measurements.

All these results were interpreted according to the Fleiss Kappa interpretation table [Table 3]. In the evaluations made according to this table, in Group I, there was general conformity for the IS and CD indices and moderate level conformity for the BP and MIS indices. In Group II, there was a significant level of conformity for the IS index, a general level for the BP index and a moderate level for the CD and MIS indices [Figure 5].

Discussion

The height of the patella can be evaluated with direct or indirect methods. Evaluation methods for the patella height, taking specific points on the femur as reference points, are known as direct methods. The technique described by Blumensaat in 1938, using the roof of the intercondylar notch as the reference line, is one of the most widely used

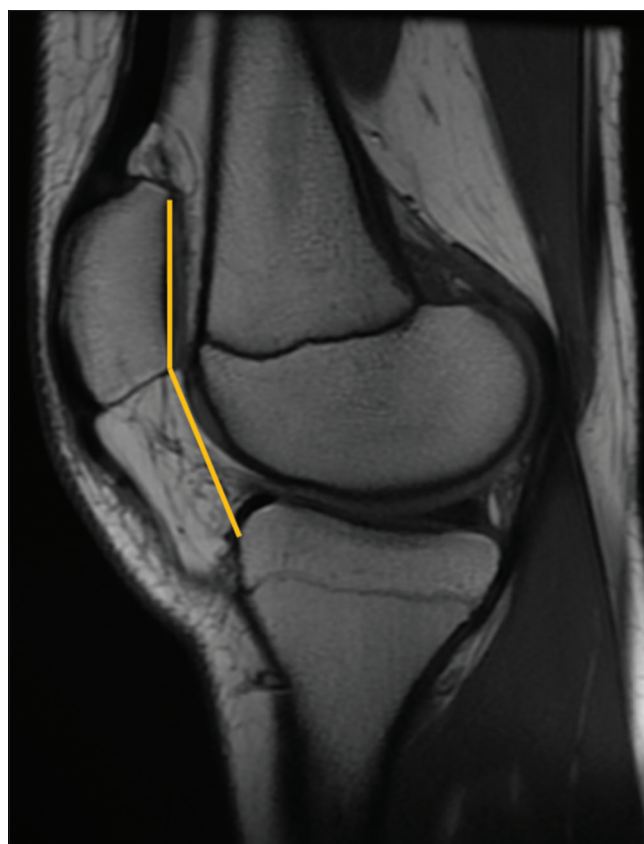

Figure 4: Modified Insall–Salvati indices: from patellar articular cartilage length and the distance between the the proximal point of the tibial tuberosity and the inferior pole of patellar articular cartilage

direct methods in the evaluation of patella height.^[7-9] The advantage of this method is that it is practical, and the vertical placement of the patella is evaluated in reference to the femur.^[10] Two points of criticism for this method are that it is significantly affected by the degree of knee flexion and that the angle of the Blumensaat line made with the femoral shaft is variable.^[11,12]

These problems have led to a greater preference for indirect methods such as the Insall–Salvati, Blackburne–Peel, and Caton–Deschamps indices, which evaluate the patella height in reference to the length of the patellar tendon and the proximal tibia.^[5,13,14] These methods evaluate the patella height indirectly according to various tibial reference points.^[15] Numerous studies have compared these measurement methods, and different authors have emphasised the various advantages of the different methods.^[7,10-14] Over time, taking other indices into consideration, modifications have been made to some of the indices themselves, such as for the Insall–Salvati index, which has been updated as the modified Insall–Salvati index.

However, no consensus has yet been reached on a “gold standard” method. Therefore, it is currently not possible to

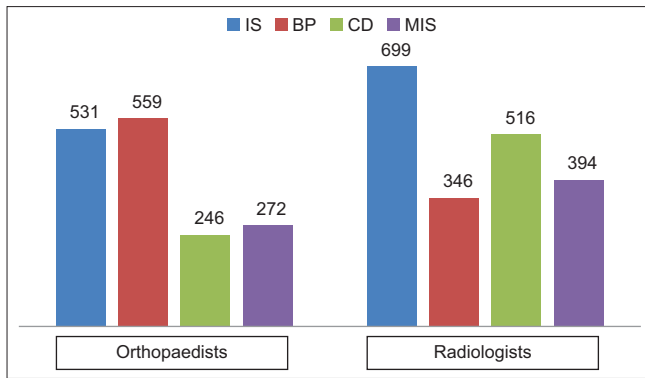


Figure 5: According to Orthopaedists and Radiologists, the Fleiss Kappa conformity level for all the measurements

evaluate the sensitivity and specificity of a particular method in the assessment of patella height, although conformity and correlations can be examined among methods known to be effective. Unfortunately, only weak correlations have been found between these different indices of patella height, and there is a lack of agreement in literature. In the current study, the results obtained were not compared with those of the previous studies that investigated reliability by comparing the indices of patella height. Thus, it is extremely important to examine the conformity and correlations among the measurement distributions of the patella height indices in a large number of patients. Such a study would offer significant insights regarding the selection of a gold standard method of determining patella height.

For the Insall–Salvati index, when there is an elongated lower pole of the patella, known as Cyrano patella, even if patella alta is present, the index value may still fall within the normal range. After tibial tubercle transfer, either distal or proximal, the index value may not change because the measurement points remain the same, which is why the index was modified. Although widely used, there are still some disadvantages of the Insall–Salvati and the modified Insall–Salvati indices. First, both the Insall–Salvati indices can be affected by the stretching of the patellar tendon and the degree of knee flexion. Furthermore, the attachment point of the tendon to the tibia is not always definitive, and this feature is more prominent in immature knees. In addition, the length of the patella does not always provide accurate information on the length of the joint surface. Because the volume of the extraarticular part of the inferior section of the patella may vary, this may cause measurement errors. Moreover, measurement is more difficult when tibial tubercle transfer has been performed.^[2]

Despite all these negative points, the level of conformity for the Insall–Salvati index in the current study was high for both the orthopedic and radiology specialists. This may be explained by the fact that this index is more well-known and is more practical to apply than the other indices assessed in the present study. An interesting finding in the present

study was that the conformity in both the orthopedic and radiology specialists for the modified Insall–Salvati index was as high as that for the Insall–Salvati index.

The Caton–Deschamps index is possibly a better method than either of the Insall–Salvati indices because it is not based on the whole patella but on the length of the joint surface.^[4] A significant advantage of this method is that it allows direct calculation of the amount of tibial tubercular transfer. A negative aspect of this method is that, in some cases, the anterosuperior corner of the tibia is not clear. In these cases, the most proximal point of the tibia is taken, and this is known as the de Carvalho index; however, this point can vary in different people. In the current study, in general, the agreement of the orthopedic specialists for this index was found to be at least as high as for the Insall–Salvati index. The conformity between the radiologists was observed to be lower, which could be because the Caton–Deschamps index is a better known method and more easily evaluated by the orthopedic specialists, who were not as familiar as the radiologists with making measurements on radiographic tests. Although the evaluation of this index was easier for the radiology specialists, it was interesting to note that the conformity among them was lower.

Another index that uses the proximal tibia for measurement is the Blackburne–Peel index.^[3] The main disadvantage of this method is that the line drawn along the plateau is naturally associated with the tibial slope. If the slope is greater than normal, then patella alta will not be revealed. In the current study, a greater level of conformity was found among the radiology specialists for this method. This may be due to the reference points being more complex than those of the other indices, and thus the radiology specialists are more familiar than orthopedic specialists with measurements on radiographic examinations.

A limitation of this study was the limited number of patients. In addition, the patients were all drawn from a single country population. Future investigations based on different races and ethnicity would provide more complete data. Because of the limited number of patients, this study can be considered a preliminary report with a detailed description of a promising new patella alta criteria.

Conclusion

In conclusion, probably because of their greater familiarity with radiological measurements, the conformity among the radiologists was greater than that among the orthopedic specialists in all of the index evaluations of patella alta in the current study. However, the interobserver variability among the different indices has led to efforts to define new indices, such as the patellotrochlear index defined on sagittal MRI proposed by Biedert and Albrecht.^[16,17] Therefore, to combat

the possibility of anatomic variations that could result in differing results among the indices, it can be concluded that several indices should be used for the definitive diagnosis of patella alta, regardless of whether the measurement is made by the orthopaedic surgeon or the radiologist.

Financial support and sponsorship

Nil.

Conflicts of interest

There are no conflicts of interest.

References

1. Dejour H, Walch G, Nove-Josserand L, Guier C. Factors of patellar instability: An anatomic radiographic study. *Knee Surg Sports Traumatol Arthrosc* 1994;2:19-26.
2. Insall J, Salvati E. Patella position in the normal knee joint. *Radiology* 1971;101:101-4.
3. Blackburne JS, Peel TE. A new method of measuring patellar height. *J Bone Joint Surg [Br]* 1977;59:241-2.
4. Caton J, Deschamps G, Chambat P, Lerat JL, Dejour H. Patella infera. Apropos of 128 cases. *Rev Chir Orthop Reparatrice Appar Mot* 1982;68:317-25.
5. Narkbunnam R, Chareancholvanich K. Effect of patient position on measurement of patellar height ratio. *Arch Orthop Trauma Surg* 2015;135:1151-6.
6. Shabshin N, Schweitzer ME, Morrison WB, Parker L. MRI criteria for patella alta and baja. *Skeletal Radiol* 2004;33:445-50.
7. Seil R, Muller B, Georg T, Kohn D, Rupp S. Reliability and interobserver variability in radiological patellar height ratios. *Knee Surg Sports Traumatol Arthrosc* 2000;8:231-6.
8. Norman O, Egund N, Ekelund L, Runow A. The vertical position of the patella. *Acta Orthop Scand* 1983;54:908-13.
9. Igbigbi PS, Msamati BC, Ng'Ambi TM. Intercondylar shelf angle in adult black Malawian subjects. *Clin Anat* 2001;14:254-7.
10. Koshino T, Sugimoto K. New measurement of patellar height in the knees of children using the epiphyseal line midpoint. *J Pediatr Orthop* 1989;9:216-8.
11. Brattstrom H. Patella alta in non-dislocating knee joints. *Acta Orthop Scand* 1970;41:578-88.
12. Grelsamer RP, Meadows S. The modified Insall-Salvati ratio for assessment of patellar height. *Clin Orthop Relat Res* 1992;282:170-6.
13. De Carvalho A, Holst Andersen A, Topp S, Jurik AG. A method for assessing the height of the patella. *Int Orthop* 1985;9:195-7.
14. Berg EE, Mason SL, Lucas MJ. Patellar height ratios. A comparison of four measurement methods. *Am J Sports Med* 1996;24:218-21.
15. Jozwiak M, Pietrzak S. Evaluation of patella position based on radiologic and ultrasonographic examination: Comparison of the diagnostic value. *J Pediatr Orthop* 1998;18:679-82.
16. Biedert RM, Albrecht S. The patellofemoral index: A new index for assessing patellar height. *Knee Surg Sports Traumatol Arthrosc* 2006;14:707-12.
17. Dejour D, Ferrua P, Ntagiopoulos PG, Radier C, Hulet C, Remy F, *et al.* The introduction of a new MRI index to evaluate sagittal patellofemoral engagement. *Orthop Traumatol Surg Res* 2013;99:391-8.