

# Early outcomes of radiofrequency ablation in unresectable metastatic colorectal cancer from a tertiary cancer hospital in India

Suyash Kulkarni, Nitin S Shetty, Ashwin M Polnaya, Sushil Patil, Kunal Gala, Rahul Chivate, Vikas Ostwal<sup>2</sup>, Anant Ramaswamy<sup>2</sup>, Shailesh V Shrikhande<sup>1</sup>, Mahesh Goel<sup>1</sup>, Shraddha Patkar<sup>1</sup>, Manish Bhandare<sup>1</sup>, Venkatesh Rangarajan<sup>3</sup>, Purandare Nilendu<sup>3</sup>

Department of Radio-diagnosis, <sup>1</sup>Surgical Oncology, <sup>2</sup>Medical Oncology and <sup>3</sup>Nuclear Medicine, Tata Memorial Centre, Mumbai, Maharashtra, India

**Correspondence:** Dr. Nitin S Shetty, Interventional Radiology, Tata Memorial Centre, Mumbai - 400 012, Maharashtra, India.  
E-mail: shettyns@tmc.gov.in

## Abstract

**Aims:** The study was carried out to evaluate the early outcomes using Radiofrequency Ablation (RFA) for unresectable liver metastases in the management of metastatic colorectal cancer (mCRC) from an area of low endemicity. **Material and Methods:** 60 Patients with unresectable colorectal liver metastases had undergone 88 sessions of RFA from January 2007 till December 2013. The results were retrospectively analysed to evaluate the outcomes in terms of efficacy and survival rates. **Results:** The median follow up of patients in our series was 24.8 months. 35/52 (67.3%) patients had complete response at 3 months while 8 patients were lost to follow up. Of the 17 patients who had recurrence, 4 (23.5%) were at the ablated site while 13 patients (76.4%) progressed elsewhere. Abdominal pain was commonest post procedural symptom (20%). There was no procedure related mortality or any major complications. Mean disease free interval and Progression free survival was 6.7 and 13.1 months. Estimated median survival in patients with liver limited disease and those with small lesion (<3cm) was 3.79 years and 3.45 years respectively. Median survival in patients with lesion size 3–5 cms was 1.5 years. Annual survival rates would be 94.5%, 55.2% and 26.2% for 1, 3 and 5 years. **Conclusion:** Radiofrequency ablation of unresectable liver metastases is effective in treatment of mCRC. Estimated survival rates and Annual survival rates at our institute from the low endemic region also follow the global trend. Size of the lesion was an important predictor of efficacy of RFA. Presence of extrahepatic disease and lesion size >3 cm was associated with decreased survival.

**Key words:** Radiofrequency ablation; unresectable colorectal liver metastases; metastatic colorectal cancer; Liver radiofrequency ablation

## Introduction

The functional status of liver plays an important role in the survival of patients suffering colorectal carcinoma (CRC).

Over 50% of the patients with CRC will develop liver metastases during their disease process, and 5-year survival rate of untreated liver metastases is less than 3%.<sup>[1]</sup>

This is an open access article distributed under the terms of the Creative Commons Attribution-NonCommercial-ShareAlike 3.0 License, which allows others to remix, tweak, and build upon the work non-commercially, as long as the author is credited and the new creations are licensed under the identical terms.

**For reprints contact:** reprints@medknow.com

**Cite this article as:** Kulkarni S, Shetty NS, Polnaya AM, Patil S, Gala K, Chivate R, *et al.* Early outcomes of radiofrequency ablation in unresectable metastatic colorectal cancer from a tertiary cancer hospital in India. *Indian J Radiol Imaging* 2017;27:200-6.

### Access this article online

#### Quick Response Code:



**Website:**  
www.ijri.org

**DOI:**  
10.4103/ijri.IJRI\_24\_17

While surgical resection is considered the gold standard for treatment of CRC liver metastases, only 10–20% of the patients with liver metastases are deemed resectable. Systemic therapy is the standard of care in such patients, which can prolong the median survival to more than 2 years.

Radiofrequency ablation (RFA) is a technique that causes tumor destruction by hyperthermia and improves survival over chemotherapy alone in patients with traditionally unresectable disease.<sup>[2,3]</sup> India is in a low endemic area of CRC according to GLOBOCON 2012 data. We retrospectively analyzed the efficacy and survival rates of our patients who had undergone RFA.

## Materials and Methods

Sixty patients with histopathologically proven diagnosis or its clinical or biochemical equivalent of metastases from colorectal malignancy who had undergone RFA from January 2007 to December 2013 at our institute were included in this study. Patients were considered to have unresectable disease because of insufficient future liver remnant, proximity to critical structures, prohibitive comorbidity, or refusal for surgery. Exclusion criteria included patients with Eastern cooperative oncology group performance status >2, more than 5 lesions, tumor located less than 1 cm from the main biliary duct, anterior exophytic location of the tumor, untreatable/unmanageable coagulopathy, or severe comorbidities.

### Pre radiofrequency ablation work-up

Routine biochemical investigations and tumor markers were performed in all patients planned for RFA. Preprocedure positron emission tomography/computed tomography (PET/CT) with intravenous contrast was performed to precisely evaluate the disease burden, location of tumors, and feasibility of ablation.

### Technique

RFA of all patients was performed under general anesthesia and CT guidance. A 150 W RF generator (RITA Medical Systems, Angiodynamics™, California) was used. To perform a typical ablation, two grounding pads were placed on the patient's thighs. Fourteen-gauge expandable electrode needles (StarBurst XL and SDE) were used in all cases, and the choice of electrode depended on the size and location of tumor. RFA was performed for a fixed duration depending on the size of the lesion, as per the manufacturer's protocol. At the end of the procedure, when the generator was turned off, a "cool down cycle" was automatically performed. A check CT scan was done to ascertain the completion of ablation, and overlapping ablation was performed as required to achieve complete ablation, including at least 1 cm of normal parenchyma around the tumor as margin. At the end of the session, the expandable tines were retracted and coagulation of the

needle track was performed (track ablation) at a temperature above 75°C with the aim of preventing any tumor cell dissemination.

### Post radiofrequency ablation evaluation and follow-up

Triphasic CT was done immediately after ablation to assess zone of ablation and to rule out any treatment related vascular complications prior to extubation. For FDG (Fluoro Deoxy Glucose) avid metastatic lesions, regional PET/CT was obtained within 24 h post procedure to confirm that ablation was complete and to plan further treatment in case of any residue. Patients were further monitored with biochemical markers and imaging [contrast-enhanced CT (CECT) or PET/CT] at 3, 6, and 12 months after treatment, and at yearly intervals thereafter for the next 5 years. In patients with FDG non-avid lesions, imaging follow-up was done using CECT. Follow-up imaging studies were aimed at detecting local tumor progression, development of new hepatic lesions, or emergence of extrahepatic disease.

Complete ablation was defined by no FDG uptake in any part of the treated lesion or residual enhancement in patients with non-FDG avid metastatic lesions. Patients with FDG uptake in the part of the treated lesion or residual enhancement in patients with non-FDG avid metastatic lesions were deemed to have residual lesion. Recurrence was defined as appearance of FDG activity or contrast enhancement within the ablated area after previous complete response. Appearance of new lesion or extrahepatic metastases was termed as disease progression. Complications were classified as minor and major according to the definition of the Society of Interventional Radiology (SIR). Major complications were those that required admission to a hospital for treatment (for outpatient procedures), an unplanned increase in the level of care, prolonged hospitalization, permanent adverse sequelae, or death. Minor complications were those with no sequelae, and those that may require nominal therapy or a short hospital stay for observation.

All the patients, at the time of discharge after RFA, were referred to the Medical Oncology department for opinion on systemic chemotherapy, and eligible patients were suggested treatment as per the institutional guidelines.

Institutional Ethics Committee approval was taken to perform the retrospective analysis of the data. SPSS version 16.0 (IBM Corporation Business Analytics Software, SPSS Inc. Chicago) was used for maintaining the data electronically. Survival analysis was performed using Kaplan–Meier analysis.

## Results

Sixty patients underwent 88 sessions of RFA. Median follow up was 24.8 months (7–73 months). Demographical details

**Table 1: Patient characteristics**

Demography	No of patients (%)
Sex	
Males	44 (73.3)
Females	16 (26.7)
Age range	
<25 years	01 (1.7)
25-50 years	19 (31.7)
50-75 years	37 (61.7)
>75 years	03 (5.0)
Intent of treatment	
Curative	51 (85.0)
Palliative	09 (15.0)
Disease	
Liver limited	49 (81.7)
Extrahepatic	11 (18.3)
Hepatic Disease burden	
Unilobar	47 (78.3)
Bilobar	13 (21.7)
No of lesions	
Solitary	44 (73.3)
>1	16 (26.7)
Size of lesion	
<3 cm	46 (76.7)
3-5 cm	14 (23.3)
Primary	
Synchronous	08 (13.3)
Operated	52 (86.7)
Post RFA Chemotherapy	
Yes	24 (40)
No	23 (38.3)
Post recurrence/progression	13 (21.7)

are summarized in Table 1. A total of 28/60 patients were alive at the time of last follow-up, whereas 7 patients were lost to follow-up.

There were no procedure-related mortality or any major complications. Abdominal pain was the most common postprocedural symptom encountered in 12 patients (20%). Five patients had postprocedure transient fever which responded to intravenous antibiotics and antipyretics. Two patients had subcapsular hemorrhage post RFA, which were managed conservatively.

A total of 6/60 patients had non-FDG avid metastatic liver lesion, and were followed with contrast CT along with the tumor markers.

In the immediate postprocedure scan, complete ablation was achieved in 46/52 (88.5%) patients [Figure 1], and imaging could not be performed in the remaining 8 patients due to logistic reasons. Out of the 52 patients, 41 were those with lesion size less than 3 cm with residual in 2 patients (4.8%),

whereas of the 11 patients who had lesion size more than 3 cm, 4 patients had residual (36.3%) lesions. Of the 6 patients with residual lesion, 5 were referred for systemic chemotherapy and 1 underwent repeat RFA [Figure 2].

At 3 months, imaging of 52 patients out of 60 were available for assessment. A total of 35/52 patients (67.3%) had complete response after RFA at 3 months. Of the 17 patients who had recurrence, 4 (23.5%) were at the ablated site whereas 13 patients (76.4%) progressed elsewhere; the median Disease Free Interval (DFI) was 6.3 months (range 43–581 days).

At end of the study period, 46/60 patients were available for evaluation (with minimum 6 months' post-RFA follow-up.) Out of these 46 patients, 33 patients had progressive disease. Twenty-one of the 33 patients (63.7%) had progression involving extrahepatic sites with or without involvement of liver whereas the remaining 12 patients (36.3%) had liver limited disease progression. There was complete response in 13 patients at the end of the study period.

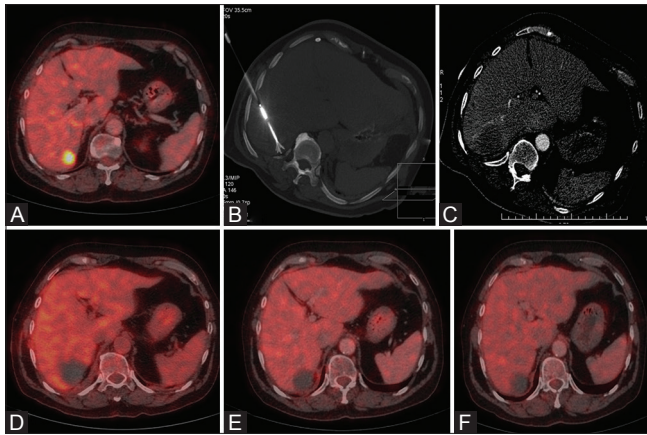
## Discussion

Hepatic resection or metastasectomy has been considered to be the only potentially curative treatment for patients with metastatic disease isolated to the liver. However, 80–90% of patients are not surgical candidates because of insufficient residual liver tissue, extrahepatic disease, anatomic constraints of the tumor, or medical comorbidities. In most series, the overall 5-year survival rate reported following hepatic resection with curative intent ranges 25–37%, with a median survival of between 24 and 40 months.<sup>[4-6]</sup>

Unfortunately, in many patients, liver metastases are so numerous or widely distributed that resection is not feasible. The prognosis for patients with untreated hepatic metastases is dismal, and 5-year survival rate is reported to be less than 1%.<sup>[7]</sup>

In patients with unresectable disease, median survival ranges from 6 months without chemotherapy to 2 years with chemotherapy.<sup>[8]</sup> Modern regimens utilizing oxaliplatin or irinotecan have improved overall survival in this population, however, still fall short of long-term cure.

RFA is a minimally invasive percutaneous technique where localized tumor destruction is done by the heat generated from high frequency alternating current by RFA electrode, and has been extensively used for ablation of liver tumors including colorectal liver metastases (CRLM). Tumor ablative techniques are minimally invasive and provide reasonable alternatives for patients who are not surgical candidates. Furthermore, it may be a reasonable alternative to metastasectomy in some patients due to its decreased

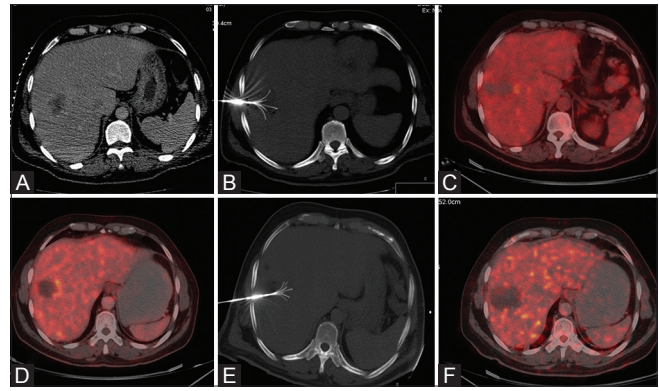


**Figure 1 (A-F):** 63 years male, operated case of Ca sigmoid colon presented with solitary segment VII FDG avid lesion (A), Radiofrequency ablation done using multitined monopolar electrode (B), Post RFA arterial phase CT (C) reveals ablation area with normal reactive zone of marginal hyperemia. Post RFA PET CT (D) reveals complete regression of FDG activity suggestive of complete ablation. 3 months and 1 year post procedure PET CT revealed complete response (E and F)

morbidity and cost. The number of lesions should not be considered an absolute contraindication to RFA if successful treatment of all metastatic deposits can be accomplished. Nevertheless, most centers preferentially treat patients with less than 5 lesions. Selected patients with limited hepatic and pulmonary colorectal metastatic disease also qualify for percutaneous treatment if extrahepatic disease is deemed curable. Ablation has the additional advantage of being easily repeatable; new or recurrent metastases can be treated or retreated as they are detected. RFA of solitary liver metastases 4 cm or smaller can be performed with minimal morbidity and results in excellent long-term survival, approaching that of surgical resection, even in patients who are not surgical candidates.<sup>[9]</sup> The safety of RFA of subcapsular tumors also seems acceptable, and the effectiveness is comparable to that of RFA of nonsubcapsular tumors.<sup>[10]</sup> Studies demonstrate that RFA significantly improves survival over chemotherapy alone in patients with traditionally unresectable disease, and combination treatment has shown to achieve a 5-year survival rate of 30%.<sup>[3,11]</sup>

CT and MRI are the two most commonly used imaging techniques for surveillance. Several recent studies have suggested that PET is superior to CT or MRI for detecting residual tumor and recurrence after RFA.<sup>[12-17]</sup>

Reur *et al.*<sup>[18]</sup> published the results of the randomized phase II study in 2012 comparing the results of systemic chemotherapy alone vs combined systemic chemotherapy with RFA. Toxicity from systemic treatment was comparable in both the arms. Median progression-free survival (PFS) was 16.8 months vs 9.9 months for combination treatment and chemotherapy alone

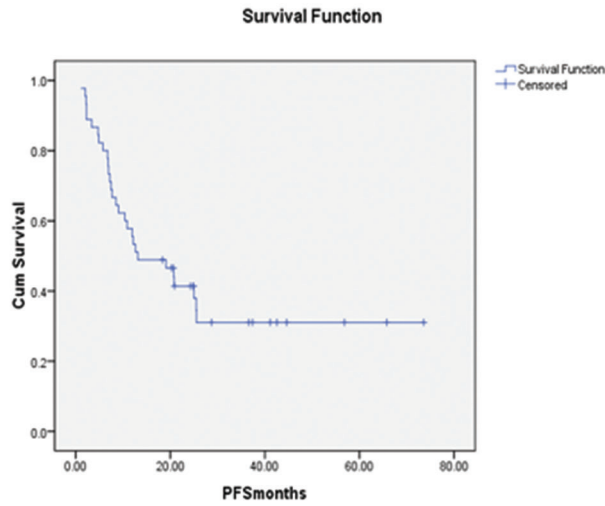


**Figure 2 (A-F):** 48 years male, operated case of Ca rectum, presented with 4.2 x 4.1 cm size solitary segment VII lesion (A), Radiofrequency ablation done using multitined monopolar electrode (B), Post RFA PET CT reveals evidence of small residual lesion along medial margin of the lesion near middle hepatic vein (C), for which patient underwent chemotherapy. PET CT done at 3 months (D) reveals persistent residual disease at periphery of the ablated lesion. Repeat RFA was done for residual disease (E). 3 months post procedure PET CT revealed complete response (F)

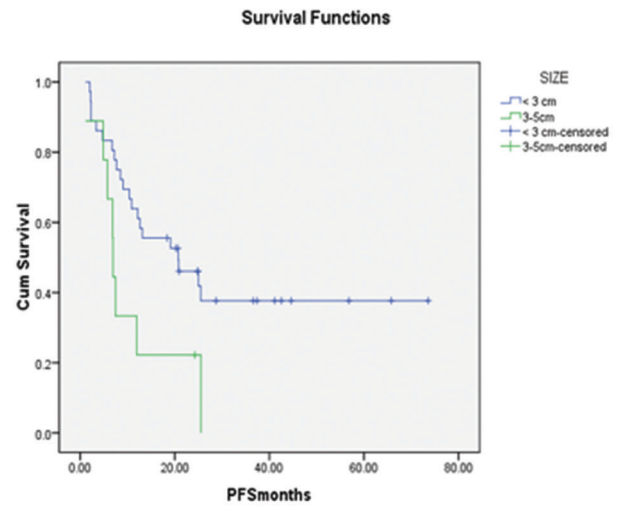
group, respectively. The median PFS was significantly prolonged by RFA plus systemic therapy. However, as the trial was not powered to detect a difference in overall survival (OS), definitive proof of the benefit of RFA on OS could not be estimated. Babawale *et al.*<sup>[19]</sup> in 2015, evaluated the long-term survival of RFA of CRLM performed in 49 patients. Overall 1, 2, 3, 4, and 5-year survival rates were 92%, 65%, 51%, 41%, and 29%, respectively.

The efficiency of RFA reduces with increase in size. Solbiati *et al.*<sup>[20]</sup> in 2012 evaluated local response rate and long-term survival of patients with small CRLM (<4.0 cm; mean: 2.2 cm). Overall survival rates were 98.0%, 69.3%, 47.8%, 25.0%, and 18.0% (median: 53.2 months) at 1, 3, 5, 7, and 10 years, respectively. Local tumor progression occurred in 11.9% (24 of 202) metastases. Failure to achieve tumor control occurred mostly with the largest tumor nodules.<sup>[2]</sup> Even our results confirm that better outcomes are obtained with smaller tumors. Complete response at 3 months was noted in 30/42 patients (71.2%) with lesion less than 3 cm with complete response at 3 months and in 5/10 patients (50%) with lesions measuring 3–5 cm. PFS calculated from the time of RFA was 13.1 months. PFS in patients with <3 cm lesion was 20.7 months vs 6.9 months in patients with 3–5 cm lesion [Table 2A and B]. This difference was statistically significant ( $P$  value = 0.004; Log Rank test for comparison of two groups). Median survival in patients with small lesions (<3 cm) was higher (3.45 years vs 1.51 years) [Table 2C]. In a study published by Siperstein *et al.*<sup>[21]</sup> the number and dominant size of metastases, as well as preoperative carcinoembryonic antigen (CEA) values were strong predictors of survival. Presence of extrahepatic disease ( $P = 0.34$ ) did not alter the median survival.

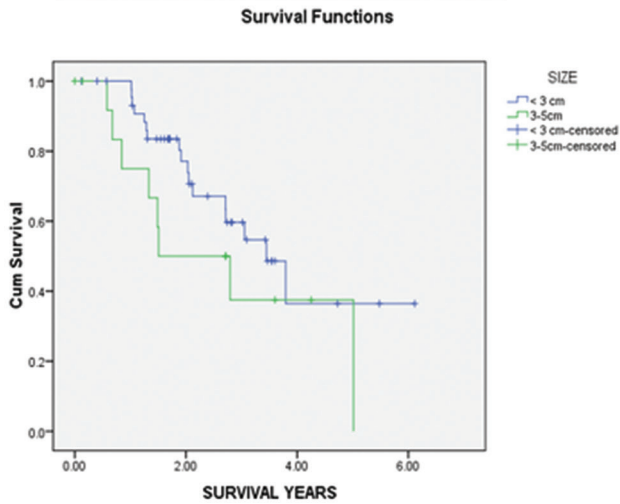
**Table 2: Survival characteristics**



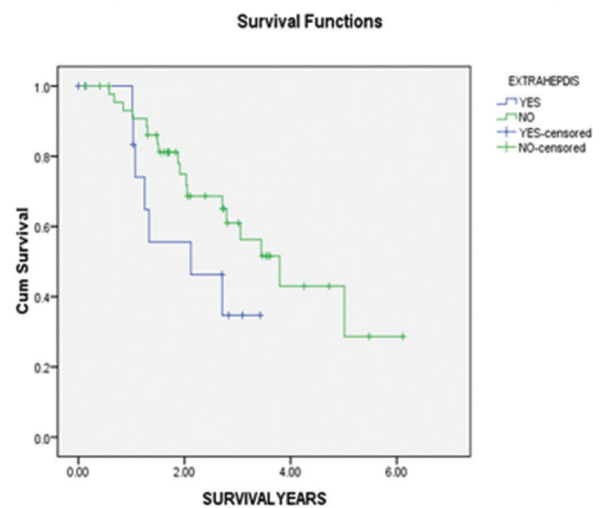
A - Overall Progression free survival



B - PFS <3cm lesion vs 3-5cm lesion



C - Survival- <3cm vs 3-5cm liver lesion.



D-Survival- Liver limited vs Extrahepatic disease

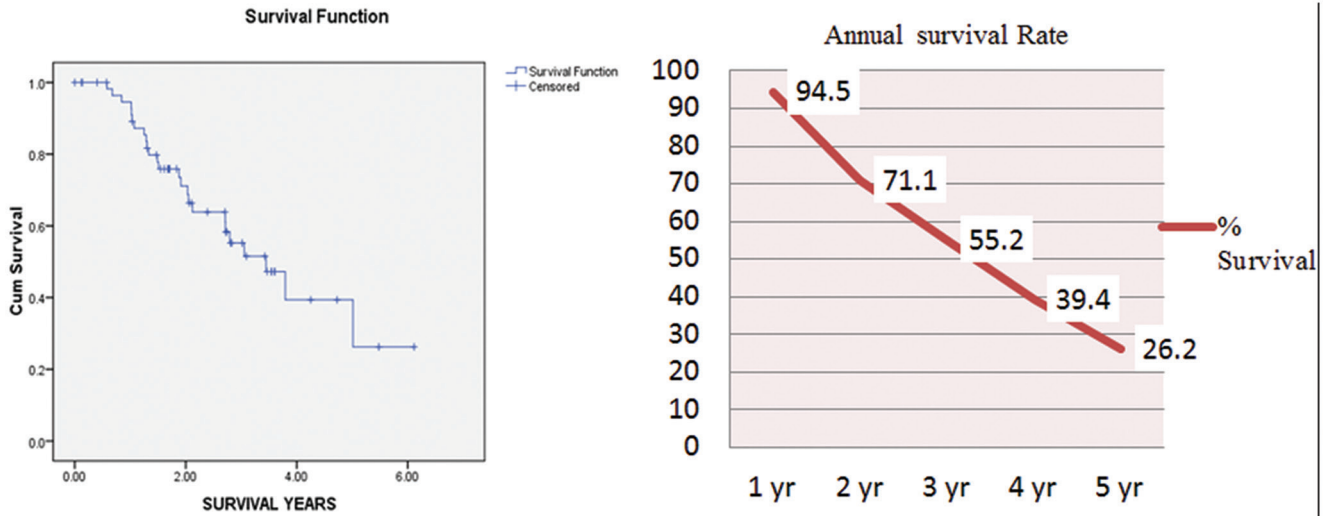
To our knowledge, the data for RFA from low endemic region of CRC is sparse. We analyzed our experience with percutaneous RFA to treat 60 hepatic secondaries from mCRC patients over a period of 7 years. In our study, median survival in patients with liver-limited disease was 3.79 years, whereas in patients with limited extrahepatic disease, survival was 2.12 years [Table 2D]. Treatment failure in a majority of patients was due to new (intra and/or extrahepatic) metastases. Estimated overall median survival using Kaplan–Meier analysis was 3.45 years. Annual survival rates were 94.5%, 55.2%, and 26.2% for 1, 3, 5 years, respectively [Table 3]. Results from our group of population correlated with the trends seen in CRC endemic areas, as reported in various studies [Table 4].

Despite the limitation of this study, being retrospective in nature, our results suggest that RFA is associated with minimal complications and can result in favorable patient outcomes.

### Conclusion

RFA is safe and effective in the treatment of unresectable CRLM. Overall and annual survival rates in patients of unresectable CRLM at our institute from a low endemic region also follows the global trend. Size of the lesion was an important predictor of efficacy of RFA. Presence of extrahepatic disease and lesion size >3 cm were associated with decreased survival.

**Table 3: Kaplan–Meier estimates for overall and annual survival rates**



**Table 4: Comparison with other studies**

Author	No of patients	Annual survival			Overall survival
		1 year	3 year	5 year	
Gilliams <i>et al.</i> 2000	69	90	34	22	27 months
Solbiati <i>et al.</i> 2001	117	93	46	-	36 months
Lencioni <i>et al.</i> 2004	423	86	47	24	-
MacKay <i>et al.</i> 2009	43	97	66	15	31 months
Sorenson <i>et al.</i> 2007	102	96	64	26	52 months
Reur <i>et al.</i> 2012	60	91	55	-	45 months
Babawale <i>et al.</i> 2015	49	92	51	29	28.5 months
Kulkarni <i>et al.</i>	60	94	55	26	41 months

**Financial support and sponsorship**

Nil.

**Conflicts of interest**

There are no conflicts of interest.

**References**

- House MG, Ito H, Gönen M, Fong Y, Allen PJ, DeMatteo RP, et al. Survival after hepatic resection for metastatic colorectal cancer: Trends in outcomes for 1,600 patients during two decades at a single institution. *J Am Coll Surg* 2010; 210(5):744–5.
- de Baere T, Elias D, Dromain C, Din MG, Kuoch V, Ducreux M, et al. Radiofrequency ablation of 100 hepatic metastases with a mean follow-up of more than 1 year. *AJR Am J Roentgenol* 2000;175:1619-25.
- Abdalla EK, Vauthey JN, Ellis LM, Ellis V, Pollock R, Broglio KR et al. Recurrence and outcomes following hepatic resection, radiofrequency ablation, and combined resection/ablation for colorectal liver metastases. *Ann Surg.* 2004;239:818-27.
- Hughes KS, Rosenstein RB, Songhorabodi S, Adson MA, Ilstrup DM, Fortner JG, et al. Resection of the liver for colorectal carcinoma metastases: A multi-institutional study of long-term survivors. *Dis Colon Rectum* 1988;31:1-4.
- Scheele J, Rudroff C, Altendorf-Hofman A. Resection of colorectal

- liver metastases revisited. *J Gastrointestinal Surg* 1997;1:408-22.
- Fong Y, Fortner J, Sun RL, Brennan MF, Blumgart LH. Clinical score for predicting recurrence after hepatic resection for metastatic colorectal cancer: Analysis of 1001 consecutive cases. *Ann Surg* 1999;230:309–18.
- Wagner JS, Adson MA, Van Heerden JA, Adson MH, Ilstrup DM. The natural history of hepatic metastases from colorectal cancer. *Ann Surg* 1984;199:502–7.
- Federica Zoratto, Luigi Rossi, Angelo Zullo, Anselmo Papa Critical appraisal of bevacizumab in the treatment of metastatic colorectal cancer. *Onco Targets Ther.* 2012;5:199-211.
- Gillams AR, Lees WR. Five-year survival following radiofrequency ablation of small, solitary, hepatic colorectal metastases. *J Vasc Interv Radiology.* 2008 May; 19(5):712-7.
- Sergio S, Paola T, Francesca M, Ingrid N, Davide T, Mirella C, et al. Subcapsular Liver Tumors Treated with Percutaneous Radiofrequency Ablation: A Prospective Comparison with Nonsubcapsular Liver Tumors for Safety and Effectiveness. *Radiology* 2008; 248:670-9.
- Machi J, Oishi AJ, Sumida K, Sakamoto K, Furumoto NL, Oishi RH, et al. Long-term outcome of radiofrequency ablation for unresectable liver metastases from colorectal cancer: Evaluation of prognostic factors and effectiveness in first- and second-line management. *Cancer J* 2006;12:318-26.
- Langenhoff BS, Oyen WJ, Jager GJ, Strijk SP, Wobbes T, Corstens FH, et al. Efficacy of fluorine-18-deoxyglucosepositron emission tomography in detecting tumor recurrence after local ablative therapy for liver metastases: A prospective study. *J Clin Oncol* 2002;20:4453-8.
- Bipat S, van Leeuwen MS, Comans EF, Pijl ME, Bossuyt PM, Zwinderman AH, et al. Colorectal liver metastases: CT, MR imaging, and PET for diagnosis- meta-analysis. *Radiology* 2005; 237:123-31.
- Anderson GS, Brinkmann F, Soulen MC, Alavi A, Zhuang H. FDG positron emission tomography in the surveillance of hepatic tumors treated with radiofrequency ablation. *Clin Nucl Med* 2003;28:192-7.
- Donckier V, Van Laethem JL, Goldman S, Van Gansbeke D, Feron P, Ickx B, et al. [F-18] fluoro deoxyglucose positron emission tomography as a tool for early recognition of incomplete tumor destruction after radiofrequency ablation for liver metastases. *J Surg Oncol* 2003; 84:215-23.

16. Chen W, Zhuang H, Cheng G, Torigian DA, Alavi A. Comparison of FDG-PET, MRI and CT for post radiofrequency ablation evaluation of hepatic tumors. *Ann Nucl Med* 2013;27:58-65.
17. Kuehl H, Antoch G, Stergar H, Veit-Haibach P, Rosenbaum-Krumme S, Vogt F, Frilling A, Barkhausen J, Bockisch A. Comparison of FDG-PET, PET/CT and MRI for follow-up of colorectal liver metastases treated with radiofrequency ablation: Initial results. *European Journal of Radiology*. 2008 Aug; 67(2):362-71.
18. Ruers T, Punt C, Van Coevorden F, Pierie JP, Borel-Rinkes I, Ledermann JA, *et al.* Radiofrequency ablation combined with systemic treatment versus systemic treatment alone in patients with non-resectable colorectal liver metastases: A randomized EORTC intergroup phase II study (EORTC 40004). *Ann oncol* 2012; 23:2619-26.
19. Babawale SN, Jensen TM, Frokjaer JB. Long-term survival following radiofrequency ablation of colorectal liver metastases: A retrospective study. *World J Gastrointest Surg*. 2015 Mar 27; 7(3):33-8.
20. Solbiati L, Ahmed M, Cova L, Ierace T, Brioschi M, Goldberg SN, *et al.* Small liver colorectal metastases treated with percutaneous radiofrequency ablation: Local response rate and long-term survival with up to 10-year follow-up. *Radiology*. 2012 Dec; 265(3):958-68.
21. Siperstein AE, Berber E, Ballem N, Parikh RT. Survival after radiofrequency ablation of colorectal liver metastases: 10-year experience. *Annals of Surgery* 2007;246:559-65.