

# Portal vein thrombosis after donor liver biopsy: Case report

Shahnawaz Bashir, Kartik Mittal, Rohit Khisti, Ankusha Yadav, Amar Mukund, Viniyendra Pamecha<sup>1</sup>

Departments of Interventional Radiology, <sup>1</sup>Liver Transplantation and Hepato-Pancreatico-Biliary Surgery, Institute of Liver and Biliary Sciences, Vasant Kunj, New Delhi, India

**Correspondence:** Dr. Amar Mukund, Department of Interventional Radiology, Institute of Liver and Biliary Sciences, Vasant Kunj - 110 070, New Delhi, India. E-mail: dramarmukund@gmail.com

## Abstract

Percutaneous plugged liver biopsy is a safe procedure with a low complication rate. Portal vein thrombosis has not been reported after percutaneous liver biopsy in the literature. We present a case of portal vein thrombosis after percutaneous plugged liver biopsy in a voluntary liver donor, which was subsequently treated with catheter-directed percutaneous transhepatic thrombolysis. In future, healthy patients undergoing liver biopsies are expected to increase for donor evaluation. More refinements of technique and hardware in the future may further decrease the rate of complications. However, if they occur, they need to be recognized and managed at the earliest.

**Key words:** Liver biopsy; portal vein thrombosis; Thrombolysis

## Introduction

Ultrasound-guided percutaneous liver biopsy (LB) is an important diagnostic tool in the work-up of patients and donors with suspected diffuse liver diseases, in known hepatitis patients for treatment monitoring and staging of disease, and for diagnostic clarification of hepatic lesions. The reported complication rate after LB is low, and to our knowledge, portal vein thrombosis (PVT) has not been reported after LB. Here, we present a voluntary liver donor who developed PVT after plugged LB, and was successfully treated with catheter-directed transhepatic thrombolysis.

## Case Report

Our institutional review board does not require approval publishing case reports. Written informed consent was obtained from the patients for all the procedures.

A 24-year male who was a prospective liver donor for his mother was referred to us for percutaneous LB. The indication of LB was a suspicion of parenchymal liver disease, as suggested by the widening of inter-lobar fissure of liver on contrast-enhanced computed tomography (CT) examination [Figure 1A and B], which also showed normal portal veins [Figure 2A and B]. Ultrasound-guided plugged liver biopsy was planned under local anesthesia. Baseline platelet count was  $389 \times 10^9/L$ , hemoglobin level was 14.3 mg/dl, and prothrombin time and INR were 13.0 s and 1.01, respectively. Local anesthesia was administered by infiltration of 10 ml of 2% xylocaine hydrochloride. A Quick-core biopsy needle set (Cook, Bloomington, IN, USA) containing coaxial needle (16 Gauge, 12 cm long) and core biopsy needle (18 Gauge, 15 cm long with 2 cm specimen notch) was used to obtain tissue core. The coaxial needle was inserted from the right intercostal approach. Through the coaxial needle, the biopsy needle

This is an open access journal, and articles are distributed under the terms of the Creative Commons Attribution-NonCommercial-ShareAlike 4.0 License, which allows others to remix, tweak, and build upon the work non-commercially, as long as appropriate credit is given and the new creations are licensed under the identical terms.

**For reprints contact:** reprints@medknow.com

**Cite this article as:** Bashir S, Mittal K, Khisti R, Yadav A, Mukund A, Pamecha V. Portal vein thrombosis after donor liver biopsy: Case report. Indian J Radiol Imaging 2018;28:61-4.

### Access this article online

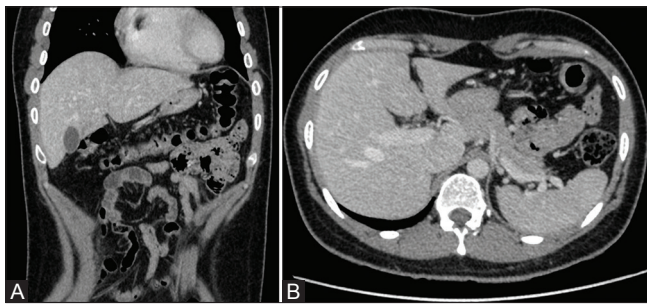
#### Quick Response Code:



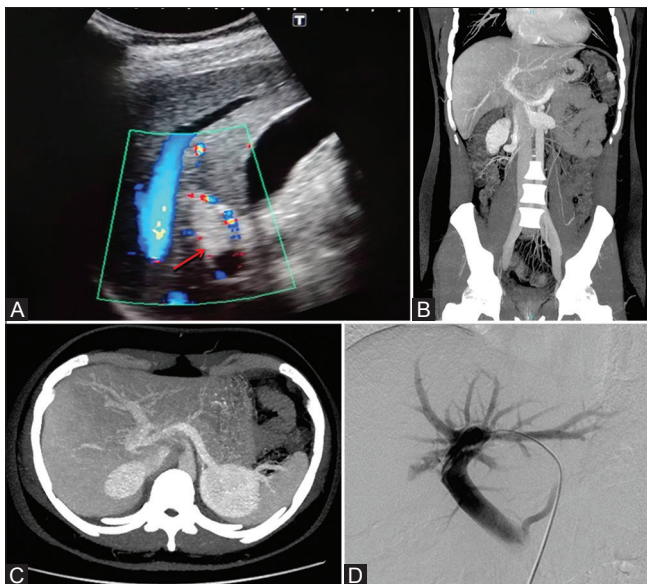
**Website:**  
www.ijri.org

**DOI:**  
10.4103/ijri.IJRI\_26\_17

was inserted and a single tissue core was obtained. The biopsy needle was removed while the coaxial needle was left in place. This was followed by the injection of gelfoam (Spongostan standard, Ferrosan, Denmark) slurry through the coaxial needle to plug the parenchymal track under real-time ultrasound guidance. Post biopsy, the patient was asked to lie on his right side for approximately 4 h. Later, the patient was discharged after a routine screening ultrasonography, which was unremarkable. Two weeks later, the patient presented with mild right upper quadrant pain. Ultrasound of the abdomen revealed echogenic thrombus completely occluding the right portal vein [Figure 3A]. Contrast-enhanced CT scan of upper abdomen confirmed right portal vein occlusion [Figure 3B and C]. The patient was started on oral antiplatelets and anticoagulants for 1 week, however, there was no resolution of the thrombus on repeat ultrasound and Doppler scan. Because the donor was symptomatic with thrombus in



**Figure 1 (A and B):** (A and B) Hepatic venous phase contrast CT coronal and axial images show subjective widening of the interlobar fissure of the liver



**Figure 3 (A-D):** (A) USG image showing echogenic thrombus in the right portal vein (arrow) with absence of flow on color Doppler. (B and C) Coronal and axial MIP contrast-enhanced image shows absent contrast filling of the right portal system. (D) Portovenogram image from DSA shows nonopacification of the right portal system with irregular filling defects in the right portal vein

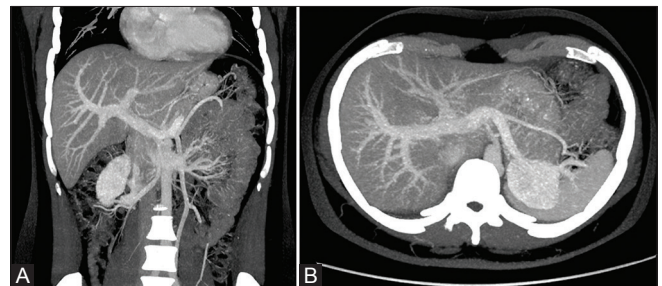
subacute stage, percutaneous endovascular intervention appeared to be the best option for his treatment.

Under ultrasound guidance, percutaneous puncture of the left portal vein was done using a 22-gauge micropuncture needle. Using NEFF set (Cook, Bloomington, IN, USA), a 0.035" J tip guide wire was introduced into the portal vein and exchanged for a 5F KMP catheter (Cook, Bloomington, IN, USA). Digital subtraction angiogram (DSA) of the portal system was obtained which also confirmed the right portal vein occlusion [Figure 3D]. Using multi-sideport catheter infusion set (Cook, Bloomington, IN, USA), urokinase bolus (50,000 units) were given in a pulse spray method. A check angiogram revealed unsatisfactory results. A continuous infusion of urokinase (30,000 units/h) was started for the next 24 h. Repeat angiogram next day showed restoration of the blood flow in the right portal vein [Figure 4A and B]. The procedure ended with coil embolization of the liver parenchymal track to reduce the chances of hemorrhage.

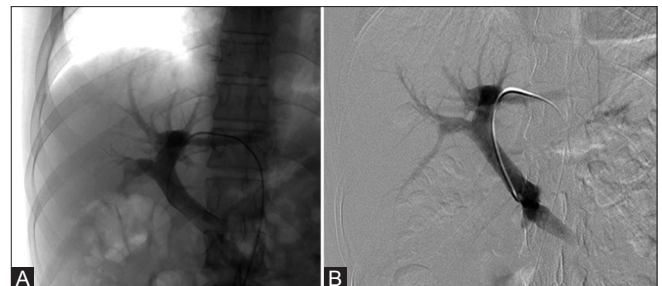
A through work-up of coagulation disorders [Table 1] revealed a raised homocysteine level (32.2  $\mu\text{mol/l}$  (normal range, 5–15  $\mu\text{mol/L}$ ). The biopsy report revealed a normal liver histology which ruled out any parenchymal liver disease.

## Discussion

LB in donor selection for living donor liver transplant (LDLT) is sometimes required after initial donor screening. In



**Figure 2 (A and B):** (A and B) Note that the pre-biopsy CT scan images in portal venous phase (maximum intensity projection, coronal and axial images) show normal portal vein contrast opacification



**Figure 4 (A and B):** (A and B) Portal venogram after thrombolysis showing restoration of blood flow in the right portal system

**Table 1: Laboratory evaluation of hypercoagulability**

Test name	Value	Reference range
Homocysteine	32.5	5-15 $\mu$ mol/L
Protein C	157.1%	70-140%
Protein S	62.1%	60-130%
Antithrombin III functional	84.8%	75-125%
Factor V Leiden mutation	Negative	-
MTHFR T allele	Heterozygous	-
Prothrombin A allele	Negative	-
JAK2 V 617F mutation	Negative	-

general, LB is safe and confers minimal risk of complications. Major and minor complication rates of 0.8% and 2–3.8%, respectively, have been reported in the literature.<sup>[1,2]</sup> These complications may vary from minor symptoms and events, such as pain and transient hypotension, to major complications, including hemorrhage, puncture of hollow viscus, inadvertent biopsy of the kidney or pancreas, and intrahepatic arteriovenous fistula formation.<sup>[3,4]</sup> The mortality rate from LB is reported to range from 0.01% to 0.1%.<sup>[4,5]</sup> To our knowledge, PVT has not been reported as a complication of LB. Because the patient had increased homocysteine levels, we assumed that the patient's inherent procoagulant status should have been the primary reason for PVT. However, because only the right portal vein thrombosed and the biopsy was taken from the right lobe with injection of gel foam slurry in the same lobe, we also assumed that possible migration or inadvertent injection of gel foam slurry into the portal vein may also have contributed in the formation of the portal vein thrombus. After this case, we have reduced the volume of the gel foam slurry used for track embolization after liver biopsies from 1.5–2 ml to 0.5–1 ml. This might prevent or reduce the amount of gel foam migration from the parenchyma into the vessels.

The most common etiologies for PVT are the myeloproliferative diseases, intra abdominal infections or inflammations, septicemia, cirrhosis, intra abdominal surgery, trauma, hypercoagulable states (antithrombin III, protein C, protein S insufficiency, and hyperhomocysteinemia), oral contraceptives, and primary or secondary liver tumors.<sup>[6]</sup> Extension of PVT to the mesenteric venous arches can cause intestinal infarction, which has a reported mortality of up to 50%.<sup>[7]</sup> Early diagnosis and treatment of PVT is crucial for the restoration of portal venous flow and reduction of morbidity and mortality. Treatment options for PVT range from conservative anticoagulant therapy to surgical thrombectomy. Endovascular thrombolytic therapy is a newer alternative technique for the treatment of PVT.<sup>[8-10]</sup>

Percutaneous transhepatic thrombolysis is a safe and effective method for the treatment of acute to subacute

symptomatic PVT who do not respond to medical management. Pulse-spray thrombolysis is a promising approach that takes advantage of the best of both thrombolysis and mechanical thrombectomy. The jets disrupt thrombus as well as deliver the drug, resulting in a shorter lysis time. This method is more effective and less time consuming than normal thrombolytic infusion.<sup>[11]</sup>

## Conclusion

Normal healthy individuals undergoing LB are expected to increase in the future for donor evaluation for LDLT. In general, plugged LB is a safe procedure, which may rarely cause complications. More refinements of the technique and hardware in the future may further decrease the rate of complications. However, if they occur, they need to be recognized and managed at the earliest.

## Declaration of patient consent

The authors certify that they have obtained all appropriate patient consent forms. In the form the patient(s) has/have given his/her/their consent for his/her/their images and other clinical information to be reported in the journal. The patients understand that their names and initials will not be published and due efforts will be made to conceal their identity, but anonymity cannot be guaranteed.

## Financial support and sponsorship

Nil.

## Conflict of interest statement

On behalf of all authors, the corresponding author states that there is no conflict of interest.

## References

- Hatfield MK, Beres RA, Sane SS, Zaleski GX. Percutaneous imaging-guided solid organ core needle biopsy: Coaxial versus non coaxial method. *AJR Am J Roentgenol* 2008;190:413-7.
- Albéniz Arbizu E, López San Román A, García González M, Foruny Olcina JR, García-Hoz Rosales F, Bárcena Marugán R, *et al.* Fibrin-glue sealed liver biopsy in patients with a liver transplantation or in liver transplantation waiting list: Preliminary results. *Transplant Proc* 2003;35:1911-2.
- Janes CH, Lindor KD. Outcome of patients hospitalized with complications after outpatient liver biopsies. *Ann Intern Med* 1993;118:96-8.
- McGill DB, Rakela J, Zinsmeister AR, Ott BJ. A 21-year experience with major hemorrhage after percutaneous liver biopsy. *Gastroenterology* 1990;99:1396-400.
- Piccinino F, Sagnelli E, Pasquale G, Giusti G, Giusti G. Complications following percutaneous liver biopsy. A multicentre retrospective study on 68, 276 biopsies. *J Hepatol* 1986;2:165-73.
- Ozkan U, Oğuzkurt L, Tercan F, Tokmak N. Percutaneous transhepatic thrombolysis in the treatment of acute portal venous thrombosis. *Diagn Interv Radiol* 2006;12:105-7.
- Kumar S, Kamath PS. Acute superior mesenteric venous

thrombosis: One disease or two? *Am J Gastroenterol* 2003;98:1299-304.

8. Kercher KW, Sing RF, Watson KW, Matthews BD, LeQuire MH, Heniford BT. Transhepatic thrombolysis in acute portal vein thrombosis after laparoscopic splenectomy. *Surg Laparosc Endosc Percutan Tech* 2002;12:131-6.
9. Aytekin C, Boyvat F, Kurt A, Yologlu Z, Coskun M. Catheter-directed thrombolysis with transjugular access in portal vein thrombosis secondary to pancreatitis. *Eur J Radiol* 2001;39:80-2.
10. Lopera JE, Correa G, Brazzini A, Ustunsoz B, Patel S, Janchai A, *et al.* Percutaneous transhepatic treatment of symptomatic mesenteric venous thrombosis. *J Vasc Surg* 2002;36:1058-61.
11. Bookstein JJ, Bookstein FL. Augmented experimental pulse-spray thrombolysis with tissue plasminogen activator, enabling dose reduction by one or more orders of magnitude. *J Vasc Interv Radiol* 2000;11:299-303.