

A rare case of neonatal mastaxue: Case report

Bhumika Suthar, Kanishka Aggarwal

Department of Radiodiagnosis, Baroda Medical College, Maharaja Sayajirao University, Vadodara, India

Correspondence: Dr. Kanishka Aggarwal, Department of Radiodiagnosis, S.S.G. Hospital, Vadodara – 390 001, Gujarat, India..
E-mail: kanishka_aggarwal@outlook.com

Abstract

Neonatal breast enlargements have varying number of presentations on imaging and these have been underreported in the literature. Our case report profiles a 2-week-old female who presented with a history of bilateral breast enlargement with redness and clear, non-bloody, milk-like discharge, who was clinically diagnosed and managed for neonatal mastitis, which was actually a neonatal breast enlargement only. Awareness on neonatal breast enlargement that can be just physiological without any associated mastitis or inflammatory/infective changes can prevent unnecessary hospitalization and treatment with parenteral antibiotics.

Key words: Neonatal breast enlargement; neonatal mastaxue; neonatal mastitis

Introduction

Neonatal breast enlargement is a common condition that occurs in both males and females. Maternal hormones, mainly estrogen, are known to cause varying degree of breast enlargement. However, the breast enlargement may not always be associated with infective or inflammatory changes that mandate hospitalization and parenteral antibiotic treatment.

We present a female neonate with bilateral breast enlargement associated with overlying skin discoloration and sonographic appearance of enlarged breast buds with no inflammatory or infective signs within or surrounding it.

Case History

In February 2018, a full term, previously healthy 2-week-old female patient was brought to the pediatric out-patient clinic with bilateral breast enlargement and redness since

birth and history of some clear, nonbloody, milk-like discharge from both the nipples. The prenatal history included normal pregnancy with cesarean section delivery for cord prolapse and no maternal infections during the pregnancy. The neonate was afebrile. Her vital signs were stable. Bilateral breast examination showed a palpable, nontender, subareolar mass with mild redness of the overlying skin [Figure 1]. No nipple discharge was noted. Laboratory results for cell count showed no evidence of sepsis. Blood sample was sent for culture and sensitivity. Since there was no nipple discharge at examination, culture of the discharge was not performed. Her C-reactive protein was within normal limits. Based on the clinical findings of bilateral breast swelling with overlying skin redness, the neonate was admitted for management of neonatal mastitis and started on parenteral amoxicillin clavulanate and amikacin. Ultrasonography of the left breast 1 day after hospitalization demonstrated a retroareolar heterogeneously hypoechoic lesion measuring 2.9 × 2.1 cm with anechoic areas and internal septations/echogenic

This is an open access journal, and articles are distributed under the terms of the Creative Commons Attribution-NonCommercial-ShareAlike 4.0 License, which allows others to remix, tweak, and build upon the work non-commercially, as long as appropriate credit is given and the new creations are licensed under the identical terms.

For reprints contact: reprints@medknow.com

Cite this article as: Suthar B, Aggarwal K. A rare case of neonatal mastaxue: Case report. Indian J Radiol Imaging 2019;29:89-93.

Access this article online

Quick Response Code:



Website:
www.ijri.org

DOI:
10.4103/ijri.IJRI_317_18

strands with no internal vascularity within and adjacent soft tissue hyperechogenicity. Sonography of the right breast showed a retroareolar mass measuring 2.8×2.0 cm with sonographic features similar to the left breast mass [Figures 2-5]. No loculated fluid collections or signs of inflammations were seen in either breast mass. The blood culture showed no growth of bacteria or yeast. The patient was discharged on the fourth day of hospitalization and asked to follow up after 2 months. Reduction in size of bilateral breast masses was noted on follow-up scans [Figures 6-10].

Discussion

The embryology of breast development involves the precursor of breast originating as early as 6 weeks of intrauterine life.^[1] Neonatal breast enlargement is the benign proliferation of glandular tissue. The crossing of

estrogens across the placenta into the fetal circulation or a normal response to dropping estrogen levels in the maternal circulation toward the end of pregnancy, which may trigger the secretion of prolactin from the neonate's pituitary gland, is considered as a etiological factor.^[2-4]

Neonatal breast enlargement is asymptomatic or physiological in 60%–90% of cases and can be unilateral or bilateral, more frequently bilateral.^[4,5] It usually presents in the first week of life and resolves spontaneously within 6 months of age but may take longer in some babies.^[2] Less often, there can be some liquid secretion from an enlarged breast, called the witch's milk, which may disappear with time without treatment.^[2,3] This nipple discharge can be bloody at times due to mammary duct ectasia. Witch's milk resembles the composition of maternal milk.^[6] Galactocele (stagnation of milk) formation secondary to inadequate let out of milk due to either improper canalization of lactiferous ducts or lack of oxytocin stimulus

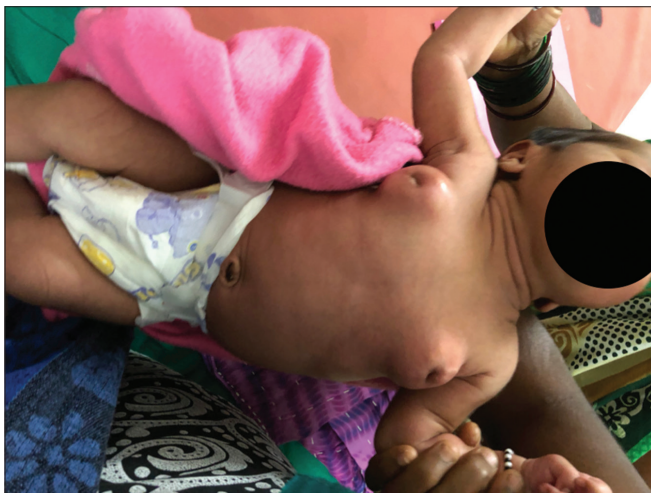

Figure 1: Clinical image of the neonate with bilateral breast enlargement and reddish skin discoloration

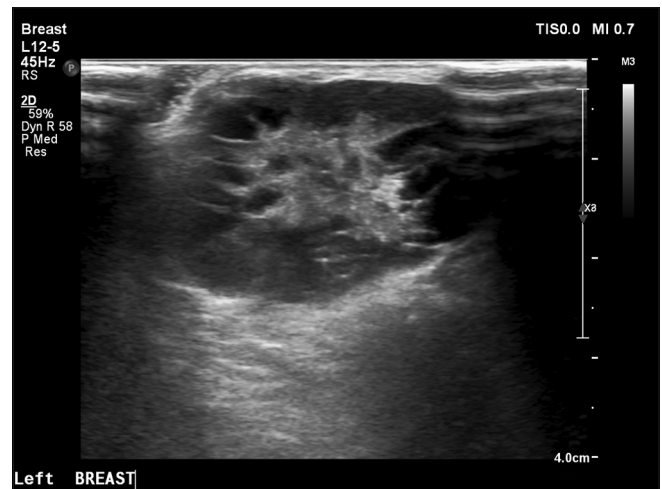

Figure 2: Left breast bud which shows a heterogeneously hypoechoic lesion with few anechoic areas within and echogenic strands radiating from the retroareolar region

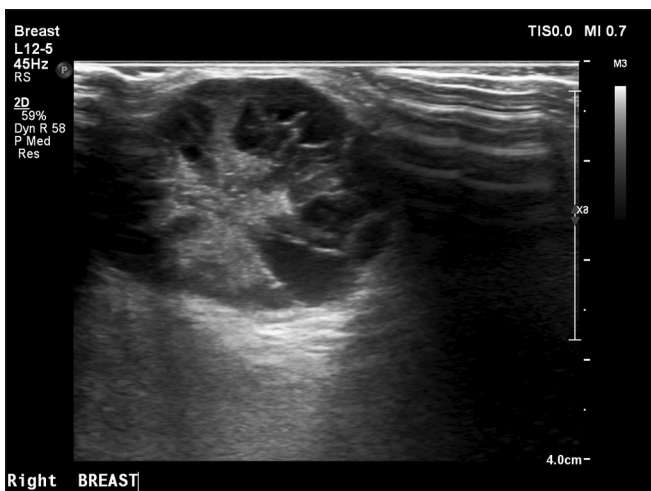

Figure 3: Right breast bud which shows a heterogeneously hypoechoic lesion with few anechoic areas within and echogenic strands radiating from the retroareolar region

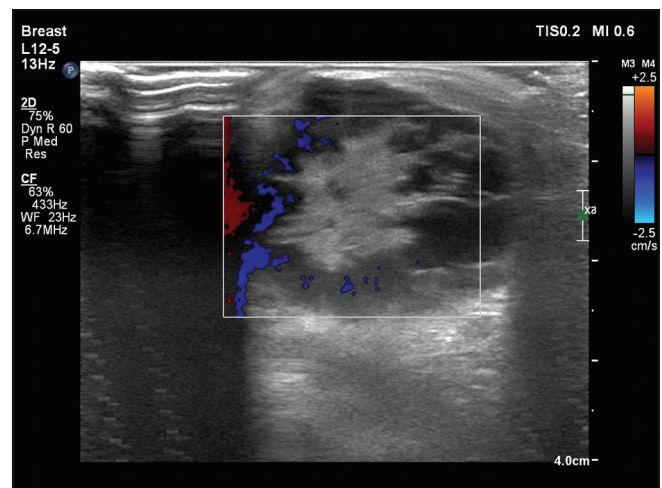


Figure 4: The lesion in left breast does not show any internal vascularity

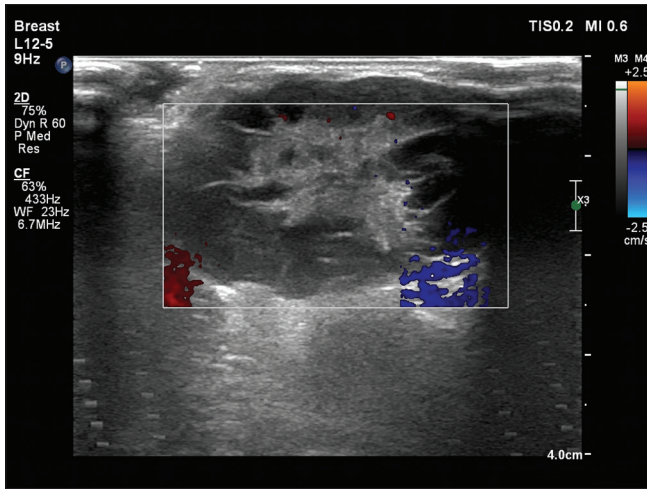


Figure 5: The lesion in right breast does not show any internal vascularity

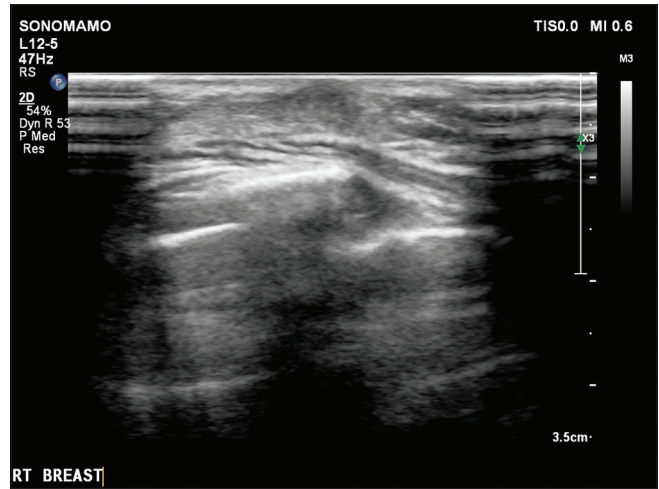


Figure 6: Follow-up ultrasound of the patient after 2 months that shows the right breast tissue appears hypoechoic with reduction in size compared with the previous scan

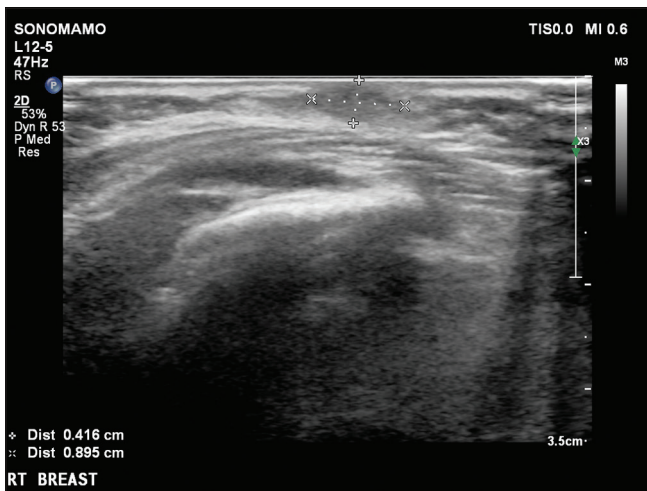


Figure 7: Ultrasound of the right breast shows that the nipple appears iso- to hypoechoic measuring 0.8 × 0.4 cm

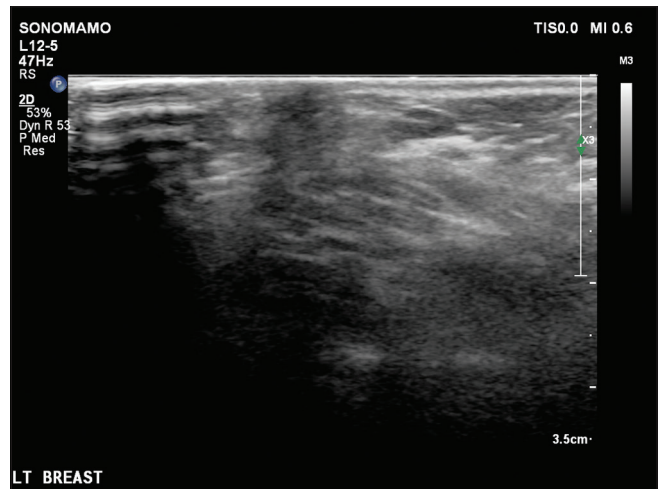


Figure 8: Follow-up ultrasound of the patient after 2 months that shows the left breast tissue appears hypoechoic with reduction in size compared with the previous scan

in the newborn may occur. Complications like breast abscess and mastitis may occur secondary to superadded infections.^[7]

Mastaxe is a combination of two Greek words mastos (Breast) and auxein (increase in size). It is used to describe uncomplicated physiological breast enlargement (breast bud diameter ≤ 3 cm) of newborn under hormonal influence. The terms “neonatal mastitis,” “neonatal breast abscess,” and “neonatal galactocele” are used to denote the complications of “neonatal mastaxe.” Exaggerated breast enlargement (breast bud diameter >3 cm) maybe referred to as “giant mastaxe.”^[4]

The breast bud at origin appears as a retroareolar or subareolar hypoechoic tissue relative to the fat on ultrasound.^[1,4] The usual sonographic appearances of neonatal breast enlargement are that of a hypoechoic retroareolar tissue or hyperechoic retroareolar nodule with

central star-shaped or liner hypoechoic areas representing simple branched ducts.^[8]

Management of neonatal breast enlargement mainly involves simple observation and reassurance to the parents as the breast tissue involutes and resolves by its own.^[4,8] Breast tissue expression may stimulate further growth of the breast as well as complications, such as mastitis and breast abscess; therefore, it should be highly discouraged.

Neonatal mastitis is an infection of breast tissue, commonly seen in full-term infants, since premature infants have underdeveloped breasts that are unlikely to get infected.^[9] It usually occurs in neonates below 5 weeks of age with peak incidence at 3 weeks of age.^[4,10-12] It is mostly unilateral with no predilection

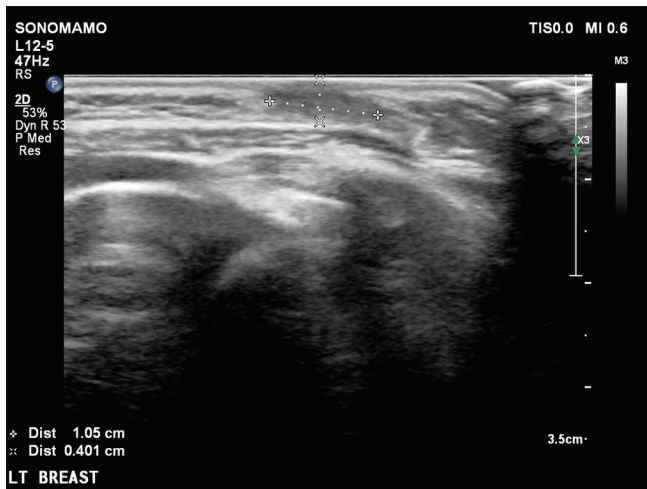


Figure 9: Ultrasound of the left breast shows the nipple appears iso- to hypoechoic measuring 1.0 × 0.4 cm

for right or left breast. In the first 2 weeks of life, it is found in equal frequency in males and females, but after 2 weeks of life, it is twice more likely in female infants. *Staphylococcus aureus* is the most common causative organism (83%–88%).^[4,12] The pathogens colonizing in the skin of the breast, nipple, and mucous membranes enter through the nipple and mammary ducts to reach the breast, which is engorged under the influence of maternal hormones. However, if the causative organism is a Gram-negative bacteria, hematogenous spread is likely to occur.^[10,12] Neonatal mastitis typically presents with unilateral swelling, erythema, warmth, tenderness, and induration in the absence of systemic signs of infection. Occasionally, surrounding skin changes and axillary lymph node involvement can occur.^[9,12]

A full sepsis work up should be done including blood and nipple discharge culture and sensitivity as well as breast sonography. Current recommendation for neonatal mastitis involves initial parenteral antibiotic use with good coverage for *S. aureus*.^[9] If left untreated, mastitis can progress to abscess formation and rarely lead on to cellulitis, fasciitis, osteomyelitis, brain abscess, and generalized sepsis.^[4,10]

Borders *et al.* has described the sonographic appearance of neonatal mastitis as either poorly marginated hyperechoic breast tissue with hypervascularity or as masses with mixed echotexture and internal vascularity. Surrounding hypervascular, hyperechoic subcutaneous fat was seen in all four patients. One of their patients developed a breast abscess which had a prior appearance of a mass with mixed echogenicity and now appeared hyperechoic and avascular. Based on the sonographic findings of another patient with breast abscess, they suggest that neonatal mastitis can be differentiated from neonatal breast abscess by the presence of increased

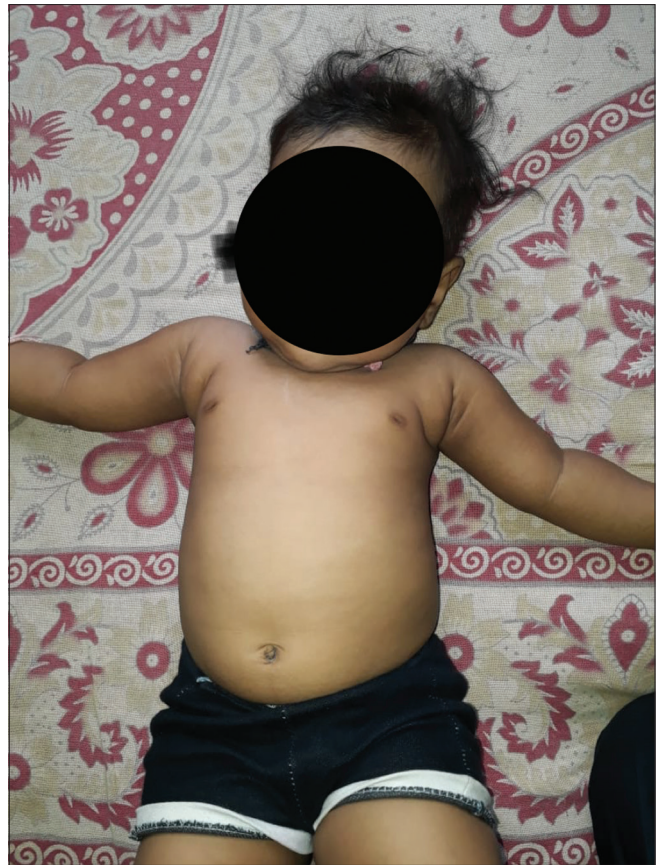

Figure 10: Clinical image of the patient after 2 months

peripheral vascularity that they saw surrounding a cystic breast mass.^[10]

In our case, ultrasound demonstrated retroareolar heterogeneously hypoechoic lesion with anechoic cystic areas and internal septations with no internal vascularity within and adjacent soft tissue hyperechogenicity in bilateral breasts. No loculated fluid collections or signs of inflammations were seen in either breast.

On follow-up scan after 2 months, reduction in the size of bilateral breasts was noted.

Therefore, enlarged neonatal breasts that show no signs of inflammation on ultrasound should be treated as physiological enlargement of neonatal breasts and not to be confused with neonatal mastitis. This shall prevent unnecessary administration of parenteral antibiotics. It is a benign condition in neonates and requires simple two monthly follow-ups with parental reassurance as the breast tissue involutes and resolves by its own eventually.

Declaration of patient consent

The authors certify that they have obtained all appropriate patient consent forms. In the form the patient(s) has/have given his/her/their consent for his/her/their images and

other clinical information to be reported in the journal. The patients understand that their names and initials will not be published and due efforts will be made to conceal their identity, but anonymity cannot be guaranteed.

Financial support and sponsorship

Nil.

Conflicts of interest

There are no conflicts of interest.

References

- Weinstein SP, Conant EF, Orel SG, Zuckerman JA, Bellah R. Spectrum of US findings in pediatric and adolescent patients with palpable breast masses. *Radiographics* 2000;20:1613-21.
- Amer A, Fischer H. Images in clinical medicine. Neonatal breast enlargement. *N Engl J Med* 2009;360:1445.
- Arca MJ, Grewal H. Pediatric breast disorders. 2016. Available from: <https://emedicine.medscape.com/article/935410-overview>.
- Raveenthiran V. Neonatal mastauxe (breast enlargement of the newborn). *J Neonatal Surg* 2013;2:31.
- Johnson RE, Murad MH. Gynecomastia: Pathophysiology, evaluation, and management. *Mayo Clin Proc* 2009;84:1010-5.
- Yap PL, Mirtle CL, Harvie A, McClelland DB. Milk protein concentrations in neonatal milk (witch's milk). *Clin Exp Immunol* 1980;39:695-7.
- Rudoy RC, Nelson JD. Breast abscess during the neonatal period. A review. *Am J Dis Child* 1975;129:1031-4.
- Chung EM, Cube R, Hall GJ, González C, Stocker JT, Glassman LM. From the archives of the AFIP: Breast masses in children and adolescents: Radiologic-pathologic correlation. *Radiographics* 2009;29:907-31.
- Sloan B, Evans R. Clinical pearls: Neonatal breast mass. *Acad Emerg Med* 2003;10:269-70.
- Borders H, Mychaliska G, Gebarski KS. Sonographic features of neonatal mastitis and breast abscess. *Pediatr Radiol* 2009;39:955-8.
- Faden H. Mastitis in children from birth to 17 years. *Pediatr Infect Dis J* 2005;24:1113.
- Stauffer WM, Kamat D. Neonatal mastitis. *Pediatr Emerg Care* 2003;19:165-6.