

CASE REPORT

Multimodality imaging features of primary breast lymphoma - A rare entity

Vinay Maurya, Giriraj Singh, Birma Ram, Prosenjit Ganguli¹

Department of Radiology, Command Hospital, ¹Department of Pathology, Command Hospital, Kolkata, West Bengal, India

Correspondence: Dr. Giriraj Singh, Department of Radiology, Command Hospital, Kolkata, West Bengal, India. E-mail: girigujral@gmail.com

Abstract

Primary lymphoma of breast is very rare which has no tell-tale imaging characteristics. Multimodality imaging helps not only in suggesting the possibility of lymphoma but also in its management. We present here one such case which was extensively worked up with various imaging modalities and was histologically proven as primary breast lymphoma.

Key words: Mammography; magnetic resonance imaging; primary breast lymphoma; ultrasound

Introduction

The most common malignant lesion presenting as lump in the breast is carcinoma breast, and the most common benign lesion affecting the breast is fibroadenoma. Primary lymphoma as a cause of lump breast is very rare and accounts for about 0.4%–0.7% of all neoplastic lesions of breast.^[1] Primary lymphoma of the breast has no tell-tale imaging characteristics, but the possibility of lymphoma should be considered if the lesion looks high grade but does not fit into classical description of carcinoma breast. We present here one such case which presented as diagnostic dilemma on imaging.

Case History

A 48-year-old postmenopausal lady presented with history of enlargement of the right breast since the past 1 month which was painless. She felt heaviness and vague lump in the right breast and noticed scanty watery discharge 10 days before she presented to the hospital. There was no history of trauma, fever, or weight loss. There was no family history of carcinoma breast in immediate

relatives. On general examination, her vitals were stable, and there was no generalized lymphadenopathy or organomegaly. Local examination revealed asymmetrical enlargement of the right breast with ill-defined palpable lump of approximately 9 × 10 cm in size, which was firm in consistency. The overlying skin and nipple areolar complex were normal. Her laboratory investigations including the total and differential leucocyte counts were normal. Mammography was done, and it showed well-defined round hyperdense mass lesion measuring 10 × 6 × 9 cm in the superolateral quadrant, there was no architectural distortion of adjacent breast parenchyma or any micro- or macrocalcification [Figure 1A and B]. There was right axillary lymphadenopathy with loss of fatty hilum (arrow). Ultrasound (USG) of breast revealed a large hyperechoic lesion in the right breast with multiple round to oval hypoechoic nodules [Figure 2A]. The right axillary nodes were enlarged, round, hypoechoic, and showed loss of normal fatty hilum or slit-like configuration of hilum [Figure 2B and C]. Based on mammography and breast USG imaging, diagnosis of BI-RADS IV lesion (breast imaging reporting and data system) with possibility

This is an open access journal, and articles are distributed under the terms of the Creative Commons Attribution-NonCommercial-ShareAlike 4.0 License, which allows others to remix, tweak, and build upon the work non-commercially, as long as appropriate credit is given and the new creations are licensed under the identical terms.

For reprints contact: reprints@medknow.com

Cite this article as: Maurya V, Singh G, Ram B, Ganguli P. Multimodality imaging features of primary breast lymphoma – A rare entity. Indian J Radiol Imaging 2019;29:85-8.

Access this article online

Quick Response Code:



Website:
www.ijri.org

DOI:
10.4103/ijri.IJRI_344_18

of phyllodes tumor was given. Following this, USG-guided trucut biopsy of the mass was done. Histopathological examination revealed diffuse sheets of large pleomorphic malignant lymphoid cells. These cells had high N:C ratio with scant cytoplasm, vesicular nuclei, and inconspicuous nucleoli which were CD45- and CD20-positive. Proliferation index by Ki-67 was high >90%; the findings were suggestive of diffuse large B-cell lymphoma (DLBL) (high grade) [Figure 3].

Thereafter, magnetic resonance imaging (MRI) of breast was done to screen the contralateral breast and to detect any other similar smaller lesions. MRI showed a solitary well-defined, smoothly marginated lesion measuring 10 × 5.4 × 9 cm (AP × TR CC) in size which was iso- to hypointense on T1W and hyperintense on short TI inversion recovery (STIR) sequence with few hypointense nodules [Figure 4A and B]. On dynamic contrast MRI study, the mass showed enhancement with hyper-enhancing

nodules. There was early enhancement with plateau followed by slow washout of contrast on time-intensity curve (type 2 kinetic curve) [Figure 4C and D].

Positron emission tomography/computed tomography (PET/CT) was done to stage the disease. It showed well-defined rounded large soft tissue density mass with increased 2-fluorodeoxyglucose (FDG) uptake in the mass (SUV_{max} of 9.4) (standardized uptake value) and right axillary nodes [Figure 5]. No uptake of radiotracer was seen in any other lymph nodal groups.

Discussion

Involvement of breast in lymphoma can be primary or secondary to metastatic disease process. Pathological criteria for diagnosis of primary breast lymphoma (PBL) given by Wiseman and Liao are presence of lymphoma cells in breast tissue in a patient with no history of earlier or simultaneous lymphoma at another site; however, involvement of ipsilateral axillary lymph nodes may be seen.^[2]

The majority of PBL are of the non-Hodgkin's lymphoma type with most cases of B-cell lineage, with 60% being the

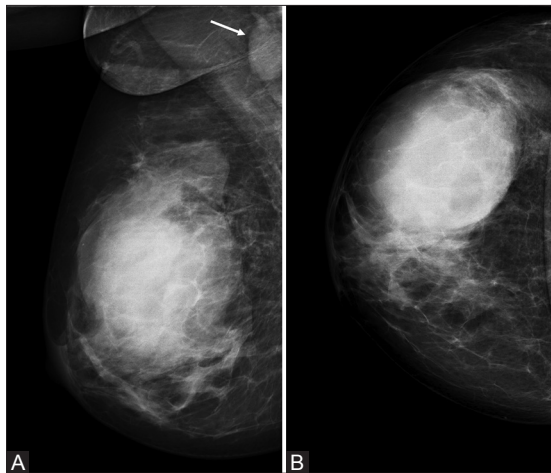


Figure 1 (A and B): (A) MLO and (B) CC view of right breast showing well-defined large hyperdense mass in the superolateral quadrant without architectural distortion. Note the enlarged node in the right axilla (arrow)

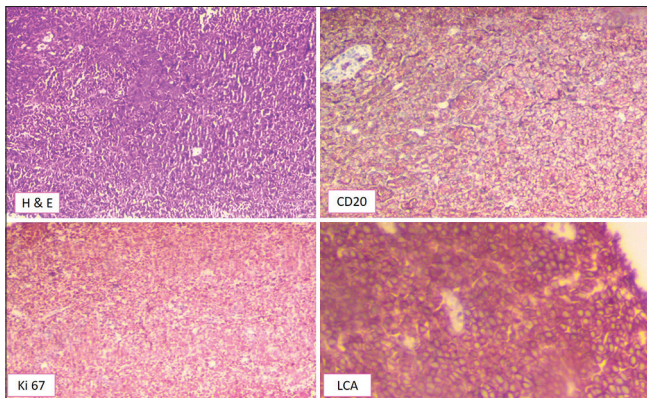


Figure 3: Histopathological examination showed a diffuse growth pattern of medium to large lymphoid cells with vesicular chromatin and inconspicuous nucleoli (H and E). These lymphoid cells were positive for CD45 and CD20 and negative for ER, PR, and CK

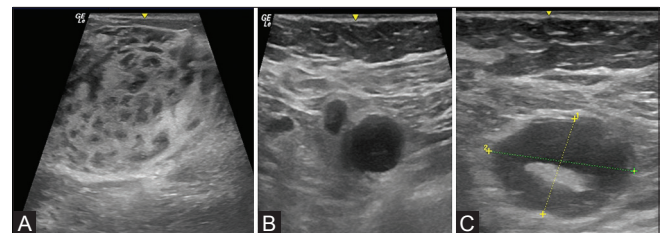


Figure 2: (A-C) (A) Ultrasound showing a large hyperechoic lesion in the right breast with multiple round to oval hypoechoic nodules. (B) Round, hypoechoic, enlarged axillary nodes with loss of normal fatty hilum, and (C) a few nodes with slit-like configuration of hilum

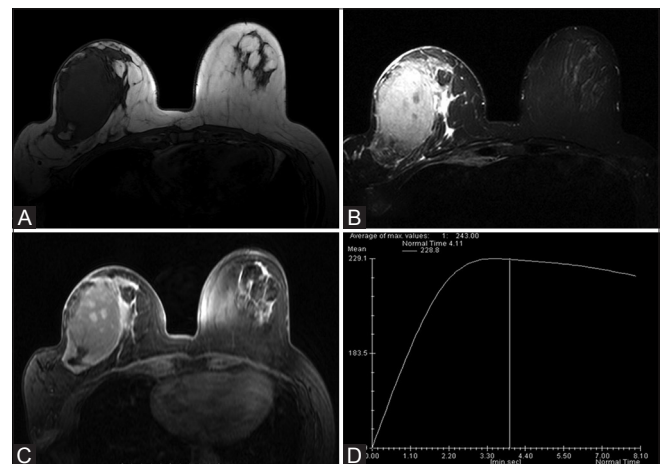


Figure 4 (A-D): MRI of breast showing a well-defined, smoothly marginated mass in right breast iso- to hypointense on T1W (A) and hyperintense on STIR with few hypointense nodules (B). On dynamic contrast study, the lesion shows heterogeneous enhancement (C) with plateau and slow washout of contrast in time-intensity curve (D)

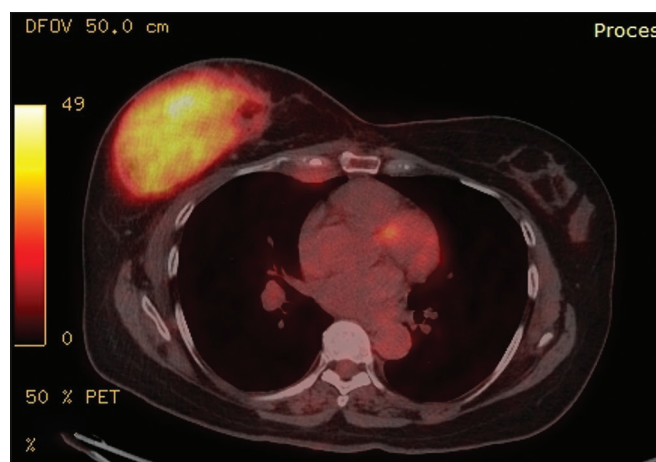


Figure 5: PET/CT image showing increased FDG uptake in the mass in the right breast with SUV_{max} of 9.4

diffuse large B-cell type.^[3] Most of the affected patients present in their fifth or sixth decade of life. Clinically, it presents with painless lump in the breast or in some cases as asymmetric enlargement of the breast as was seen in this case.

The basic work-up of any lump breast includes mammography and USG of the breast. There are no pathognomonic imaging features of PBL on mammography; however, findings such as solitary mass with well-defined margins, lack of micro- or macrocalcification, and absence of distortion of the normal breast architecture with axillary lymphadenopathy should raise the suspicion of PBL.^[4] This case had typical mammographic features of PBL such as well-circumscribed large mass, absent calcification, preserved breast architecture, and axillary adenopathy [Figure 1]; however, these features are nonspecific and the diagnosis of PBL cannot be made on the basis of mammographic findings alone.

The most common USG feature of PBL has been described as a solitary round or oval hypoechoic mass. Other findings which can be seen in PBL are heteroechoic mass with ill-defined margins or masses with an echogenic center and surrounding hypoechoic. Surov *et al.*^[5] in their study found 67% of the lesions to be oval in shape, 15% were anechoic, 46% were hypochoic, and mixed echogenicity was seen in 39% with posterior enhancement noted in 52% of the lesions. The USG in our case showed an echogenic mass which merged with the normal breast tissue and had multiple round to oval hypoechoic areas within [Figure 2A]; these focal round to oval lesions are akin to lymphoma deposits seen in other organs such as spleen or liver. This round to oval hypoechoic lymphoma deposits in breast have not been described in literature; more studies will be required before it can be considered specific for PBL, although this USG characteristic is not seen in any other breast lump. The USG also showed

multiple enlarged ipsilateral axillary nodes; these nodes had variable appearance with round to oval shape and appeared hypochoic; a few showed loss of normal fatty hilum, whereas others showed slit-like appearance of hilum. Metastatic nodes are round and show loss of fatty hilum [Figure 2B] or the hilum is displaced to the side, whereas reactive nodes maintain their reniform shape and have preserved fatty hilum. Slit-like appearance of hilum is often seen in metastatic disease than reactive nodes, as was seen in this case [Figure 2C].

MRI findings of PBL show well-circumscribed masses which are isointense on T1W and hyperintense on T2W/STIR images. Post contrast administration, the lesions show marked heterogeneous enhancement. Time-intensity curve or kinetics study on MRI in PBL shows a rapid early enhancement and plateau or a slow washout in delayed phase. The lesion in this case was isointense on T1W, hyperintense on STIR, and showed heterogeneous enhancement with a few nodular hyper-enhancing areas within. It showed type 2 kinetic curve [Figure 4D]. Unlike breast carcinoma which typically shows early enhancement and rapid washout (type 1 curve), lymphomas tend to show type 2 curve. Surov *et al.* in their study of 23 lesions of PBL found type 2 and type 1 kinetic curves in 90% and 5% of the lesions, respectively.^[5]

Lymphomas show increased FDG uptake on PET/CT which can be focal or diffuse depending on the involvement of the breast, as was seen in our case with SUV_{max} of 9.4 [Figure 5]. PET/CT has a role in staging and in evaluation of treatment response and detection of recurrence on follow-up.^[6]

The differential diagnosis of PBL should include phyllodes tumor, fibroadenoma, breast hamartoma, primary breast cancer, and metastatic lesions. Phyllodes tumor presents as painless rapidly growing mass which occurs most commonly between 40 and 60 years in the perimenopausal age. On mammography, it appears as large rounded oval or lobulated, well-circumscribed mass lesion with even margins. Micro- or macrocalcification is not a typical feature of phyllodes. On USG, it may mimic a large fibroadenoma in appearance. Breast hamartomas also present as painless lump with asymmetrical enlargement of breast, but they typically occur in relatively younger age group of 35–50 years, unlike lymphomas that occur in 50–60 years age group. On mammography, they are seen as inhomogeneous, round to oval mass with well-defined margins surrounded by thin halo. On USG, they are compressible and show internal echotexture mixed with both hyperechoic and hypoechoic components which may mimic the appearance of large lymphoma. On MRI, the hamartoma appears as encapsulated mass with intralobular fat and fibroglandular signal intensity without abnormal contrast enhancement;^[7] lymphoma, in contrast, appears hyperintense on STIR/T2W imaging and shows avid contrast enhancement.

Pathologically, PBLs are mostly B-cell lymphomas with up to half being DLBL mostly CD 20+, as was seen in our case. Other lymphomas that can present in breast are follicular lymphoma, MALT lymphoma, Burkitt's lymphoma, and Burkitt-like lymphoma.^[8]

The management of PBL includes radiotherapy and chemotherapy, which depends on the stage and histologic grade of disease. It is vital to make a correct diagnosis, as surgical resection is generally not required in these cases.

Conclusion

Primary lymphoma of breast is rare but an important differential in patient presenting with lump breast as it can be treated without surgical resection by chemotherapy. Therefore, radiologically one should keep in mind this differential diagnosis especially in elderly patient presenting with well-defined radiodense lump with ipsilateral enlarged nodes on mammography or USG. The trucut biopsy should be done in these cases as histopathological and immunocytochemistry conclusively diagnose this entity.

Acknowledgement

The authors would like to thank Dr. Neeraj Kumar, Asst. Prof., Department of Nuclear Medicine, Command Hospital, for permitting them to use the PET/CT image.

Declaration of patient consent

The authors certify that they have obtained all appropriate patient consent forms. In the form the patient(s) has/have given his/her/their consent for his/her/their images and

other clinical information to be reported in the journal. The patients understand that their names and initials will not be published and due efforts will be made to conceal their identity, but anonymity cannot be guaranteed.

Financial support and sponsorship

Nil.

Conflicts of interest

There are no conflicts of interest.

References

1. Giardini R, Piccolo C, Rilke F. Primary non-Hodgkin's lymphomas of the female breast. *Cancer* 1992;69:725-35.
2. Wiseman C, Liao KT. Primary lymphoma of the breast. *Cancer* 1972;29:1705-12.
3. Topalovski M, Crisan D, Mattson JC. Lymphoma of the breast. A clinicopathologic study of primary and secondary cases. *Arch Pathol Lab Med* 1999;123:1208-18.
4. Liberman L, Giess CS, Dershaw DD, Louie DC, Deutch BM. Non-Hodgkin lymphoma of the breast: Imaging characteristics and correlation with histopathologic findings. *Radiology* 1994;192:157-60.
5. Surov A, Holzhausen H-J, Wienke A, Schmidt J, Thomssen C, Arnold D, *et al.* Primary and secondary breast lymphoma: Prevalence, clinical signs and radiological features. *Br J Radiol* 2012;85:e195-205.
6. Santra A, Kumar R, Reddy R, Halanaik D, Kumar R, Bal CS, *et al.* FDG PET-CT in the management of primary breast lymphoma. *Clin Nucl Med* 2009;34:848-53.
7. Bhatia M, Ravikumar R, Maurya VK, Rai R. "Breast within breast sign": Mammary hamartoma. *Med J Armed Forces India* 2015;71:377-9.
8. Ganjoo K, Advani R, Mariappan MR, McMillan A, Horning S. Non-Hodgkin lymphoma of the breast. *Cancer* 2007;110:25-30.