

# Prenatal diagnosis of nail patella syndrome: A case report

L D Padmanabhan, D Yesodharan<sup>1</sup>, S Nampoothiri<sup>1</sup>

Division of Perinatology, Amrita Institute of Medical Sciences and Research Centre, <sup>1</sup>Department of Paediatric Genetics, Amrita Institute of Medical Sciences and Research Centre, Kochi, Kerala, India

**Correspondence:** Dr. L D Padmanabhan, Columbia Asia Hospital, Whitefield, Bangalore, Karnataka, India. E-mail: latoshmi@gmail.com

## Abstract

The Nail Patella Syndrome (NPS) is an autosomal dominant connective tissue disorder affecting the nails, skeletal system, kidneys and eyes. Here, we report a case of NPS detected at 19 weeks of gestation. The movements of the elbow and knee joints were restricted and there was rotational deformity of the knee joints. To our knowledge, this is the first report of in-utero restriction of limb movements in a fetus with NPS.

**Key words:** Limited extension of elbow and knee joints; nail patella syndrome; rotational defect of knee joint

## Introduction

Nail patella syndrome (NPS) is a pleiotropic condition affecting tissues of both ectodermal and mesodermal origin manifesting as nail, skeletal, ocular and renal anomalies. The incidence is approximately 1 in 50000 live births.<sup>[1,2]</sup> Here, we report a case of prenatal detection of NPS at 19 weeks of gestation. To our knowledge, this is the first case report of prenatal detection of NPS from India.

## Case Report

A 21-year-old primigravida underwent an anomaly scan at 19 weeks of gestation. Her medical and surgical history was unremarkable. Her husband had NPS which was proven by mutation study. He was visually challenged secondary to congenital glaucoma and had undergone renal transplantation for end-stage renal disease due to focal segmental glomerulosclerosis. He had antecubital

pterygium; difficulty in abducting the shoulders; bilateral small and dislocatable patella; swan neck deformity of fingers; triangular lunules in the thumbs; dystrophy and longitudinal ridging in both thumb nails and absent skin creases on distal interphalangeal joints of the second, third and fourth fingers, and bilateral iliac horns.

Ultrasound evaluation showed a single live fetus with parameters corresponding to 19 weeks of gestation. The orientation of the long bones of the lower limbs was abnormal. There was rotational defect at the knee joint in both the lower limbs and feet were pointing towards the gluteal region. The extension at the knee joints was restricted [Figure 1 and Videos 1,2]. Throughout the examination both the upper limbs were flexed at the elbow joint with limited extension in between [Figure 2]. A three-dimensional (3D) ultrasound scan was undertaken to better delineate the extent of the limb anomaly, which showed a clearer picture of the abnormal position of the limbs. The upper limb was kept flexed at the elbow and in the lower limbs the feet were pointing towards the gluteal

Videos available on: [www.ijri.org](http://www.ijri.org)

### Access this article online

#### Quick Response Code:



Website:  
[www.ijri.org](http://www.ijri.org)

DOI:  
10.4103/ijri.IJRI\_438\_16

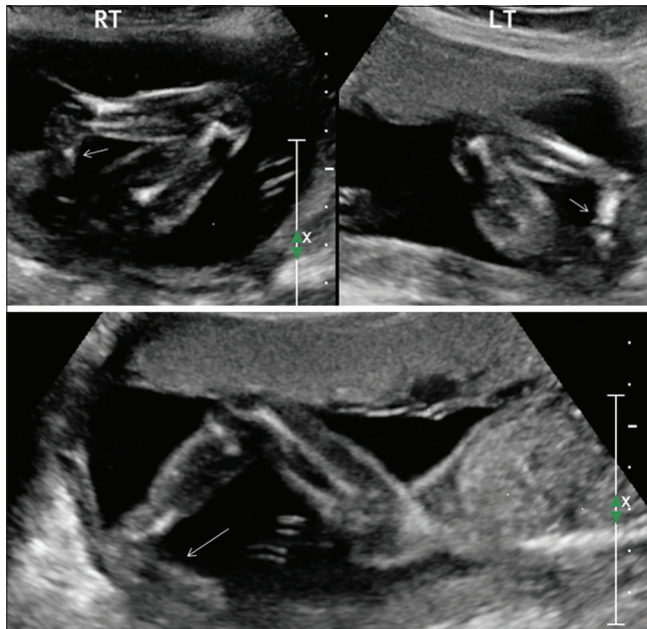
This is an open access article distributed under the terms of the Creative Commons Attribution-NonCommercial-ShareAlike 3.0 License, which allows others to remix, tweak, and build upon the work non-commercially, as long as the author is credited and the new creations are licensed under the identical terms.

**For reprints contact:** [reprints@medknow.com](mailto:reprints@medknow.com)

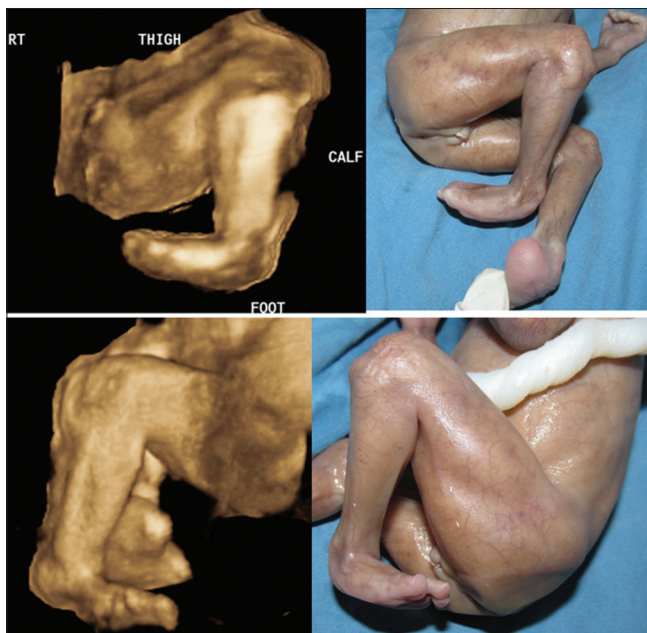
**Cite this article as:** Padmanabhan LD, Yesodharan D, Nampoothiri S. Prenatal diagnosis of nail patella syndrome: A case report. Indian J Radiol Imaging 2017;27:329-31.

region [Figures 2 and 3]. Based on these ultrasound findings the clinical diagnosis was NPS. When counseled regarding the findings, the couple opted for termination.

Post-abortion examination and infantogram confirmed the antenatal findings. In the lower limbs, there was a rotational defect at the knee joint and the feet were pointing posteriorly. The elbows could not be extended beyond 90° due to soft tissue contracture. In the infantogram, the



**Figure 1:** Two-dimensional image of the lower limbs with foot (arrow) pointing towards the gluteal region with restricted extension at the knee joint

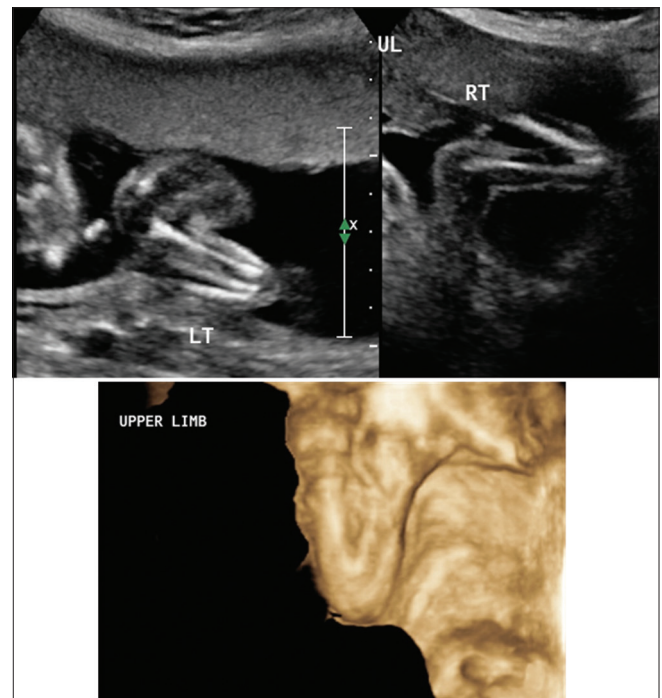


**Figure 3:** Three-dimensional image and post abortion images of the right and left lower limbs with feet pointing towards the gluteal region with restricted extension at the knee joint

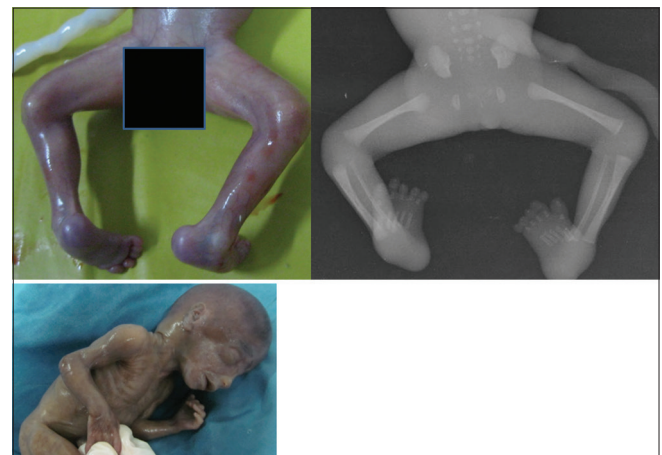
tibia was seen laterally with a medial fibula due to torsion at the knee joint [Figure 4].

## Discussion

NPS also known as onycho-osteo-dysplasia, Fong disease, Turner-Kieser syndrome. NPS is characterized by a clinical tetrad involving the nails, knees, elbows and presence of iliac horns. Nail changes seen are hypoplasia, splitting, discoloration, longitudinal ridging, poorly-formed lunulae and triangular lunulae. Nails on the radial side of the hand are said to be more severely affected and the 4<sup>th</sup> and 5<sup>th</sup> finger nails may be relatively normal. Aplasia or



**Figure 2:** Two-dimensional and three-dimensional image of the upper limb showing persistent flexion at the elbow joint



**Figure 4:** Post abortion picture of upper limb and lower limb. x ray of the lower limbs showing fibula in the medial position compared to laterally placed tibia. Note difficulty to extend the elbow joint

hypoplasia of the patella, inability to straighten the knee joint, or rotational deformities may be seen. At the elbow joint, there may be webbing of the elbow, loss of extension, or limitation of pronation and supination. Other findings of NPS are proteinuria with or without hematuria, casts, renal insufficiency and glaucoma.<sup>[1-3]</sup>

Prenatal detection of NPS has been reported earlier in two cases. Feingold *et al.* detected the first case by the presence of bilateral iliac horns at 36 weeks of gestation.<sup>[4]</sup> The second case was diagnosed at 18–19 weeks and showed lower extremity clubbing with malrotation on the left side; the father of the fetus was diagnosed to have NPS.<sup>[5]</sup> Abnormalities of limb movements have not been reported in earlier cases, whereas our case had restricted movements of both upper and lower limbs with rotational defect of the lower limbs.

McIntosh *et al.* used 5 DNA markers flanking the *LMX1B* locus to demonstrate that a fetus was affected with NPS.<sup>[6]</sup> Drut *et al.* observed renal changes in a spontaneously aborted 18-week fetus with NPS and proposed intrauterine kidney biopsy for the prenatal diagnosis.<sup>[7]</sup> However, considering the invasive nature of this procedure it is unlikely to be the procedure of choice for the prenatal diagnosis of NPS. Sweeney *et al.* in a clinical study of 123 patients with NPS observed that in 1 patient severe bilateral talipes was noted in the 20-week scan.<sup>[3]</sup> Talipes in a fetus with an affected parent with NPS should probably raise a suspicion and warrant a careful scrutiny of the limbs.

Prenatal detection of NPS is important because of the associated abnormalities. NPS being an autosomal dominant disorder, the risk to inherit to the offspring is 50% when either of the parents is affected with NPS. Being a multisystem disorder with severe morbidity, it is mandatory to discuss the possible phenotype in the offspring if the baby is affected so that the family can take an informed decision. Skeletal abnormalities may require extensive reconstructive surgery and there is always a risk for nephropathy. Looij *et al.* have reported a risk of 1 in 4 of having a child with nephropathy and the risk of having a child in whom renal failure will develop as 1 in 10 when there is a family history of nephropathy with NPS.<sup>[8]</sup> In our case, the father had undergone renal transplantation for end-stage renal disease.

Prenatal detection of NPS will help the parents to take an informed decision whether to continue or terminate the pregnancy when faced with the possibility of a severely affected fetus. If they opt to continue the pregnancy, it will help them to accept and plan the postnatal care. In such circumstances, three-dimensional ultrasound can help in counseling the parents regarding the extent of the anomaly. Prenatal diagnosis by molecular analysis can be offered when the mutation in the family is known.

Our case highlights the importance of critical evaluation by ultrasound of “at-risk fetuses.” This approach of noninvasive detection is very crucial where the molecular studies are not feasible as well as in resource-limited situations.

To conclude, NPS can be diagnosed at the time of anomaly scan, and our case highlights the importance of a careful scrutiny of the limbs – the orientation of long bones and the limb movements in fetuses at risk for NPS.

#### Financial support and sponsorship

Nil.

#### Conflicts of interest

There are no conflicts of interest.

#### References

1. Online Mendelian Inheritance in Man, OMIM®. Johns Hopkins University, Baltimore, MD. MIM Number: 161200:05/23/2016. World Wide Web URL <http://omim.org>. [Last accessed on 2016 Sep 03].
2. Lyons Jones K, Crandall Jones M, Del Campo M. Smith's Recognizable Patterns of Human Malformation (7<sup>th</sup> edn). Philadelphia, PA: W. B. Saunders Company; 2013; 572-3.
3. Sweeney E, Fryer A, Mountford R, Green A, McIntosh I. Nail patella syndrome: A review of the phenotype aided by developmental biology. *J Med Genet* 2003;40:153-62.
4. Feingold M, Itzhak Y, Goodman RM. Ultrasound prenatal diagnosis of the Nail-Patella syndrome. *Prenat Diagn* 1998;18:854-6.
5. Pinette MG, Ukleja M, Blackstone J. Early prenatal diagnosis of nail patella syndrome by ultrasonography. *J Ultrasound Med* 1999;18:387-9.
6. McIntosh I, Clough M V, Gak E, Frydman M. Prenatal diagnosis of nail-patella syndrome. *Prenat Diagn* 1999;19:287-8.
7. Drut RM, Chandra S, Latorraca R, Gilbert- Barness E. Nail-patella syndrome in a spontaneously aborted 18-week fetus: Ultrastructural and immunofluorescent study of the kidneys. *Am J Med Gen* 1992;43:693-6.
8. Looij BJ Jr, te Slaa RL, Hogewind BL, van de Kamp JJP. Genetic counselling in hereditary osteo-onychodysplasia (HOOD, nail-patella syndrome) with nephropathy. *J Med Genet* 1988;25:682-6.