

MR-guided focused ultrasound surgery: A novel non-invasive technique in the treatment of adenomyosis -18 month's follow-up of 12 cases

Bhawna Dev^{1,2}, Sameera Gaddam², Mitesh Kumar¹, Suresh Varadarajan³

¹Department of Radiology, Sri Ramachandra Institute of Higher Education and Research, Porur, ²Department of Radiology, Concept Medicare Pvt Ltd Guindy, Chennai, ³Department of Community Medicine, Sri Ramachandra Institute of Higher Education & Research, Porur, Chennai, Tamil Nadu, India

Correspondence: Dr. Bhawna Dev, Department of Radiology, Sri Ramachandra University, Chennai - 600 116, Tamil Nadu, India.
E-mail: bhawnadev@gmail.com

Abstract

Background: Adenomyosis is a gynecological condition of the uterus, characterized by the presence of ectopic endometrial tissue in the myometrium. Hysterectomy, uterine artery embolization, and endometrial ablation therapy are the various surgical treatment options available for adenomyosis. A novel and globally upcoming technique is MR-guided focused ultrasound surgery "MRgFUS," which is a promising non-invasive surgical treatment option. This study was carried out to determine the effectiveness of MRgFUS in the symptomatic management of adenomyosis. **Subjects and Methods:** This study was carried out as a long-term follow-up study among 12 cases of adenomyosis, which were treated by MR-guided focused ultrasound. In all these participant's, three parameters – symptom severity score (SSS), menstrual pain score accessed using visual analogue score (VAS), and number of approximate pads used during menstruation were recorded prior to the treatment and on follow-up at 3, 9, and 18 months, respectively. The Friedman's test was used to test the difference in the values of scores before and after treatment. **Results:** There was a significant improvement in the SSS, VAS, and the numbers of sanitary napkins used after surgery and sustained during the long-term follow-up. These values were statistically significant ($P < 0.05$). **Conclusion:** MRgFUS can be used in successful treatment of adenomyosis/focal adenomyoma by careful selection of the participant, good planning, and proper monitoring of the technique during ablation.

Key words: Adenomyosis; HIFU; high-intensity focused ultrasound; long-term follow-up; MR- guided focused ultrasound; magnetic resonance-guided focused ultrasound; sanitary pads

Introduction

Adenomyosis is a condition characterized by the presence of ectopic endometrial tissue in the myometrium. It can be either diffuse or focal in its involvement. It has been defined as the benign invasion of the endometrium into

the myometrium producing a diffusely enlarged uterus, which microscopically exhibits ectopic, non neoplastic

This is an open access journal, and articles are distributed under the terms of the Creative Commons Attribution-NonCommercial-ShareAlike 4.0 License, which allows others to remix, tweak, and build upon the work non-commercially, as long as appropriate credit is given and the new creations are licensed under the identical terms.

For reprints contact: reprints@medknow.com

Cite this article as: Dev B, Gaddam S, Kumar M, Varadarajan S. MR-guided focused ultrasound surgery: A novel non-invasive technique in the treatment of adenomyosis –18 month's follow-up of 12 cases. Indian J Radiol Imaging 2019;29:284-8.

Received: 20-Feb-2019

Revision: 05-May-2019

Accepted: 05-Jul-2019

Published: 30-Oct-2019

Access this article online

Quick Response Code:



Website:
www.ijri.org

DOI:
10.4103/ijri.IJRI_53_19

endometrial glands and the stroma surrounded by the hypertrophic and hyperplastic myometrium.^[1] The exact etiology of this entity remains unknown, but it has been associated with any condition that damages the junction between endometrium and myometrium leading to the presence of ectopic endometrium tissue in the myometrium.

There has been a wide variation in the prevalence of adenomyosis all over the world. The average prevalence of adenomyosis varies from 20% to 30%, while in several studies, the prevalence has been as low as 5% and in some, as high as 70%.^[2] The symptoms of adenomyosis are pelvic or abdominal pain, pain in thighs and legs, heavy and/or prolonged bleeding, severe dysmenorrhea, infertility, and repeated abortion among others. These symptoms overlap with other common gynecological disorders such as uterine myomas and pelvic endometriosis.^[3]

The first line of treatment for adenomyosis is medical management with anti-inflammatory and hormonal medicines. Hysterectomy, uterine artery embolization, and endometrial ablation therapy are the various surgical treatment options available for adenomyosis. The other interventions include uterine artery ligation, myometrial electrocoagulation, and hysteroscopic procedures. These procedures are invasive options and have high rates of complications such as post operative bleeding, hormonal imbalances, and increased risk of infertility. Therefore, there has been a growing need to develop a gold standard therapeutic option, which is both effective and non-invasive.

A novel and globally accepted technique for management of adenomyosis has been developed in recent times. The technique is magnetic resonance-guided focused ultrasound (MRgFUS). This technique has shown promising results in symptomatic management of adenomyosis and has been found to have minimal complications and adverse effects. MRgFUS is a non-ionizing, completely non-invasive procedure, which can be performed on a day care basis. This technique has been approved by the United States Food and Drug Administration for management of fibroids.^[4] This intervention provides focused delivery of a concentrated quantity of ultrasound energy to deep tissue areas without thermal effects to the surrounding tissues.^[5] The advantages of this procedure are its non-invasive nature, accuracy, safety, effectiveness, and absence of scars. The other potential advantage is that this modality of treatment does not affect the fertility. Because this procedure is carried out as a daycare procedure, it requires only mild sedation.

Considering the advantages, MRgFUS can be used as a good alternative to hysterectomy in adenomyosis. There are very few studies done to evaluate the effectiveness of MRgFUS on long-term management of adenomyosis. An assessment of long-term benefits of MRgFUS helps in establishing the

gold standards in the management of adenomyosis, in symptomatic participants. This study was carried out to determine the effectiveness of MRgFUS in symptomatic management of adenomyosis.

Subjects and Methods

Study setting and study participants

This study was carried out as a prospective non-randomized trial between January 2012 and October 2014 in a private clinic. All the participants who were diagnosed with adenomyosis formed the study population. The participants were selected as per inclusion and exclusion criteria as follows:

Inclusion criteria

1. Age of the participant between 25 and 45 years
2. Participants with symptomatic adenomyosis confirmed on MRI
3. Junctional zone >25 mm in thickness^[6]
4. Symptom severity score (SSS) of more than 25 were included in the study.

Exclusion criteria

1. Participants who required the second treatment session
2. Presence of bowel loops in-front of the uterus
3. Thick abdominal wall scar.

A total of 12 participants with adenomyosis participated in the study. The participants were selected by purposive sampling.

Informed consent

Each participant was explained in detail about the study, and informed consent was obtained prior to the data collection.

Data collection tools

The diagnosis and technical ability to follow the procedure protocol were confirmed by MRI. Ablation was performed using high focused ultrasound (Exblate[®] 2100 Insightec, Israel) under the guidance of 1.5T MRI (General Electric, USA).

Preliminary assessment

The SSS, the menstrual pain score (analyzed using VAS), and the number of sanitary pads used were evaluated pre-MRgFUS as baseline values.^[7,8] MRI pelvis with intravenous gadolinium was performed in all participants as a preliminary, essential decision-making imaging investigation. MRI was performed using 1.5T MR in the prone position and by placing a gel pad under the abdomen. This was done to simulate the gel pad used during the MRgFUS.

MRgFUS procedure

All the procedures were performed during the first half of the menstrual cycle of the study.^[9] After preparation of

the participants for the procedure, the participants were made to lie in the prone position on the water trough on a gel pad immersed in degassed water. The pelvic coil was placed on participant's back and secured tightly. The MRI was performed by using axial, sagittal, and coronal T2 weighted images to determine the exact location of the adenomyosis/focal adenomyoma in the uterus. The acquired images were transferred from MRI to FUS workstation.

Diligent mapping of the lesion was done on FUS workstation. Skin line–red line [Figure 1A] was drawn as an initial step of planning, followed by drawing of no pass zones on bowel loops - pink line [Figure 1A], far-field bones such as sacrum -yellow line [Figure 1A] and pubic bone – blue line [Figure 1A], also on scars and clips if present. The region of interest–orange oval [Figure 1B] is then marked. Virtual fiducials were placed on the uterine boundary – red crosses [Figure 1C], fiducials guide to detect any minimal movement during the procedure. The appropriate protocol to treat the particular lesion was selected followed by movement detection scan.

After meticulous mapping of the targeted area, the system by default determined the number and size of sonication or focal spots– green rectangles [Figure 1C] required for ablation of the region of interest. Midazolam – 2 mg was given intravenously to the participants for conscious sedation just before the first sonication. Simultaneously, ringer lactate solution was also administered intravenously.

Pre-treatment verification sonication was performed in coronal and sagittal sections just before real sonications. Following this, the treatment was started, addressing each sonication of varying size at a particular temperature, energy, and time. The real-time temperature was monitored with the help of MR thermography and thermal maps, which were obtained during each sonication.^[10-12] The diseased area was heated under continuous MRI monitoring until temperature > 60°C reached. This thermal map helped the interventional radiologist to modify the treatment plan as and when required. During the treatment, the participant's heart rate, pulse, oxygen saturation, and blood

pressure were constantly monitored. The treatment took 2 to 4 h depending upon the size of the adenomyosis to be treated. When required extra sonications were performed on the manually selected areas.

After the area mapped was satisfactorily treated, intravenous gadolinium was administered to the participant, Spoiled Gradient images were obtained, and non-enhancing area – non-perfused volume (NPV) was determined to measure the area treated. Before shifting the participant to recovery room, physical examination of her anterior abdominal wall to look for skin burns was done. Participant's vitals were checked and the participant was discharged. All participants were advised to report back in case of any discomfort.

Follow-up

The participants were followed-up by telephonic conversation the next day, after a week, and then after their first menstrual period post procedure regarding any post-procedural pain. SSS, pain during menstruation using VAS, and number of sanitary pads used during periods (PADS) were re-assessed at the end of three, nine, and eighteen months.

Data analysis

Data were entered and analyzed using SPSS ver 21 software. The Friedman's test was used to test the difference in the values of SSS, VAS, and no of sanitary napkins (PADS) used, from baseline value to third, ninth, and eighteenth month among the study participants. A *P* value <0.05 was considered statistically significant.

Results

Results were analyzed considering three basic parameters - SSS, pain during menstruation using VAS, and number of sanitary napkins (PADS) used during periods.

These values were statistically significant as shown below in the Tables 1-3. The mean, median values of SSS, VAS, and number of PADS used have gradually decreased from baseline to 18 months. The differences in the mean scores of SSS before and after through the follow-up period among the study participants shows a significant reduction in the scores. The observed difference was statistically significant (*P* < 0.001) [Table 1].

The pain during menstruation was evaluated using VAS. There was a significant reduction in the VAS scores post intervention, and this reduction was further observed at the end of 12 months (2.5 ± 1.0). The observed difference was statistically significant (*P* < 0.001) [Table 2].

The mean usage of sanitary napkins during the menstruation was assessed and compared with the values taken at baseline and after intervention. There has been a

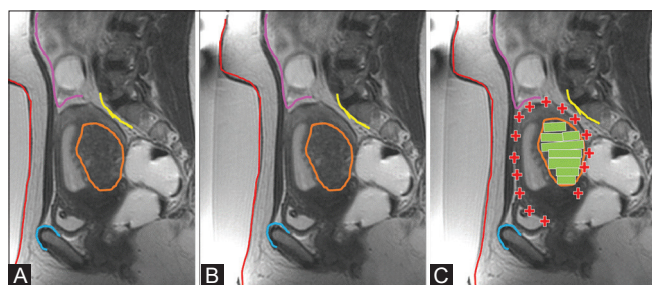


Figure 1 (A-C): (A) No pass zone on bowel loops (pink line); sacrum (yellow line) pubic bone (blue line). (B) Marking of the region of interest (orange). (C) Virtual fiducials to mark the uterine boundary; focal spots (green rectangles)

significant reduction in the mean number of sanitary napkins used and the observed difference was statistically significant ($P < 0.001$) [Table 3].

MRI of one participant showed anterior wall adenomyosis in pre-MRgFUS plain and contrast sagittal images [Figure 2A and B] and immediate post ablation sagittal image depicting non-perfused area [Figure 2C]. Another participant's MRI showed posterior wall disease in T2W sagittal prior to the treatment [Figure 3A], during sonications [Figure 3B], and non-perfused area immediately after the MRgFUS treatment in sagittal T1W post contrast image [Figure 3C].

Discussion

MRgFUS has been proved to be an established procedure in the treatment of fibroids and recently adenomyosis.^[13-15] Lately, the number of studies have been done to determine

Table 1: Difference in the mean scores of SSS among the study participants

SSS	Mean	SD	P
Base line	51.6	10.0	<0.001
3 months	32.8	9.8	
9 months	25.6	8.0	
18 months	22.5	3.0	

Table 2: Difference in the mean VAS scores among the study participants

VAS	Mean	SD	P
Base line	7.5	1.1	<0.001
3 months	4.0	1.4	
9 months	3.2	1.3	
12 months	2.5	1.0	

Table 3: Mean usage of sanitary napkins among the study participants

PADS	Mean	SD	P
Base line	6.4	1.7	<0.001
3 months	4.5	0.9	
6 months	3.7	0.8	
12 months	3.4	0.5	

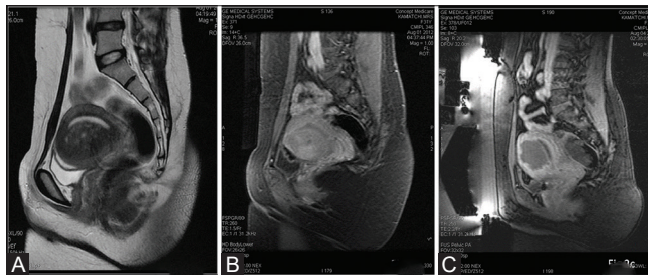


Figure 2 (A-C): (A and B) Pre-MRgFUS plain and contrast sagittal images. (C) Immediate post-ablation image showing non-perfused area

the extent of reduction in symptoms of the participants treated using MRgFUS. The procedure consists of high intensity ultrasonic waves that are focused on the target area. The adenomyosis/adenomyoma is localized by axial, sagittal, and coronal T2 weighted MRI images. Once localized, this high intensity focused ultrasound beam is targeted to the lesion to be ablated. This beam when passes through the affected tissue produces heat and the resultant increase in the temperature leads to protein denaturation and coagulation.^[16,17] The area surrounding the region of interest also gets mildly heated without producing any cell death. The temperature is monitored on FUS monitor and treatment plan modified as per the thermal map. Once the number of sonication to be given is completed, contrast-enhanced SPGR images are obtained to look for non-enhancing areas, which indicate significant ablation. This is then compared with the pre-ablation post-contrast images.

Only a few studies determining the long-term effect of MRgFUS treated adenomyosis are present. Ferrari *et al.* and Fan *et al.* have reported reduction in uterine volume on follow-up MRI over a period of 12 months.^[18,19] In our study, we had evaluated the usage patterns of sanitary napkins before and after the intervention and found a significant reduction in the number of pads used during menstruation, after the intervention. Few studies have demonstrated this finding, which is a proxy measure of the volume of menstrual flow, which otherwise could be a subjective measure.

All our participants were followed at the end of 3, 9, and 18 months. We found a significant decrease in the bleeding, symptom severity score SSS, VAS, and decrease in the number of sanitary pads used by our participants during their menstrual cycle. This led to a significant change in their lifestyle, and two of 12 participants were able to conceive after the procedure. These two participants successfully completed their pregnancies and delivered healthy babies.

MRgFUS can be described as a non-invasive, incision-free surgery. MRI by its virtue of high soft tissue resolution is able to characterize, localize, and target the adenomyotic foci and useful in the monitoring and follow-up of the ablation. It does not affect the nearby tissue, thus preserving the

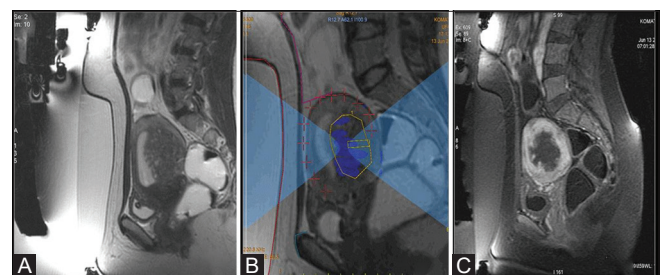


Figure 3 (A-C): (A) T2W sagittal MRI prior to treatment; (B) Image during sonication; (C) Non-perfused area immediately after treatment

shape and the strength of the uterus for future pregnancy. The complications associated with this procedure are rare and includes skin burn, back ache, abdominal pain, bladder perforation, bowel perforation, and urinary tract infection. In the study performed by Zhang *et al.*, there was more frequent abdominal pain in cases with diffuse adenomyosis as compared to focal adenomyosis (64% and 71%).^[20] Few rare complications such as severe leg pain and foot drop can also occur during and after the treatment as documented by Lee *et al.*^[21] In our study, we did not encounter any major or minor complications. During the sonications, three participants had complained of cramps, which was tackled by just reassuring the participants on table.

Conclusion

MRgFUS can be used in the successful treatment of adenomyosis/focal adenomyoma by careful selection of the participant, good planning, and proper monitoring of the technique during ablation. This method although expensive has limited availability as of now, the advantages of being a scarless, non-invasive out participant procedure that does not require hospitalization and has a fast recovery period. However, studies with larger sample size and long-term follow-up are required to establish the role of MRgFUS affirmly in treating symptomatic adenomyosis.

Limitation

This study has certain limitations. Owing to logistic and other constraints, we could only document the follow-up data through telephonic conversations. Moreover, we have not confirmed the histopathological evidence of adenomyosis in any of our participants. An explorative analysis comparing the MRI of pre- and post-treatment could significantly enhance the statistical inference. However, they could not be done owing to certain constraints.

Financial support and sponsorship

Nil.

Conflicts of interest

There are no conflicts of interest.

References

1. Benagiano G, Brosens I. History of adenomyosis. *Best Pract Res Clin Obstet Gynaecol* 2006;20:449-63.
2. Taran FA, Stewart EA, Brucker S. Adenomyosis: Epidemiology, risk factors, clinical phenotype and surgical and interventional alternatives to hysterectomy. *Geburtshilfe Frauenheilkd* 2013;73:924-31.
3. Rabinovici J, Stewart EA. New interventional technique for adenomyosis. *Best Pract Res Clin Obstet Gynaecol* 2006;20:617-37.
4. Zhou YF. High intensity focused ultrasound in clinical tumor ablation. *World J Clin Oncol* 2011;2:8-27.
5. Al Hilli MM, Stewart EA. Magnetic resonance-guided focused ultrasound surgery. *Semin Reprod Med* 2010;28:242-9.
6. Novellas S, Chassang M, Delotte J, Toullalan O, Chevallier A, Bouaziz J, *et al.* MRI characteristics of the uterine junctional zone: From normal to the diagnosis of adenomyosis. *AJR Am J Roentgenol* 2011;196:1206-13.
7. Harding G, Coyne KS, Thompson CL, Spies JB. The responsiveness of the uterine fibroid symptom and health-related quality of life questionnaire (UFS-QOL). *Health Qual Life Out* 2008;6:99.
8. Spies JB, Coyne K, GuaouGuaou N, Boyle D, Skynarz MK, Gonzalves SM. The UFS-QOL, a new disease specific symptom and health related quality of life questionnaire for leiomyomata. *Obstet Gynecol* 2002;99:290-300.
9. Fukunishi H, Funaki K, Sawada K, Yamaguchi K, Maeda T, Kaji Y. Early results of magnetic resonance-guided focused ultrasound surgery of adenomyosis: Analysis of 20 cases. *J Minim Invasive Gynecol* 2008;15:571-9.
10. Ishihara Y, Calderon A, Watanabe H, Okamoto K, Suzuki Y, Kuroda K. A precise mapping using proton chemical shift. *Magn Reson Med* 1995;34:814-23.
11. Cline HE, Hynynen K, Watkins RD. Focused US system for MR imaging-guided tumor ablation. *Radiology* 1995;194:731-7.
12. Hindman JC. Proton resonance shift of water in the gas and liquid states. *J Chem Phys* 1966;44:4582-92.
13. Morita Y, Ito N, Hikida H, Takeuchi S, Nakamura K, Ohashi H. Non-invasive magnetic resonance imaging-guided focused ultrasound treatment for uterine fibroids-early experience. *Eur J Obstet Gynecol Reprod Biol* 2008;139:199-203.
14. Hindley J, GedroycW, Regan L, Stewart E, Tempany C, Hynynen K, *et al.* MRI guidance of focused ultrasound therapy of uterine fibroids: Early results. *AJR Am J Roentgenol* 2004;183:1713-9.
15. Kim KA, Yoon SW, Lee C, SeongSJ, Yoon BS, Park H. Short-term results of magnetic resonance imaging-guided focused ultrasound surgery for participants with adenomyosis: Symptomatic relief and paid reduction. *Fertil Steril* 2011;95:1152-5.
16. Jolesz FA, Hynynen K. Magnetic resonance image-guided focused ultrasound surgery. *Cancer J* 2002;8(Suppl 1):S100-12.
17. Chung AH, Jolesz FA, Hynynen K. Thermal dosimetry of a focused ultrasound beam *in vivo* by magnetic resonance imaging. *Med Phys* 1999;26:2017-26.
18. Ferrari F, Arrigoni F, Miccoli A, Mascaretti S, Fascetti E, Mascaretti G, *et al.* Effectiveness of magnetic resonance-guided focused ultrasound surgery (MRgFUS) in the uterine adenomyosis treatment: Technical approach and MRI evaluation. *Radiol Med* 2016;121:153-161.
19. Fan TY, Zhang L, Chen W, Liu Y, He M, Huang X, *et al.* Feasibility of MRI-guided high intensity focused ultrasound treatment for adenomyosis. *Eur J Radiol* 2012;81:3624-30.
20. Zhang X, Li K, Xie B, He M, He J, Zhang L. Effective ablation therapy of adenomyosis with ultrasound-guided high-intensity focused ultrasound. *Int J Gynaecol Obstet* 2014;124:207-11.
21. Lee JS, Hong GY, Park BJ, Kim TE. Ultrasound-guided high-intensity focused ultrasound treatment for uterine fibroid and adenomyosis: A single center experience from the Republic of Korea. *Ultrason Sonochem* 2015;27:682-7.