

Radiological requirements for surgical planning in cochlear implant candidates

Mohamad Hasan Alam-Eldeen, Usama Mohamed Rashad¹, Al Hussein Awad Ali¹

Departments of Diagnostic Radiology and ¹Otolaryngology, Sohag Faculty of Medicine, Sohag University, Sohag, Egypt

Correspondence: Dr. Mohamad Hasan Alam-Eldeen, Department of Radiology, Sohag Faculty of Medicine, Sohag University, Sohag, Egypt.
E-mail: m.elkousy@yahoo.com

Abstract

Objective: This study is concerned with clarification of radiological findings that should be addressed and reported in patients listed for cochlear implant (CI) operation. These findings may force a surgeon to consider modifications of the surgical approach by a CI surgeon. **Materials and Methods:** The study was performed from January 2015 to January 2016. It included 50 patients with severe-to-profound sensorineural hearing loss who fulfilled the criteria for CI. Patients underwent CI surgery in the Department of Otolaryngology. All patients underwent preoperative computed tomography (CT) and magnetic resonance imaging (MRI) assessment in the Department of Diagnostic Radiology. Combined examination of the CT and MRI by the radiologist and the surgeon was advocated. **Results:** Many anatomical variants were observed regarding the pattern of mastoid pneumatization, position of middle cranial fossa dura, sigmoid sinus position jugular bulb position, and the size and position of the mastoid segment of facial nerve canal. Labyrinthitis ossificans was seen in 3 patients (6%), otospongiosis in 1 patient (2%), and dilated vestibular aqueduct and endolymphatic sac in 9 patients (18%). **Conclusion:** Cochlear implantation is a major treatment modality in patients with severe-to-profound sensorineural hearing loss. Radiological evaluation is integral in surgery planning.

Key words: Cochlear implantation; computed tomography; magnetic resonance imaging; surgical considerations

Introduction

Cochlear implants (CIs) are a well-accepted treatment for severe-to-profound sensorineural hearing loss patients who are refractory to conventional hearing augmentation.^[1,2] Imaging plays an important role in the workup of CI candidates not only to identify inner ear congenital and acquired abnormalities or cochlear nerve anomalies but also to detect temporal bone abnormalities that may be encountered during surgery that may alter surgical approach.^[2,3] Some variations are potential surgical hazards that may lead to problems during the surgery and may alert the surgeon regarding potential surgical dangers and complications.^[4] The radiologist and

surgeon must be familiar with these imaging findings.^[3,4] Both computed tomography (CT) and magnetic resonance imaging (MRI) should be used as they delineate, in different manners, cochlear and middle ear anatomy as well as other anatomical variants.^[4,5]

Mastoid pneumatization is important for planning the surgery. It is classified into pneumatic, diploic, sclerotic, and mixed. Effusion of the middle ear cleft should also be reported.^[6,7]

Korner's septum divides the mastoid process into a superficial squamous portion and a deep petrous portion. It may mislead the surgeon to the mastoid antrum during

Access this article online

Quick Response Code:



Website:
www.ijri.org

DOI:
10.4103/ijri.IJRI_55_17

This is an open access article distributed under the terms of the Creative Commons Attribution-NonCommercial-ShareAlike 3.0 License, which allows others to remix, tweak, and build upon the work non-commercially, as long as the author is credited and the new creations are licensed under the identical terms.

For reprints contact: reprints@medknow.com

Cite this article as: Alam-Eldeen MH, Rashad NM, Ali AH. Radiological requirements for surgical planning in cochlear implant candidates. Indian J Radiol Imaging 2017;27:274-81.

surgery.^[4] Mastoid emissary veins participate in extracranial venous drainage of the posterior fossa dural sinuses. Most of them disappear, however, some persist and enlarge.^[8,9]

Low lying dura represents difficulty to access the aditus, lateral semicircular canal and to posterior tympanotomy. It is often associated with sclerotic mastoid.^[8] Posterior tympanotomy is a well-known otologic procedure that allows surgeons to access the middle ear cavity.^[10] The surgeon opens a window in the posterior wall of the middle ear in the angle between the chorda tympani and the mastoid part of the facial nerve.^[11] Laterally or anteriorly positioned mastoid part of the facial nerve may hinder the access to the facial recess or may even force the surgeon to change his approach.^[11-13]

The sigmoid sinus passes along the posteromedial border of the mastoid air cells. An anteriorly located sinus produces a deep bulge in the mastoid and may reach the posterior wall of the external auditory canal being separated from it only by a thin bony plate.^[8,14]

Jugular bulb variations are common, the roof of a normal jugular bulb lies either at or slightly below the level of the EAC floor and is separated from the middle ear cavity by the thin bony sigmoid plate.^[15,16] The average width of jugular bulb is 1 cm.^[16] A jugular bulb larger than 1 cm is called a giant or mega jugular bulb.^[15] A jugular bulb that extends over the basal turn of the cochlea or abuts the round window is called a high riding jugular bulb.^[17,18] Dehiscence of sigmoid plate with upward protrusion of the bulb into posterior hypotympanum is called a dehiscent jugular bulb, which may obliterate a round window niche.^[17]

Aberrant internal carotid artery is an enlarged inferior tympanic artery that occurs as a result of agenesis or underdevelopment of the cervical segment of the ICA. It runs along the medial aspect of the middle ear coursing anteriorly across cochlear promontory to join the horizontal carotid canal through a dehiscence in the carotid plate.^[9,19,20]

Cochlear duct patency and axis, patency of the round window niche and the patent even caliber of the cochlea must be adequately evaluated by both CT and MRI. Otospongiotic foci compromise the insertion of CI electrode if they occlude the round window niche or cochlear duct.^[5] Labyrinthitis ossificans may partially or completely obliterate cochlear lumen. Fibrosis may precede ossification and areas of fibrosis and ossification may coexist. Cochlear ossification with luminal obstruction is not a contraindication for implantation, however, it is important to be identified preoperatively.^[2]

Vestibular aqueduct (VA) is considered dilated if its width is greater than the width of the posterior SCC or if its midpoint width is greater than 1.5 mm.^[21,22] CT shows dilatation of

the VA only whereas MRI shows the dilatation of the VA and of the endolymphatic sac.^[21]

The aim of this topic is the clarification of the radiological findings of surgical interest that should be addressed and reported, which may require modification of the surgical approach by the CI surgeon.

Materials and Methods

Consent

- Approval of our institute Research Ethics Committee was obtained
- Consent from the patients or his/her guardian was obtained.

This hospital-based study was performed in from January 2015 to January 2016. It included 50 patients (25 males and 25 females; age ranging between 2 and 26 years) who were clinically diagnosed as having severe-to-profound SNHL and fulfilled the criteria for CI. Patients underwent CI surgery in the Department of Otolaryngology. All patients underwent preoperative CT and MRI assessment in the Department of Diagnostic Radiology. Standard CT and MRI protocols in addition to special multiplanar reconstructive CT protocols concerning the complex anatomy of the ear were performed for all patients. Light sedation was given for children less than 6 years.

Inclusion criteria

- Age, any age was included
- Sex, both genders were included
- Patient fulfilled criteria for CI including audiological criteria (as bilateral profound hearing loss not benefiting from hearing aid, absent ABR waves) and phoniatric criteria as IQ (using Stanford Binet intelligence scale) more than 80 with no medical, surgical, or radiological contraindication for surgery
- Family motivation and commitment for audiologic and phoniatric rehabilitation and follow-up
- Confirmation of the presence of cochlear nerve using preimplant MRI.

Exclusion criteria

- Patient who did not fulfill the criteria for indicating CI surgery
- Patients with no records of preoperative investigations
- Patients with major dysplasia or aplasia of the cochlea as common cavity.

Computed tomography technique

The study was performed using GE Lightspeed ultra 8-slice CT scanner and Toshiba Alexion 16-slice CT scanner. Unenhanced 0.6-mm slice thickness scans were performed in the axial plane with the patient in the neutral supine position. The axial source images were used by a dedicated

workstation to obtain coronal reformatted images and coronal oblique multiplanar reformatted images on cochlea and semicircular canals on both sides.

Magnetic resonance imaging technique

MRI was performed using 1.5-T MRI unit (Philips, Acheiva, Netherlands) using a dedicated head coil with the patient in the neutral supine position. The protocol included the following sequences: axial and coronal three-dimensional (3D) balanced turbo gradient echo (B-TFE sense) sequences on cerebellopontine angle (CPA) (TR = 6 ms, TE = 3 ms, FOV = 180 mm, slice thickness = 1 mm and interslice gap = 0.5 mm, flip angle = 60°, scan duration = 1.43 min for axial and 1.35 min for coronal), sagittal oblique T2-weighted 3D Drive clear sequence perpendicular on internal auditory canal (IAC) on both sides (TR = 1.5 s, TE = 250 ms, FOV = 130 mm, slice thickness = 1.4 mm, interslice gap = 0.7 mm, flip angle = 90°, scan duration = 2.26 min) and fluid-attenuated inversion recovery (FLAIR) images of the brain (TR = 9 s, TE = 140 ms, FOV = 230 mm, slice thickness = 4 mm, interslice gap = 1 mm, flip angle = 90°, scan duration = 3 min).

Image analysis

The CT and MRI images of each patient were simultaneously assessed by the radiologist in the attendance of the surgeon during CI committee meeting to make him aware about the expected variations. All surgeries were either done by the same surgeon or attended by him. Correlation between the imaging findings and intraoperative findings was recorded.

Statistical analysis

The results obtained were statistically analyzed with the help of statistical package for social sciences (2007 SPSS 16.0 for windows) for statistical analysis IBM Corporation <https://www.ibm.com/analytics/us/en/technology/spss/>. The parameters for which statistical analysis was done included mastoid pneumatization, level of middle cranial fossa dura, Korner's septum, mastoid emissary vein, sigmoid sinus position, jugular bulb, position of the mastoid segment of facial nerve canal, alignment of cochlea basal turn with ICA, round window accessibility, round window niche and cochlear duct patency, and the state of vestibular aqueduct and endolymphatic sac with relation to CSF gusher.

Results

This study included 50 patients (25 males and 25 females) with age ranging between 2 and 26 years and a standard deviation of 3.5 years; the mean age was 4.4 years and the median age was 4 years.

Radiological evaluation of the mastoid process showed that it was pneumatic in 39 patients (78%), diploic in 6 (12%), sclerotic in 3 (6%) and mixed in 2 (4%), whereas surgical evaluation revealed that it was pneumatic in

36 (72%), diploic in 9 (18%), sclerotic in 3 (6%) and mixed in 2 (4%). CT was successful in detecting the true type of mastoid pneumatization in 47 patients (94%) and failed in 3 (6%) [Figure 1].

Middle ear cleft and mastoid effusion was found In 7 patients bilateral in 5 and unilateral in 2. Chronic sclerosing mastoiditis was found in 2 patients. Radiological assessment revealed normal position of dura in 38 patients (76%) and low lying dura in 12 (24%), whereas surgical evaluation revealed normal dura in 39 patients (78%) and low dura in 11 (22%) [Figure 2].

Both radiological and surgical assessment confirmed the presence of Korner's septum [Figure 3] in 44 patients (88%) and confirmed the presence of mastoid emissary veins [Figure 4] in 15 patients (30%).

Radiological assessment revealed normal position of the sigmoid sinus in 43 patients (86%), anteriorly displaced sinus in 4 (8%), and laterally displaced sinus in 3 (6%), whereas surgical evaluation revealed normal sinus position in 38 patients (76%), anteriorly displaced sinus in 11 (22%), and laterally displaced sinus in 1 (2%) [Figure 5].

Radiological assessment of the jugular bulb revealed normal jugular bulb in 30 patients (60%), high bulb in 10 (20%), giant in 7 (14%), giant and high in 2 (4%), and dehiscent in 1 (2%), whereas surgical evaluation revealed normal bulb position in 35 patients (70%), high bulb in 8 (16%), giant in 4 (8%), giant and high in 2 (4%), and dehiscent in 1 (2%) [Figure 6].

Radiological assessment of mastoid segment of facial nerve canal revealed normal position in 47 patients (94%) and anteriorly displaced in 3 (6%), whereas surgical

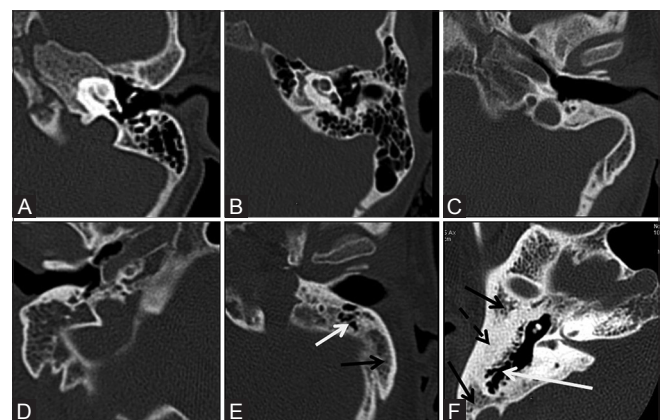


Figure 1 (A-F): Different patterns of mastoid pneumatization. (A) Normal pneumatization. (B) Hyperpneumatization. (C) Hypoplastic diploic mastoid, note deep anterior position of sigmoid sinus. (D) Diploic mastoid. (E) Partially pneumatic (white arrow) partially diploic (black arrow) mastoid. (F) Mixed, pneumatic (white arrow), diploic (black arrow) and sclerotic (dashed black arrow) mastoid

evaluation revealed normal position in 40 (80%), anteriorly displaced in 4 (8%) and laterally displaced in 6 (12%) [Table 1 and Figures 7, 8].

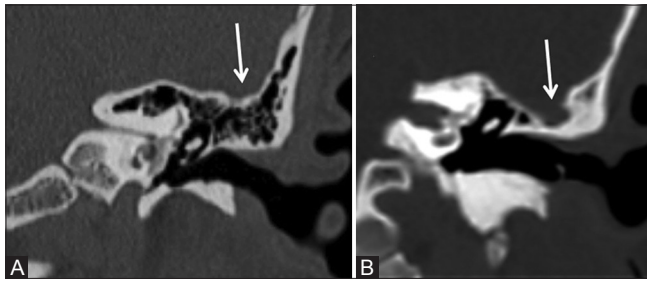


Figure 2 (A and B): Dura position. (A) Normal dura position lying at the same level of attic roof. (B) Low lying dura which is at a lower level than attic roof

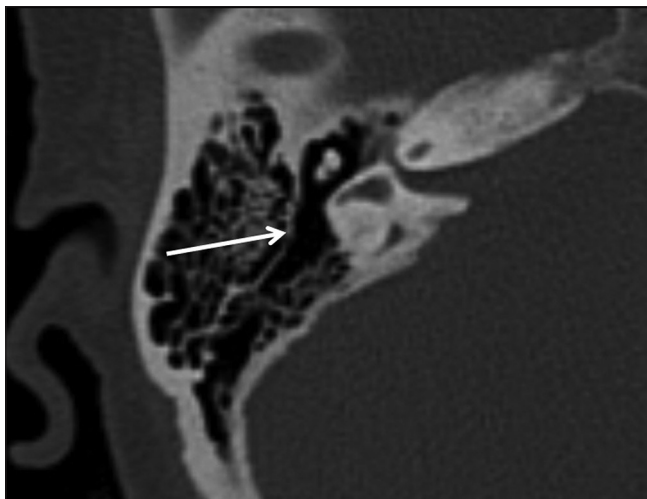


Figure 3: Korner's septum

Imaging was successful in detecting the position of facial nerve canal in 41 patients (82%) and failed in 9 patients (18%) [Table 2].

The axis of the basal turn of cochlea affects the position of the round window niche, which is reflected on the round window accessibility during surgery. Using the axial images, the axis of the basal turn of cochlea was compared with the axis of the ICA canal. When both were parallel, open accessibility during surgery was expected, whereas when cochlear axis was posteriorly rotated in relation to that of the ICA canal, difficulty in accessibility during surgery was expected [Figure 9]. Radiological assessment of round window accessibility suggested open accessibility in 41 patients (82%) and difficult accessibility in 9 (18%), whereas surgical assessment revealed open

Table 1: Radiological and surgical study of facial nerve canal position

Facial nerve position	Radiology	Surgery
Normal	47 (94%)	40 (80%)
Ant displaced	3 (6%)	4 (8%)
Lat displaced	0	6 (12%)
Total	50 (100%)	50 (100%)

Table 2: Cross tabulation of radiological and surgical assessment of facial nerve position

Radiology–Facial nerve position	Surgery–Facial nerve position			Total
	Normal	Ant displaced	Lat displaced	
Normal	39	2	6	47
Anteriorly displaced	1	2	0	3
Total	40	4	6	50

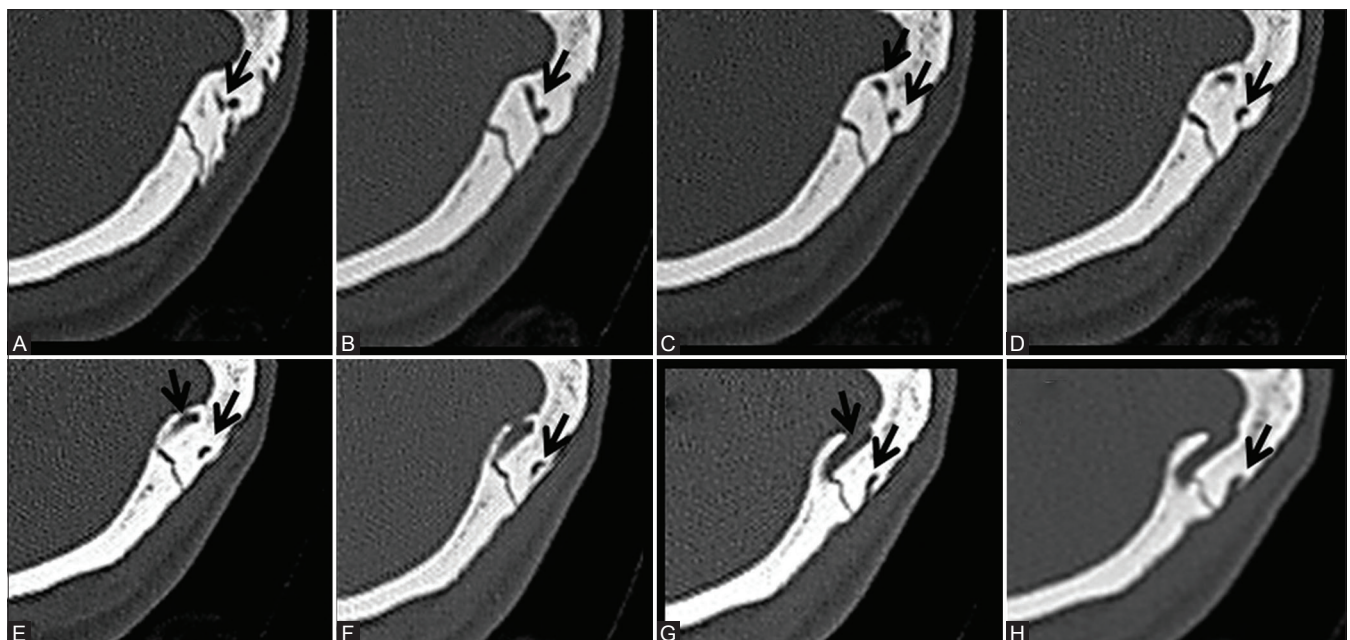


Figure 4 (A-H): Sequential axial CT images showing the course of mastoid emissary vein

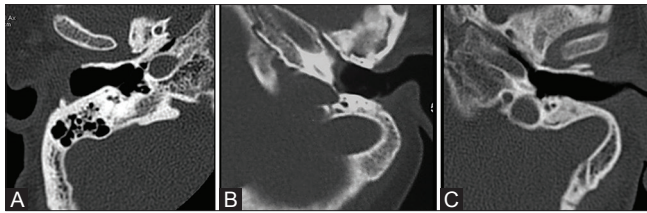


Figure 5 (A-C): Sigmoid sinus variations. (A) Normal position of sigmoid sinus. (B) Lateral position of sigmoid sinus. (C) Anterolateral position of sigmoid sinus. Note diploic hypoplastic mastoid in (B) and (C)

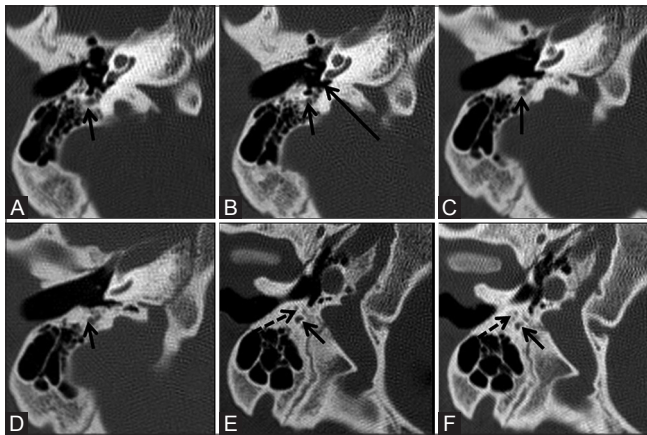


Figure 7 (A-F): Sequential axial images from superior to inferior showing normal position of the mastoid segment of facial N. and facial recess which lie posterior to the round window niche suggesting adequate visualization and open accessibility of the round window during surgery. Facial N. (short arrow), chorda tympani nerve (dashed arrow), round window niche (long arrow)

accessibility in 37 (74%) and difficult exposure in 13 (26%) [Table 3].

Further analysis found that 6 patients were true positive (had difficult accessibility on radiological and surgical assessment), 3 were false positive (open accessibility by surgery but radiology suggested difficult accessibility), 7 were false negative (difficult exposure in surgery but radiology suggested open accessibility), whereas 34 patients were true negative (open accessibility in both surgery and imaging) [Table 4]. The radiological assessment of round window accessibility had a sensitivity of 46.15% and specificity of 91.89% in the prediction of difficulty in accessibility. Thus, radiological assessment is a very good negative test for exclusion of difficult accessibility with a specificity of 91.89% and negative predictive value of 82.93%.

Radiological assessment of cochlear duct revealed patency of round window niche and cochlear basal turn in 46 patients (92%), partial obliteration of the basal turn of cochlea by labyrinthitis ossificans in 3 (6%) (bilateral in 1 patient and unilateral in 2 patients with positive history of meningitis in the 3 patients) [Figure 10] and obliteration of round window niche by otospongiotic foci in 1 (2%) [Figure 11], whereas surgical evaluation revealed cochlear duct patency in 46 patients (92%) with full electrode

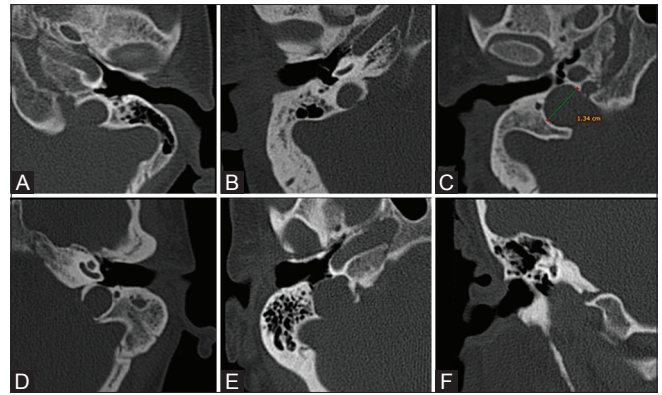


Figure 6 (A-F): Jugular bulb variations. (A) Normal jugular bulb; (B) high riding bulb; (C) giant bulb; (D) high riding giant bulb; (E and F) axial and coronal scans of dehiscent jugular bulb

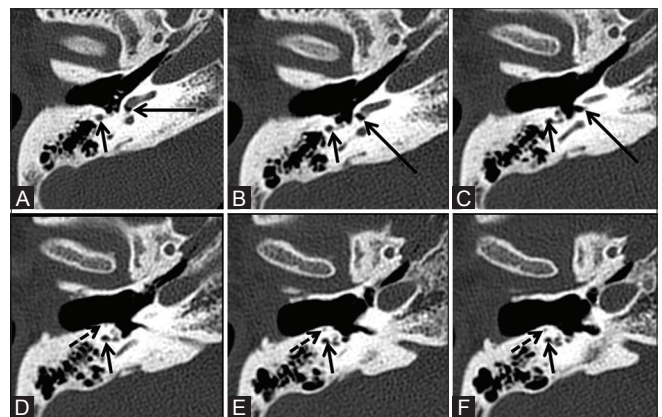


Figure 8 (A-F): Sequential axial images from superior to inferior showing abnormal anterior position of the mastoid segment of facial N. and facial recess in relation to the round window niche which is expected to hinder the visualization of the round window with difficult accessibility during surgery. Facial N. (short arrow), chorda tympani nerve (dashed arrow), round window niche (long arrow)

Table 3: Radiological and surgical study of round window accessibility

Round window accessibility	Radiology	Surgery
Open accessibility	41 (82%)	37 (74%)
Difficult accessibility	9 (18%)	13 (26%)
Total	50 (100%)	50 (100%)

Table 4: Cross tabulation of radiological and surgical assessment of round window accessibility

Radiology-round window nich	Surgery-round window nich		Total
	Open accessibility	Difficult	
Open accessibility	34 (true negative)	7 (false negative)	41
Difficult accessibility	3 (false positive)	6 (true positive)	9
Total	37	13	50

insertion, partial obliteration of the basal turn of cochlea by labyrinthitis ossificans in 3 (6%) for whom drilling and compressed electrode insertion was performed and obliteration of round window niche by otospongiotic foci

in 1 (2%) for whom compressed electrode insertion was performed after drilling of the niche.

Radiological assessment of VA and endolymphatic sac revealed normal duct and sac in 41 patients (82%) and dilated duct and sac in 9 (18%) [Figure 12]. Surgical evaluation revealed no CSF gusher in 44 patients (88%) and CSF gusher in 6 (12%).

Cochlear nerve presence was confirmed in all patients using sagittal oblique T2-weighted 3D Drive clear sequence on IAC on both sides [Figure 13].

Discussion

Imaging is essential in the preoperative evaluation of sensorineural hearing loss (SNHL) patients who are candidates for CI. Surgeons need to be alert regarding the anomalies and pathologies that may represent a potential surgical hazard or that may that may require modification of the surgical approach.

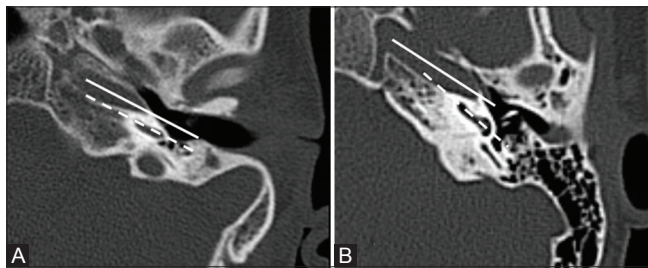


Figure 9 (A and B): Axis of the basal turn of cochlea (dashed arrow) in relation to axis of ICA canal (solid arrow). (A) The axis of cochlea basal turn is parallel to that of ICA canal with expected open accessibility of round window during surgery. (B) Posterior rotation of axis of cochlea basal turn in relation to that of ICA canal with expected difficult accessibility of round window during surgery

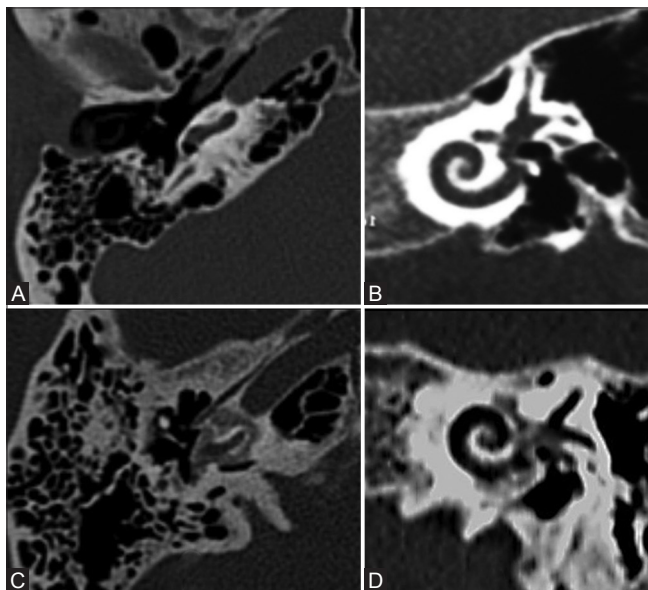


Figure 11 (A-D): Normal cochlea and otospongiosis. Normal cochlea on (A) axial CT, (B) oblique coronal MPR CT. Otospongiosis on (C and D)

In our study, CT was successful in detecting the true type of mastoid pneumatization in 47 patients (94%). This is in accordance to a study performed by authors who found strong correlation between the radiological assessment and the surgical findings in the mastoid air cell complex.^[23]

Our study revealed that imaging was successful to detect the true position of the middle cranial fossa dura in 49 patients (98%). This is in line with other authors who found a strong correlation between the radiological assessment and the surgical findings in the assessment of tegmen position.^[23]

Both radiological and surgical assessments confirmed the presence of Korner's septum in 44 patients (88%) and the presence of mastoid emissary veins in 15 patients (30%).

The sigmoid sinus is an important landmark in mastoidectomy surgery. Drilling is usually performed

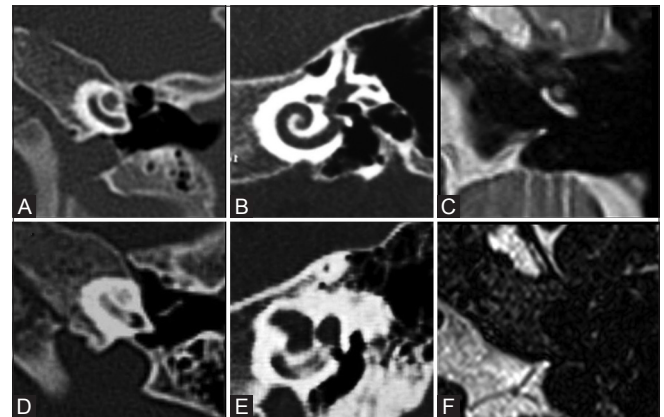


Figure 10 (A-F): Normal cochlea and labyrinthitis ossificans. Normal cochlea on (A) axial CT, (B) oblique coronal MPR CT, (C) axial MRI. Labyrinthitis ossificans on (D-F)

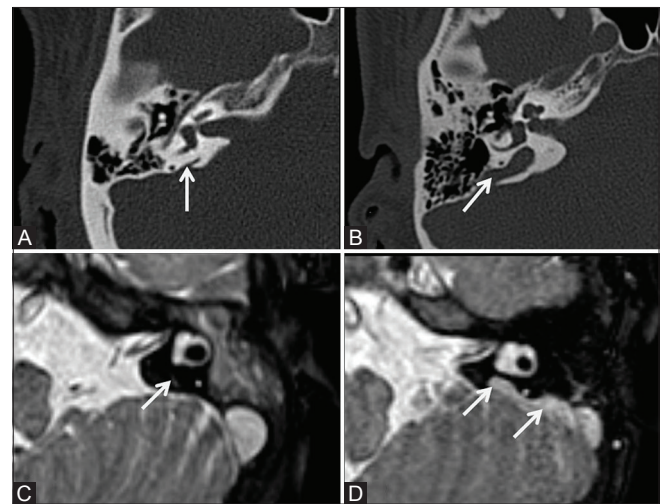


Figure 12 (A-D): Normal and dilated vestibular aqueduct. (A and B) CT shows (A) normal vestibular aqueduct, (B) dilated vestibular aqueduct. (C and D) MRI shows (C) normal vestibular aqueduct, (D) dilated vestibular aqueduct and endolymphatic sac

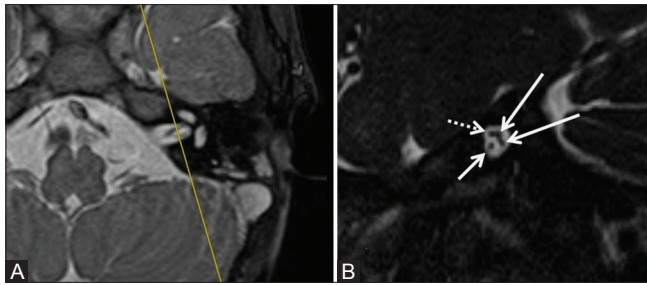


Figure 13 (A and B): Normal cochlear nerve on MRI. (A) Axial MRI on left IAC showing the plane at which sagittal oblique images were obtained. (B) sagittal oblique at mid IAC showing the cochlear nerve anteroinferiorly (short white arrow), facial nerve anterosuperiorly (dashed white arrow), superior and inferior vestibular nerves posteriorly (long white arrows)

anterior to it. An unusual anterior position of the sigmoid sinus can lead to surgical difficulties or may lead to a risk of profuse bleeding. True position of the sigmoid sinus was detected by imaging in 36 patients (72%) in our study. This is in accordance to the study performed Park *et al.* who found a strong correlation between radiological assessment and surgical findings in the sigmoid sinus position.^[23] In our study, only 1 patient had lateral position of the sigmoid sinus during surgery with difficult round window accessibility. This suggested that lateral sinus position had a minimal impact on the degree of round window accessibility. Park *et al.* found that lateral sinus position had no relation with difficulty regarding cortical mastoidectomy.^[24]

Our study showed that imaging could evaluate the jugular bulb in 40 patients (80%) with sensitivity of 63.2% and specificity of 76.4%. This is contrary to a study performed by Júnior *et al.* who found that the sensitivity of CT was 36.36% and the specificity was 86.36%.^[25] This can be explained by the fact that in imaging the jugular bulb is considered high if it reaches the level of the basal turn of cochlea regardless of whether it is hiding round window niche; however, surgeons are dealing only with the high bulb that may interfere with the accessibility of round window.

During posterior tympanotomy, the surgeon can approach the round window niche and promontory where a cochleostomy is carried out for CI electrode array insertion. The mastoid segment of the facial nerve and the chorda tympani nerve could be injured in cases of narrow facial recess. We used axial images to assess the orientation of round window niche and its relation to the position of the mastoid segment of facial nerve. Some authors have recommended the use of oblique sagittal reformatted CT images to assess the tympanic and mastoid segments of the facial nerve in one image.^[11,12] Others have recommended drawing multiple lines and measuring multiple angles using different oblique reformatted images.^[13] In our study, imaging was successful in detecting the true position of facial nerve canal in 41 patients (82%). We also found that position of the facial nerve had minimal relation with the

degree of round window accessibility. Of the 10 patients who had displacement of the facial nerve during surgery, only 3 had difficult round window accessibility.

Assessment of round window accessibility revealed that, among the 50 patients, imaging was true positive in 6 patients and true negative in 34, with a total of 40 patients (80%). Imaging has a sensitivity of 46.15% and specificity of 91.89% in the prediction of difficulty in accessibility. Thus, radiological assessment is a very good negative test for exclusion of difficulty in accessibility with a specificity of 91.89% and negative predictive value of 82.93%. This is in accordance to the study by Pendem *et al.* and Saki *et al.*^[26,27]

Radiological assessment of round window niche and cochlear duct patency in our study was similar to the surgical findings. This is in accordance to the study performed by Saki *et al.* who found that the results of the surgery and imaging regarding the patency of cochlear duct were similar.^[27]

As regards the imaging assessment of vestibular aqueduct and endolymphatic sac and its correlation with occurrence of CSF gusher during surgery, we found that 3 patients in our study who had dilated vestibular aqueduct and endolymphatic sac by imaging and had no CSF gusher during surgery. Imaging had a sensitivity of 66.7% and specificity of 95.7% in prediction of the presence of CSF gusher in case of dilated VA. Thus, imaging assessment of VA is a very good negative test for exclusion of CSF gusher in case of normal duct. Thus, we conclude that the mere presence of a wide VA and dilated endolymphatic sac is not an indication that gusher will occur during surgery. This finding is supported by other authors.^[25]

Conclusion

Cochlear implantation has become an accepted treatment in patients with severe-to-profound sensorineural hearing loss. Radiologists have an important role in evaluating these patients as the number of procedures escalates. Anomalies and anatomical variants of temporal bone are common. Some variations are potential surgical hazards, and the radiologist must be familiar with these imaging findings.

Financial support and sponsorship

Nil.

Conflicts of interest

There are no conflicts of interest.

References

1. Joshi VM, Navlekar SK, Kishore GR, Reddy KJ, Kumar EC. CT and MR imaging of the inner ear and brain in children with congenital sensorineural hearing loss. *Radiographics* 2012;32:683-98.

2. Witte RJ, Lane JI, Driscoll CL, Lundy LB, Bernstein MA, Kotsenas AL, *et al.* Pediatric and adult cochlear implantation. *Radiographics* 2003;23:1185-200.
3. Taha T, Wahba H, Ibrahim AS, Abd Elazim Y. Cochlear implant tailored imaging protocol: What clinicians need to know. *Egyptian J Radiol Nucl Med* 2015;46:33-43.
4. Karaca CT, Toros SZ, Noseri HK. Analysis of anatomic variations in temporal bone by radiology. *Int Adv Otol* 2012;8:239-43.
5. Dupuch KM, Meyer B. Cochlear implant assessment: Imaging issues. *Eur J Radiol* 2001;40:119-32.
6. Hindi K, Alazzawi S, Raman R, Prepageran N, Rahmat K. Pneumatization of mastoid air cells, temporal bone, ethmoid and sphenoid sinuses. Any correlation? *Indian J Otolaryngol Head Neck Surg* 2014;66:429-36.
7. Koc A, Karaaslan O, Koc T. Mastoid air cell system. *Otoscope* 2004;4:144-54.
8. Kontorinis G, Lenarz T, Schwab B. Anatomic limitations in implantation of middle ear transducer and carina middle ear implants. *Laryngoscope* 2010;120:2289-93.
9. Reis CVC, Deshmukh V, Zabramski JM, Crusius M, Deshmukh P, Preul MC, *et al.* Anatomy of the mastoid emissary vein and venous system of the posterior neck region: Neurosurgical implications. *Neurosurgery* 2007;61:193-201.
10. Kim CW, Oh SJ, Kim HS, Ha SH, Rho YS. Analysis of axial temporal bone computed tomography scans for performing a safe posterior tympanotomy. *Eur Arch Otorhinolaryngol* 2008;265:887-91.
11. Hasaballah MS, Hamdy TA. Evaluation of facial nerve course, posterior tympanotomy width and visibility of round window in patients with cochlear implantation by performing oblique sagittal cut computed tomographic scan temporal bone. *Egyptian J Otolaryngol* 2014;30:317-21.
12. Chuang MT, Chiang IC, Liu GC, Lin WC. Multi-detector row CT demonstration of inner and middle ear structures. *Clin Anat* 2006;19:337-44.
13. McRackan TR, Reda FA, Rivas A, Noble JH, Dietrich MH, Dawant BM, *et al.* Comparison of cochlear implant relevant anatomy in children versus adults. *Otol Neurotol* 2012;33:328-34.
14. Weissman JL, Hirsch BE. Imaging of Tinnitus: A Review. *Radiology* 2000;216:342-9.
15. Filipovic B, Gjuric M, Hat J, Glunc I. High mega jugular bulb presenting with facial nerve palsy and severe headache. *Skull Base* 2010;20:465-8.
16. Caldemeyer KS, Mathews VP, Azzarelli B, Smith RR. The jugular foramen: A review of anatomy, masses, and imaging characteristics. *Radiographics* 1997;17:1123-39.
17. Ong CK, Chong VHF. Imaging of jugular foramen. *Neuroimag Clin N Am* 2009;19:469-82.
18. Kawano H, Tono T, Schachern PA, Paparella MM, Komune S. Petrous high jugular bulb: A histological study. *Am J Otolaryngol* 2000;21:161-8.
19. Offiah CE, Ramsden RT, Gillespie JE. Imaging appearances of unusual conditions of the middle and inner ear. *Br J Radiol* 2008;81:504-14.
20. Davidson HC. Imaging of the temporal bone. *Magn Reson Imaging Clin N Am* 2002;10:573-613.
21. Okamoto K, Ito J, Furusawa T, Sakai K, Tokiguchi S. Large vestibular aqueduct syndrome with high CT density and high MR signal intensity. *AJNR Am J Neuroradiol* 1997;18:482-4.
22. Valvassori GE, Clemis JD. The large vestibular aqueduct syndrome. *Laryngoscope* 1978;88:723-8.
23. Vlastarakos PV, Kiprouli C, Pappas S, Xenelis J, Maragoudakis P, Troupis G, *et al.* CT scan versus surgery: How reliable is the preoperative radiological assessment in patients with chronic otitis media. *Eur Arch Otorhinolaryngol* 2012;269:81-6.
24. Park E, Amoodi H, Kuthubutheen J, Chen JM, Nedzelski JM, Lin VY. Predictors of round window accessibility for adult cochlear implantation based on pre-operative CT scan: A prospective observational study. *J Otolaryngol Head Neck Surg* 2015;44:20.
25. Júnior L, Rocha MD, Walsh PV, Antunes CA, Calhau CM. Evaluation by imaging methods of cochlear implant candidates: Radiological and surgical correlation. *Rev Bras Otorrinolaringol* 2008;74:395-400.
26. Pendem SK, Rangasami R, Kumar AR, Sai PMV, Natarajan P. Preoperative HRCT temporal bone measurement useful for cochlear implantation in children: Correlation between pre-op HRCT and surgical measurement. *Int J Recent Trends Sci Technol* 2015;14:460-4.
27. Saki N, Saki S, Zarandy MM. The first step toward improving cochlear implant insertion using a new technique called slide method (Motasaddi Method). *Int J Pharm Res Allied Sci* 2016;5:110-3.