

Original Article

Soft Coagulation Using Hemostatic Forceps for Prevention of Postendoscopic Papillectomy Hemorrhage

Nobuhiko Fukuba, Hiroki Sonoyama, Ichiro Moriyama¹, Shunji Ishihara, Yoshikazu Kinoshita

Department of Internal Medicine II, Shimane University School of Medicine, ¹Division of Cancer Center, Shimane University Hospital, Shimane, Japan

ABSTRACT

Aim: Few reports of the prophylactic use of soft coagulation with hemostatic forceps for postendoscopic papillectomy hemorrhage (PEPH) have been presented. The aim of this study was to clarify the utility of that procedure for prophylaxis. **Materials and Methods:** From April 2009 to March 2012, PEPH was treated in four patients after the development of the condition with a conventional procedure at our institution. Thereafter, from April 2012 to March 2016, soft coagulation using hemostatic forceps was performed as prophylactic hemostasis following an EP in five patients. For the latter procedure, the hemostatic forceps device (FD411-QR, Olympus, Tokyo, Japan) was used in a closed position, with the coagulation wave set at 60 W (VIO 300D; ERBE, Tubingen, Germany). The primary outcome was the onset of PEPH, which was defined as a decrease in hemoglobin ≥ 2 g/dL after EP. Secondary endpoints were the success rate and the incidence of adverse events of soft coagulation using hemostatic forceps for emergency bleeding cases after EP. **Results:** The incidence of PEPH was 20% (1 of 5 cases) in the prophylactic procedure group, which was lower than that in the conventional procedures group (75%, 3 of 4 cases), though the difference was not statistically significant ($P = 0.206$, Fisher's exact test). All cases of PEPH were successfully treated by soft coagulation using hemostatic forceps. **Conclusion:** Soft coagulation with hemostatic forceps may be suitable for use as a routine technique following EP to prevent PEPH.

KEYWORDS: Endoscopic papillectomy, hemorrhage, hemostatic forceps, prevention

INTRODUCTION

An endoscopic papillectomy (EP) procedure is generally performed for treatment of a papillary adenoma,^[1] whereas post-EP hemorrhage (PEPH) is a clinically serious adverse event associated with that procedure.^[2] As a result, various methods of hemostasis, including clipping, hypertonic saline-epinephrine local injection, and argon plasma coagulation, have been reported for treatment of PEPH.^[3] In addition to those, hemostatic forceps, a device used mainly for coagulation of exposed vessel in cases of endoscopic mucosal dissection, have recently been utilized to perform soft coagulation as a PEPH treatment.^[4] We have used hemostatic forceps for treatment of both emergency cases of PEPH and its prevention. However, few studies have assessed such prophylactic use, and

thus, we conducted this retrospective study to clarify its utility.

MATERIALS AND METHODS

We reviewed consecutive patients who underwent EP from April 2009 to March 2016 at our hospital. Second-look endoscopy was performed within 1 week in all cases of both groups with or without bleeding or anemia. During the early period (April 2009–March 2012), PEPH was treated after it developed with

Address for correspondence: Dr. Nobuhiko Fukuba, Department of Internal Medicine II, Faculty of Medicine, Shimane University, 89-1, Enya-Cho, Izumo, Shimane, Japan.
E-mail: fnat98@yahoo.co.jp

This is an open access journal, and articles are distributed under the terms of the Creative Commons Attribution-NonCommercial-ShareAlike 4.0 License, which allows others to remix, tweak, and build upon the work non-commercially, as long as appropriate credit is given and the new creations are licensed under the identical terms.

For reprints contact: reprints@medknow.com

How to cite this article: Fukuba N, Sonoyama H, Moriyama I, Ishihara S, Kinoshita Y. Soft coagulation using hemostatic forceps for prevention of postendoscopic papillectomy hemorrhage. J Dig Endosc 2018;9:114-7.

Access this article online

Quick Response Code:



Website: www.jdeonline.in

DOI: 10.4103/jde.JDE_41_17

conventional procedures, including clipping, hypertonic saline-epinephrine local injection, argon plasma coagulation, and soft coagulation with hemostatic forceps (conventional procedures group). On the other hand, from April 2012 to March 2016, soft coagulation with a hemostatic forceps device (FD411-QR, Olympus, Tokyo, Japan) was performed prophylactically immediately after EP or on the following day (prophylactic procedure group). Soft coagulation was done only when there is a “red spot.” Red spots were defined as red-colored parts of ulcer bed tissue with a clear boundary and seemed to include vessels. Many of the red spots were present at the periphery of the ulcer. Only red spots were indicated for soft coagulation, while the whitish part of ulcer tissue was not treated with soft coagulation. If the endoscope did not show any red spots, soft coagulation was not added. The hemostatic forceps device was used in a closed position without grasping or strongly pressing the mucosa to avoid excessive coagulation of the deeper layer. The coagulation wave was set at 60 W (VIO 300D, ERBE, Tübingen, Germany), and the energization time was approximately 2 s or less. Second-look endoscopy was done for all patients of both groups within a week after EP. Either JF260V or TJF260V (Olympus, Tokyo, Japan) was used in this study. The primary outcome of the present study was the onset of PEPH, which was defined as a decrease in hemoglobin ≥ 2 g/dL after EP regardless of the presence of hematemesis or melena, and we compared the two groups. In addition, as a secondary endpoint, the success rate and the incidence of the adverse event of soft coagulation using hemostatic forceps were examined retrospectively.

RESULTS

In this retrospective study, nine patients were enrolled, four of whom were included in the conventional procedures group and five in the prophylactic procedure group. Backgrounds and outcomes are shown in Table 1. Age and gender were similar between the groups. The mean maximum diameter of the resected specimen was 15 mm in the prophylactic procedure group, which was slightly smaller as compared with the conventional procedures group (21 mm) though the difference was not significant.

PEPH occurred in three of the four patients in the conventional procedures group, while only one of the five patients in the prophylactic procedure group developed that condition. All cases of PEPH were successfully treated by endoscopic hemostasis. The incidence of PEPH was 20% in the prophylactic procedure group

and 75% in the conventional procedures group though the difference between them was not statistically significant ($P = 0.206$, Fisher’s exact test) [Table 2].

Three of the five patients in the prophylactic treatment group had at least one red spot and received soft coagulation (e.g., representative case report: case 1). On the other hand, two patients had no red spots on the day of EP. One of the two patients received soft coagulation for slight bleeding on the next day. This case did not meet the criteria of PEPH, since the value of hemoglobin was not decreased (representative case report: case 2). The other case did not have any red spots on both the day of EP and the next day, but after 5 days, hemoglobin was found to decrease by >2 g/dl, and he was the only patient who met the criteria of PEPH in the prophylactic treatment group. Four cases of emergency bleeding after EP were experienced in this study, but in all cases, hemostasis was obtained using soft coagulation using hemostatic forceps. There was a case of abdominal pain after hemostasis, but it was relieved promptly by conservative treatment.

Representative cases report

Case 1 (prophylactic group)

A 60-year-old woman underwent EP for an adenoma of the ampulla [Figure 1a], and the pathological examination revealed curative resection. Although no hemorrhaging was noted immediately after the procedure, second-look endoscopy performed the next day showed a few reddish spots in the ulcer bed [Figure 1b]. At the time of the

Table 1: Comparisons of patient backgrounds, postendoscopic papillectomy hemorrhage incidence, and complications between conventional procedures and prophylactic procedure groups

	Conventional procedures group (n=4)	Prophylactic procedure group (n=5)	P
Mean age (years)	69	67	0.80*
Male (%)	75	80	1.00#
Mean maximum diameter of resected specimen (mm)	21	15	0.39*

*Mann–Whitney U-test, #Fisher’s exact test

Table 2: Comparisons of postendoscopic papillectomy hemorrhage incidence between conventional procedures and prophylactic procedure groups

	Conventional procedures group (n=4)	Prophylactic procedure group (n=5)	P
Incidence of PEPH* (%)	75	20	0.21#

#Fisher’s exact test. PEPH=Postendoscopic papillectomy hemorrhage

second-look endoscope, we coagulated to only the red points by slightly touching those spots with the end of the clamped hemostatic forceps, which resulted in them changing to have a whitish appearance [Figure 1c]. The patient was discharged according to schedule without any evidence of bleeding or complications associated with the hemostasis technique.

Case 2 (prophylactic group)

In another representative case, a 59-year-old male taking oral warfarin for deep vein thrombosis was diagnosed with an adenoma of the ampulla. Warfarin administration was discontinued from 1 week before, heparin intravenous injection (10,000 units/day) was started instead, and it was discontinued from 6 h before EP. Just before performing EP, we confirmed that the international normalized ratio was 2 or less. In this case, soft coagulation was not performed immediately after EP because red spots were not revealed. Even before heparin was administered again, a second-look endoscopy examination on the next day after EP showed asymptomatic bleeding from the ulcer [Figure 2a], for which our hemostatic forceps technique was successfully used for soft coagulation [Figure 2b]. The bleeding did not cause any symptoms and a decrease of hemoglobin value, and therefore, we judged that this case did not fall under PEPH cases. The pathological examination revealed adenoma with curative resection.

DISCUSSION

Endoscopic treatment for a papillary adenoma was reported by Binmoeller *et al.* in 1993 as an endoscopic snare excision of benign adenomas of the papilla of Vater.^[5] Thereafter, the procedure, termed EP or endoscopic ampullectomy, has been used throughout the world, as it is less invasive than surgical resection and can be utilized as a standard treatment for adenomas of the ampulla. However, according to a review by De Palma *et al.*, the overall rate of complications after EP varies from 8% to 35%, with the most common being pancreatitis (5%–15%) and bleeding (2%–16%).^[6] Tsuji *et al.* also noted that PEPH was observed in 21 (18.2%)

of 115 patients though endoscopic hemostasis was difficult to perform in only one of those cases.^[7] Several endoscopic hemostasis techniques for treatment of PEPH have been proposed. Mutignani *et al.* reported that a technique of injection of diluted fibrin glue might be an effective endoscopic modality to treat refractory post-ERCP bleeding including PEPH,^[8] while Ito *et al.* presented an argon plasma coagulation technique for emergency hemostasis in PEPH cases.^[3] In addition, Klein *et al.* found that nonpulsatile focal intraprocedural bleeding unresponsive to snare tip soft coagulation could be controlled with the use of coagulation forceps in most cases.^[4] In this study, we examined the results of soft coagulation using hemostatic forceps for four patients who had emergency bleeding after EP and succeeded in all cases as a result. Accordingly, endoscopic hemostasis for emergency PEPH seems to be an effective treatment method. However, the usefulness of endoscopic treatment for prevention of the condition remains unclear. In the present study, we investigated the utility of an endoscopic prophylactic hemostatic procedure to prevent PEPH, with focus on the use of soft coagulation with hemostatic forceps.

Procedures for obtaining soft coagulation with hemostatic forceps have developed with the spread of endoscopic submucosal dissection, and a recent study noted its use for gastroduodenal ulcer bleeding.^[9] With soft coagulation, one of the modes available in electrosurgical workstations produced by ERBE such as the VIO 300D, temperature is adjusted to just below the boiling point and treated tissue shrinks with dehydration and carbonization, which seals the lumen of the vessel to obtain hemostasis.^[10] Nunoue *et al.* reported that soft coagulation with hemostatic forceps achieved primary hemostasis for peptic ulcer bleeding in 96% of their cases, which was significantly higher than the 67% of success rate in the heater probe thermocoagulation group ($P < 0.0001$).^[10] Kim *et al.* found that both efficacy and safety of soft coagulation using hemostatic

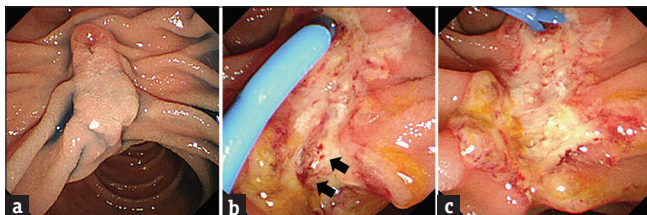


Figure 1: (a) A 60-year-old woman underwent endoscopic papillectomy for an adenoma of the ampulla. (b) Second-look endoscopy performed the next day showed a few reddish spots in the ulcer bed (arrow). (c) Soft coagulation using hemostatic forceps was performed for prevention of the late-onset bleeding and reddish spots became whitish in appearance

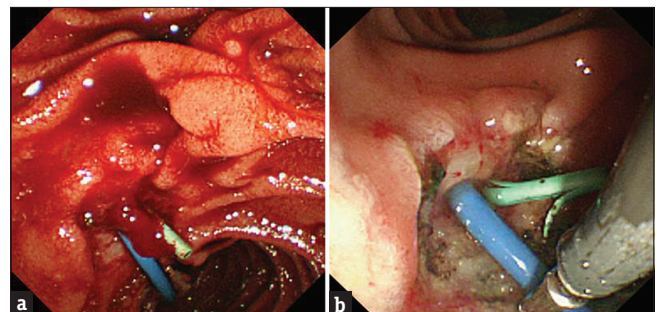


Figure 2: (a) A second-look endoscopy performed the next day after endoscopic papillectomy revealed bleeding from the ulcer. (b) Hemostatic forceps were used for soft coagulation, which controlled postendoscopic papillectomy hemorrhage without complications

forceps were not inferior to those of argon plasma coagulation performed for peptic ulcers bleeding. Furthermore, Arima *et al.* noted that the incidence of recurrent bleeding after hemostasis was 2% in patients who received soft coagulation, which was lower than that of the clipping group (10%).^[11] The same as with other devices, soft coagulation using hemostatic forceps has a high hemostatic capability and may also result in a decrease in recurrent bleeding as compared with clipping. Furthermore, the hemostatic forceps device is easily handled with the elevator of an ERCP scope as compared to a clipping device, which is more difficult because of the complexity of operation. With these issues in mind, we focused on soft coagulation using hemostatic forceps as a method to prevent bleeding after EP and found this prophylactic procedure to be suitable as a routine technique from the standpoint of the convenience of operation.

The difference in regard to PEPH incidence between the present groups was not significant, likely because of the small sample size. For obtaining data to show a significant difference, a sample size with an alpha-error of 0.05 and power of 0.8 would be required, indicating that 15–20 cases would be needed in each group. On the other hand, the mean maximum diameter of the resected specimen was 15 mm in the prophylactic procedure group, smaller as compared with the conventional procedures group (21 mm). We were unable to avoid selection bias, which also might have influenced the results. A future prospective study for the accumulation of additional cases would be helpful.

Financial support and sponsorship

Nil.

Conflicts of interest

There are no conflicts of interest.

REFERENCES

1. Napoleon B, Gincul R, Ponchon T, Berthiller J, Escourrou J, Canard JM, *et al.* Endoscopic papillectomy for early ampullary tumors: Long-term results from a large multicenter prospective study. *Endoscopy* 2014;46:127-34.
2. Irani S, Arai A, Ayub K, Biehl T, Brandabur JJ, Dorer R, *et al.* Papillectomy for ampullary neoplasm: Results of a single referral center over a 10-year period. *Gastrointest Endosc* 2009;70:923-32.
3. Ito K, Fujita N, Noda Y, Kobayashi G, Obana T, Horaguchi J, *et al.* Impact of technical modification of endoscopic papillectomy for ampullary neoplasm on the occurrence of complications. *Dig Endosc* 2012;24:30-5.
4. Klein A, Tutticci N, Bourke MJ. Endoscopic resection of advanced and laterally spreading duodenal papillary tumors. *Dig Endosc* 2016;28:121-30.
5. Binmoeller KF, Boaventura S, Ramsperger K, Soehendra N. Endoscopic snare excision of benign adenomas of the papilla of Vater. *Gastrointest Endosc* 1993;39:127-31.
6. De Palma GD. Endoscopic papillectomy: Indications, techniques, and results. *World J Gastroenterol* 2014;20:1537-43.
7. Tsuji S, Itoi T, Sofuni A, Mukai S, Tonozuka R, Moriyasu F, *et al.* Tips and tricks in endoscopic papillectomy of ampullary tumors: Single-center experience with large case series (with videos). *J Hepatobiliary Pancreat Sci* 2015;22:E22-7.
8. Mutignani M, Seerden T, Tringali A, Feisal D, Perri V, Familiari P, *et al.* Endoscopic hemostasis with fibrin glue for refractory postsphincterotomy and postpapillectomy bleeding. *Gastrointest Endosc* 2010;71:856-60.
9. Fujishiro M, Abe N, Endo M, Kawahara Y, Shimoda R, Nagata S, *et al.* Retrospective multicenter study concerning electrocautery forceps with soft coagulation for nonmalignant gastroduodenal ulcer bleeding in Japan. *Dig Endosc* 2010;22 Suppl 1:S15-8.
10. Nunoue T, Takenaka R, Hori K, Okazaki N, Hamada K, Baba Y, *et al.* A randomized trial of monopolar soft-mode coagulation versus heater probe thermocoagulation for peptic ulcer bleeding. *J Clin Gastroenterol* 2015;49:472-6.
11. Arima S, Sakata Y, Ogata S, Tominaga N, Tsuruoka N, Mannen K, *et al.* Evaluation of hemostasis with soft coagulation using endoscopic hemostatic forceps in comparison with metallic hemoclips for bleeding gastric ulcers: A prospective, randomized trial. *J Gastroenterol* 2010;45:501-5.