

Original Article

Unique Pattern of True Foreign-Body Ingestion in the Valley of Kashmir; Sharp Foreign Bodies Outnumbering the Blunt Ones

Nisar Ahmad Shah, Showkat Ahmad Kadla¹, Asif Iqbal Shah¹, Bilal Ahmad Khan¹, Inaam Ul Haq², Shabir Ahmad Shiekh¹, Aijaz Ahmad Malik³

Departments of Medicine and Gastroenterology, ¹Gastroenterology, ²Social and Preventive Medicine, Government Medical College, ³Consultant, Department of Minimal-Access Surgery, Shifa Medical Centre, Srinagar, Jammu and Kashmir, India

ABSTRACT

Background and Aims: Foreign-body ingestion is a common phenomenon, especially in children. In normal adults, foreign-body ingestion is usually accidental and mostly ingestion occurs with food and impaction is a result of structural abnormalities of the upper gastrointestinal tract (UGIT). However, accidental ingestion of nonfood products is unusual; especially ingestion of pins (scarf or safety pins) and needles is unknown. We come across ingestion of these unusual/sharp foreign bodies routinely from the past few years. The aim of this study was to observe, over a period of 1 year, the spectrum of nonfood or true foreign-body ingestion in our community and to see the impact of an early endoscopy on outcome or retrieval of the ingested objects. **Materials and Methods:** In a prospective observational study, we studied the profile of foreign-body ingestion in normal individuals of all ages and both sexes, excluding the individuals with any structural abnormalities of the gut and the people with psychiatric ailment. **Results:** Of total 51 patients with foreign-body ingestion, 42 (82%) were 20 or <20 years of age with females constituting 86.3% of the total and males constituting only 13.7%. Foreign bodies ingested included 38 pins (74.5%), seven coins (13.7%), four needles (7.8%), and one denture and a nail (2%) each. Overall 26 (51%) foreign bodies were seen in UGIT (within reach of retrieval) at the time of endoscopy and all of them were retrieved. Nineteen (37.3%) patients reported within 6 h of ingestion, and majority of them (16 = 84.2%) had foreign bodies within UGIT and all of them were removed. Those patients ($n = 32$; 62.7%) who reported beyond 6 h, only 10 (31.25%) had foreign bodies in UGIT as a result of which the success rate of removal in these patients was only 32%. **Conclusion:** Most of our patients were young females and the common foreign bodies ingested were sharp including scarf pins followed by coins and needles. The success rate of retrieval was high in those who reported within 6 h of ingestion of foreign body. The rate of retrieval was 100% if foreign body was found on esophagogastroduodenoscopy. Hence, we recommend an early endoscopy in these patients and some alternative to use of scarf pins.

KEYWORDS: Endoscopy, foreign bodies, Kashmir, safety pins, sharp foreign bodies

INTRODUCTION

Nonnutritious, undesirable, unwanted material or a thing swallowed or aspirated intentionally or unintentionally that may be potentially or seriously harmful to health constitutes the aerodigestive foreign bodies (FBs).

Address for correspondence: Dr. Nisar Ahmad Shah, Department of Medicine and Gastroenterology, Government Medical College, Srinagar, Jammu and Kashmir, India. E-mail: nisarshah19@gmail.com

This is an open access journal, and articles are distributed under the terms of the Creative Commons Attribution-NonCommercial-ShareAlike 4.0 License, which allows others to remix, tweak, and build upon the work non-commercially, as long as appropriate credit is given and the new creations are licensed under the identical terms.

For reprints contact: reprints@medknow.com

How to cite this article: Shah NA, Kadla SA, Shah AI, Khan BA, Haq IU, Shiekh SA, et al. Unique pattern of true foreign-body ingestion in the valley of Kashmir; sharp foreign bodies outnumbering the blunt ones. J Dig Endosc 2019;10:XX-XX.

Access this article online

Quick Response Code:



Website: www.jdeonline.in

DOI: 10.4103/jde.JDE_74_18

In US, 1500 people die each year from either swallowing or aspirating FBs.^[1] Most of them are children who ingest small toys and coins.^[2] Normal adults are usually not affected but may accidentally ingest FBs, if they are careless about the objects or if they have a cognitive impairment, poor vision or are intoxicated.^[3,4] The type of FBs depends on the objects available and the frequency with which they are used. In general, in adults, the most commonly ingested FBs include toothbrushes, nails, and dental prosthesis. People with dementia and those having psychiatric ailments are most likely to ingest a FB intentionally; however, patients with bulimia may inadvertently swallow objects while trying to induce vomiting.^[5,6] Some people may have history of recurrent FB ingestion (psychiatric population) while others may ingest it for secondary gains (incarcerated criminals and drug traffickers “body packers”). In the normal population, dementic patients, incarcerated criminals, and people with bulimia may ingest FBs. The type of FBs may vary from community to community depending on the easy availability of objects that are intentionally or unintentionally put in mouth.

The most commonly seen upper gastrointestinal tract (UGIT) FB in US in adults is meat bolus and bone chips, and in children, the same includes coins, toys, magnets, and batteries.^[6] In some European countries, the commonly ingested FBs include Fishbone, bones, and dentures; in China, it is food bolus, fish bones, dental prostheses, and bones that are commonly ingested, while as in the Middle East, the same may include coins, meat boluses, and bones.^[7-9] In Africa and the Indian subcontinent, coins, meat boluses, and dentures are the most commonly expected FBs that could be ingested.^[10,11] Since the pattern and profile of FB ingestion have not so far been reported anywhere from India, and also the unique pattern of UGIT FBs that was observed in our set up over some time in which there was a predominance of pins and needles compelled us to observe it in a prospective manner.

MATERIALS AND METHODS

This was a prospective, observational study conducted in the Department of Gastroenterology, Government Medical College, Srinagar, Jammu and Kashmir, India, from January 2014 to December 2015. After the Institutional Ethical Committee Clearance, patients of all ages and both sexes who presented to the department with the history of accidental or intentional ingestion of a true FB were included, patient's vitals were checked, physical examination and radiological examination done before contemplating FB removal. If FB was not located on plain radiograph, a computed tomography scan was

ordered for proper localization of FB. To keep the study limited to the general population and true FBs only, the following patients were excluded from the study:

1. Those with psychiatric ailments
2. Incarcerated criminals
3. People with underlying dysphagia and bulimia
4. Food bolus impaction
5. Those having taken FB for secondary gains.

RESULTS

In this prospective, observational study, we enrolled 51 patients [Table 1], of which 44 (86.3%) were female and seven (13.7%) were male with an average age of 17.18 years (range, 6–67 years); 29 (56.36%) were from rural and 22 (43.13%) from urban background. Most of our patients were young with 39 (76.47%) being 20 or <20 years and only 12 (23.52%) were >20 years of age. Majority ($n = 44$) of our patients were females. Out of total, only 37.3% of patients presented within 6 h of ingestion of FB, whereas 62.7% presented late. Thirty (58.8%) patients were endoscoped during the day and 21 (41.2%) were endoscoped at odd hours. A unique pattern was observed [Table 1] in the sense that there were 38 (74.5%) pins, seven (13.7%) coins, four (7.8%) needles, and one (2%) nail and one (2%) denture. The sharp FBs outnumbering blunt ones.

Of 51 patients, 27 (52.9%) had no FB within the reach of upper GI endoscopy, and of these, 20 (74.07%) FBs passed spontaneously; whereas 07 (25.91%) got

Table 1: Demography, type of foreign bodies, and outcome

	Frequency (%)
Age (years)	
≤20	39 (76.47)
>20	12 (23.52)
Gender	
Female	44 (86.3)
Male	7 (13.7)
Residence	
Rural	29 (60.4)
Urban	22 (39.6)
Foreign body type	
Pin	38 (74.5)
Coin	7 (13.7)
Needle	4 (7.8)
Denture	1 (2.0)
Nail	1 (2.0)
Status	
Found/retrieved	26 (51.0)
Not found/not retrieved	25 (49.0)
Time of ingestion	
Day	30 (58.8)
Night	21 (41.2)

retained in the GI tract, among which 03 pins were recovered from colon [Figure 1], two weeks after ingestion. Another 2 pins had pierced the GI wall where one pin was removed from peritoneum and another from gastrohepatic ligament [Figure 2] and two patients with remaining 2 pins could not be contacted for follow up. On upper GI endoscopy [Table 2], 16 (31.4%) were found in the stomach [Figure 3], 3 (5.9%) in D1, 6 (11.8%) in D2 [Figure 4], and one in the cricopharynx. All the FBs found were retrieved using polypectomy snare, Roth basket, or FB retrieval forceps [Table 3].

Nineteen patients reported within 6 h of ingestion and among them, 16 (84.21%) had FB within the range of retrieval on upper GI endoscopy. Of 32 patients who reported late, only 10 (31.2%) had FB accessible for removal on upper GI endoscopy, and to our surprise, one among these 10 patients had the history of FB ingestion some 3 months back.

Of 38 ingested pins, 20 (52.63%) were retrieved; of seven coins, three were retrieved, whereas four had gone down, and all of them passed out uneventfully. Of four stitching needles, two were retrieved while two had gone down, one got stuck up in small bowel and needed surgery, and another passed up to the anorectum and was retrieved from the rectum.




Figure 1: Pin found in the colon

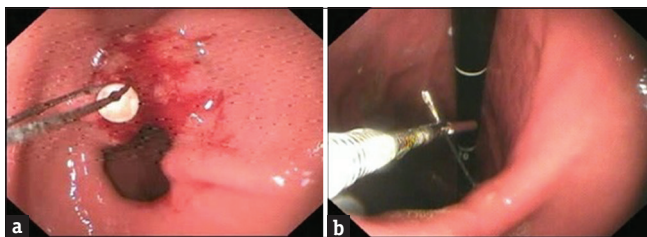


Figure 3: (a) A headed pin pierced in the antrum being removed with snare. (b) Pierced needle at incisura being removed with forceps

Table 2: Location of foreign bodies on upper gastrointestinal endoscopy

Location	Frequency (%)	Valid percent	Cumulative percent
Not located in UGI	25 (49.1)	49.1	49.1
Stomach	16 (31.4)	31.4	80.5
Duodenum	9 (17.6)	13.7	94.2
Cricopharynx	1 (2.0)	2.0	100.0
Total	51 (100.0)	100.0	

UGIT=Upper gastrointestinal tract

Table 3: Status of foreign bodies with respect to time of ingestion and type of foreign bodies

	Status		P
	Found/retrieved (n=26)	Not found/not retrieved (n=25)	
Reporting time after ingestion (h)			
<6	16	3	<0.001
≥6	10	22	
Foreign body type			
Pin	20	18	0.910
Coin	3	4	
Needle	2	2	
Denture	0	1	
Nail	1	0	

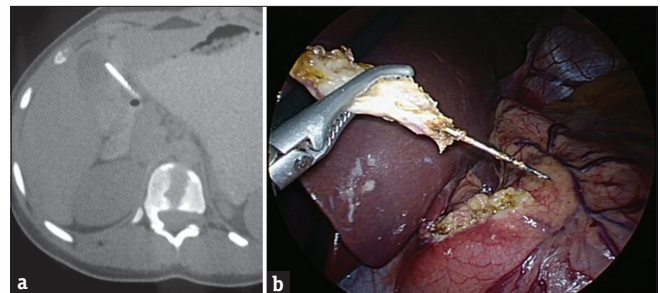


Figure 2: (a) Computed tomography scan showing foreign body (pin) in gastrohepatic ligament. (b) Pin being extracted from the gastrohepatic ligament

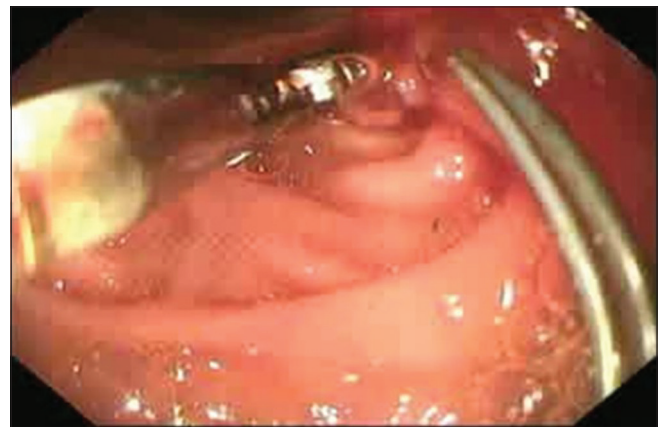


Figure 4: Two pierced pins in the duodenum being removed by the forceps

All patients had accidentally ingested FBs; none had taken them intentionally. Two girls had ingested >1 pin, with one of them having ingested even three pins.

DISCUSSION

Accidental FB ingestion occurs primarily in children and in edentulous or mentally impaired elderly adults. Food bolus impaction at a narrowed part of the esophagus and ingestion of coins in children are by far the most common causes of upper GI intervention for FB removal.^[1] Incidental ingestion of FB occurs in psychiatric patients or prison inmates.^[2,4] Other common FBs include fish and chicken bones, medication packaging, dentures, and coins.^[7] Most FBs (80%) pass without any intervention.^[8,9] Out of those FBs which need removal, 16% may need surgery. It is a trend to remove sharp, long, and wide objects as early as possible. Other FBs which need early removal include large button batteries, high-powered magnets, narcotic packages, and super absorbent objects.^[12]

Other than FB characteristics, structural and functional abnormalities of GI tract may also increase the risk of impaction.^[13-16] These abnormalities include diverticula, webs, rings, strictures, achalasia, tumors, duodenal ulcer sequelae, hernia, and postgastrectomy status.^[17] The type of FB ingested depends on easily available and frequently used objects, that is, why toothbrushes, dentures, nails, coins, and toys are the most common FBs found worldwide. The type of FB also varies from country to country.^[6-11] The pattern must also be changing from time to time as the readily available things also change from time to time and from place to place. Such observations are not published and perhaps not studied. Ingestion of true FBs by normal people with normal GI tract has also not been studied as we did not come across any study which has excluded the people who either have a tendency to ingest FBs or have abnormal GIT anatomy. Our study is also unique in this regard that Kashmir being a disturbed area, it is not easy to reach to a medical facility during night for all individuals, especially those living in remote villages and perhaps this is one of the factors that lead to late reporting by the patients when most of the FBs had crossed the UGIT. The most common FB in this study was pins which are an uncommon finding in other studies.^[18,19] The reason that the pins and needles were common FBs, especially in young girls is clear from the fact that these things are being routinely used by our young girls for tying their head covers and for chain stitching jobs. While tying the head cover, these young girls keep many pins under their teeth and if something untoward happens during this time such as sneezing, coughing, someone else pushing from behind or frightening you, there is every chance that

these pins may either be swallowed or aspirated, example of this is about a young girl who while tying her scarf had three pins under the teeth when her younger sister shame punched her belly and she swallowed all the three pins which fortunately were taken out by endoscopy. The type of head cover has evolved over some time in our community as has been in rest of the world. Some great ladies who are known for their unique head cover included Mother Teresa, Indira Gandhi, Benazir Bhutto, and Sonia Gandhi. In our community, the type of head cover changed markedly in the past few decades, the most primitive one was Kasab (routinely used by our Hindu elderly ladies) which was also loaded with pins, later on it changed to Dhaji which is a simple piece of cloth which is tied at the back of head and hangs over the back of the neck but not covering the face. Dhaji is still being used in our villages and some towns. Many ladies use veil as full body cover which has two types, Arbi Burka and Kashmiri Burqa, none of them needs pins for tying up; however, of late young girls, especially school/college going girls have switched over to Iranian type of Scarf-based head cover which needs multiple safety pins for fixation and hence that it does not slip away. Due to this changing trend of head cover among our female folk, there has been a considerable rise in FB ingestion and thus emergency endoscopies for their removal since past few years and this also justifies the female predominance observed while this study was being conducted.

Timing is very important as far as the management of FBs is concerned. The interval between ingestion of FB and the time patient reaches hospital is really very important as it will decide the success rate of retrieval on UGI endoscopy as we did observe in our study that in those patients who reported early (within 6 h), success rate on UGI endoscopy was much better (84.2%) than those who presented to us beyond 6 h in whom the same was only (31.2%). In this study, the longest interval between ingestion and retrieval was 3 months where in the FB was retrieved from the antrum after it had got impacted over there. Although an early endoscopy is mandatory in sharp and long foreign bodies, a patient who reports late and has a history of ingestion of a sharp foreign body should be subjected to UGI endoscopy because once a foreign body gets impacted at any place in UGI tract, it stays there for months.

Type of FB matters the most, sharp FBs such as pins and needles can cause devastation. If impacted, it can cause aortoesophageal fistula, mediastinitis, pericarditis, cardiac tamponade, recurrent pericardial effusion, and even hemopericardium.^[20-25]

CONCLUSION

After studying the pattern and type of FB ingestion in our community, the following conclusion can be drawn:

- Due a changing trend of covering the head by females of our community, there has been a considerable change and rise in unique FB ingestion in our set up since past few years, in which sharp FBs outnumber the blunt ones
- To get better results, an early endoscopy in these cases is recommended, but even if the patient presents late with the history of FB ingestion, he/she should be subjected to a UGI endoscopy
- An alternate method of fixing the head cover is recommended.

Financial support and sponsorship

Nil.

Conflicts of interest

There are no conflicts of interest.

REFERENCES

1. Lazebnik N, Iellin A, Michowitz M. Spontaneous rupture of the normal stomach after sodium bicarbonate ingestion. *J Clin Gastroenterol* 1986;8:454-6.
2. Webb WA. Management of foreign bodies of the upper gastrointestinal tract: Update. *Gastrointest Endosc* 1995;41:39-51.
3. Henderson CT, Engel J, Schlesinger P. Foreign body ingestion: Review and suggested guidelines for management. *Endoscopy* 1987;19:68-71.
4. Kirk AD, Bowers BA, Moylan JA, Meyers WC. Toothbrush swallowing. *Arch Surg* 1988;123:382-4.
5. Roark GD, Subramanyam K, Patterson M. Ingested foreign material in mentally disturbed patients. *South Med J* 1983;76:1125-7.
6. Proctor MH. Assault by battery. *N Engl J Med* 1987;316:554.
7. Sugawa C, Ono H, Taleb M, Lucas CE. Endoscopic management of foreign bodies in the upper gastrointestinal tract: A review. *World J Gastrointest Endosc* 2014;6:475-81.
8. Ambe P, Weber SA, Schauer M, Knoefel WT. Swallowed foreign bodies in adults. *Dtsch Arztebl Int* 2012;109:869-75.
9. Li ZS, Sun ZX, Zou DW, Xu GM, Wu RP, Liao Z. Endoscopic management of foreign bodies in the upper-GI tract: Experience with 1088 cases in China. *Gastrointest Endosc* 2006;64:485-92.
10. Emara MH, Darwiesh EM, Refaey MM, Galal SM. Endoscopic removal of foreign bodies from the upper gastrointestinal tract: 5-year experience. *Clin Exp Gastroenterol* 2014;7:249-53.
11. Hariga I, Khamassi K, Zribi S, Amor MB, Gamra OB, Mbarek C, *et al.* Management of foreign bodies in the aerodigestive tract. *Indian J Otolaryngol Head Neck Surg* 2014;66:220-4.
12. Wahid FI, Rehman HU, Khan IA. Management of foreign bodies of upper digestive tract. *Indian J Otolaryngol Head Neck Surg* 2014;66:203-6.
13. Schunk JE, Harrison AM, Corneli HM, Nixon GW. Fluoroscopic Foley catheter removal of esophageal foreign bodies in children: Experience with 415 episodes. *Pediatrics* 1994;94:709-14.
14. Ribas Y, Ruiz-Luna D, Garrido M, Bargalló J, Campillo F. Ingested foreign bodies: Do we need a specific approach when treating inmates? *Am Surg* 2014;80:131-7.
15. Wu WT, Chiu CT, Kuo CJ, Lin CJ, Chu YY, Tsou YK, *et al.* Endoscopic management of suspected esophageal foreign body in adults. *Dis Esophagus* 2011;24:131-7.
16. Pellerin D, Fortier-Beaulieu M, Guegun J. The fate of swallowed foreign bodies: Experience of 1250 instances of subdiaphragmatic foreign bodies in children. *Program Pediatr Radiol* 1969;2:302.
17. Carp L. Foreign bodies in the intestine. *Ann Surg* 1927;85:575-91.
18. Sahn B, Mamula P, Ford CA. Review of foreign body ingestion and esophageal food impaction management in adolescents. *J Adolesc Health* 2014;55:260-6.
19. Li ZS, Sun ZX, Zou DW, Xu GM, Wu RP, Liao Z, *et al.* Endoscopic management of foreign bodies in the upper-GI tract: Experience with 1088 cases in China. *Gastrointest Endosc* 2006;64:485-92.
20. Sharland MG, McCaughan BC. Perforation of the esophagus by a fish bone leading to cardiac tamponade. *Ann Thorac Surg* 1993;56:969-71.
21. Quandalle P, Pruvot FR, Latreille JP. Aorto-esophageal fistula secondary to a perforation of the esophagus by a foreign body. *Ann Chir* 1984;38:159-61.
22. Pulatov AT, Kim LE, Rofiev RR. An esophageal foreign body in a child causing the development of an esophago-pericardial fistula and suppurative pericarditis. *Khirurgiia* 1992:100-2.
23. Holder TM. Purulent pericarditis due to perforation of esophagus with foreign body: Bozer AY, Saylam A, Ersoy U. *J Thorac Cardiovasc Surg* 67: 590-592 (April), 1974. *J Pediatr Surg* 1974;9:791.
24. Akdemir R, Gunduz H, Erbilin E, Uyan C. Recurrent pericardial effusion due to retained cardiac pellets: A case report and review of the literature. *Heart Vessels* 2003;18:57-9.
25. Sugunan S, Ajith Krishnan AS, Devakumar VK, Arif AK. Safety-pin induced hemopericardium and cardiac tamponade in an infant. *Indian Pediatr* 2018;55:521-2.