

Review Article

Intraductal Ultrasonography in Pancreatobiliary Diseases

Rinkesh Kumar Bansal, Narendra S. Choudhary, Rajesh Puri, Zubin Sharma, Saurabh Patle, Gaurav Kumar Patil

Institute of Digestive and Hepato-Biliary Sciences, Medanta The Medicity, Gurugram, New Delhi, India

ABSTRACT

Intraductal ultrasonography (IDUS) utilizes probe catheter and operates at a higher frequency (12–30 MHz). It can be passed down the biopsy channel of a side-view endoscope during endoscopic retrograde cholangiopancreatography, and it provides real-time, high-quality imaging of pancreatobiliary ducts and the surrounding structures. IDUS has been used in defining choledocholithiasis, evaluating biliary as well as pancreatic strictures or thickening, and local staging of tumor. We shall discuss the utility of IDUS in the current review.

KEYWORDS: Biliary stricture, endoscopic ultrasound, intraductal ultrasound, pancreatobiliary diseases

INTRODUCTION

Transabdominal ultrasound (US), computed tomography (CT), magnetic resonance imaging (MRI), endoscopic retrograde cholangiopancreatography (ERCP), and endoscopic US (EUS) are various modalities that are used for the evaluation of pancreatobiliary diseases. While US, CT, and MRI are cross-sectional imaging modalities, EUS and ERCP are endoscopic modalities that are also used for tissue diagnosis. The diagnostic yield of ERCP-guided tissue acquisition is suboptimal, which led to the development of ERCP-based newer techniques of evaluation such as peroral cholangioscopy, confocal laser endomicroscopy, and intraductal ultrasonography (IDUS).^[1]

IDUS uses a high-frequency (12–30 MHz) US probe that is passed over a guide wire into the bile and pancreatic ducts during ERCP. IDUS creates images from within the duct lumen and provides real-time and high-quality cross-sectional images of extrahepatic bile duct, pancreatic duct, and the surrounding structures. However, it is not widely used, as most ERCP practitioners are not well trained in EUS.^[2,3] Here, we will discuss indications as well as limitations of IDUS in patients with pancreatobiliary diseases.

INDICATIONS

IDUS is indicated in a number of pancreatobiliary diseases. It is most commonly used in treating biliary tract diseases, differentiating benign and malignant strictures,

and local staging of cholangiocarcinoma (CCA). It can also help to differentiate diseases such as choledocholithiasis from ductal malignancies. IDUS detects local extension of intraductal papillary mucinous neoplasms (IPMNs) and tumor of ampulla of Vater; it also determines the extent of surgical or endoscopic resection.

EVALUATION OF BILIARY DISEASES

IDUS is used in a variety of biliary tract disorders. Indications include evaluation for choledocholithiasis, biliary stricture, and local staging of CCA. IDUS, in comparison to standard EUS, provides better evaluation of proximal biliary system and better delineates the surrounding structures such as portal vein, right hepatic artery, and hepatoduodenal ligaments. It is limited in its accuracy to detect distant structures.

CHOLEDOCHOLITHIASIS

IDUS has been well described in the evaluation of choledocholithiasis. It can visualize small bile duct stones or sludge which is missed on cholangiogram and MRCP. It also differentiates stone from air bubble [Figures 1 and 2]. In a prospective study of 95 patients with suspicious choledocholithiasis, IDUS detected small bile duct stones in 31 patients (32.6%)

Address for correspondence: Dr. Rajesh Puri, Institute of Digestive and Hepato-Biliary Sciences, Medanta The Medicity, Gurugram, New Delhi, India. E-mail: purirajesh70@gmail.com

This is an open access article distributed under the terms of the Creative Commons Attribution-NonCommercial-ShareAlike 3.0 License, which allows others to remix, tweak, and build upon the work non-commercially, as long as the author is credited and the new creations are licensed under the identical terms.

For reprints contact: reprints@medknow.com

How to cite this article: Bansal RK, Choudhary NS, Puri R, Sharma Z, Patle S, Patil GK. Intraductal ultrasonography in pancreatobiliary diseases. *J Dig Endosc* 2017;8:115-8.

Access this article online

Quick Response Code:



Website: www.jdeonline.in

DOI: 10.4103/jde.JDE_83_16

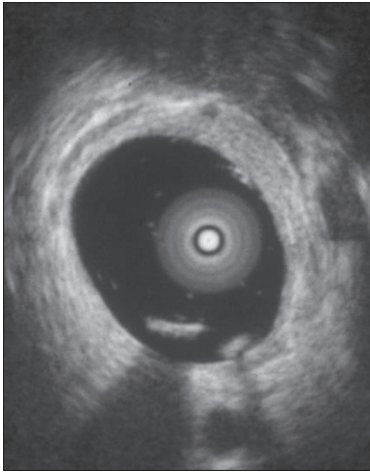


Figure 1: Common bile duct stone seen on intraductal ultrasonography

and sludge in 24 patients (25.2%), which was missed on cholangiography. Endoscopic extraction confirmed bile duct stones in all the 31 patients and sludge in 21 patients.^[4] In a retrospective study of 213 patients with suspected choledocholithiasis, they found that the sensitivity of ERCP in the diagnosis of bile duct stones was significantly affected by the size of stones (100% for stones ≥ 8 mm and 74% for stones < 8 mm) and the diameter of common bile duct (CBD) when the stone size was < 8 mm. The authors thus recommended IDUS in suspicious choledocholithiasis when cholangiogram failed to detect bile duct stones, especially in a dilated CBD (≥ 12 mm in diameter).^[5] IDUS adds cost to the overall management of patients with choledocholithiasis, but its usefulness in suspicious cases, especially where the duct is dilated and cholangiogram is normal, cannot be denied.

IDUS can be performed to confirm bile duct clearance after stone extraction and to detect remnant CBD stones. In a prospective study of seventy patients for detection of residual bile duct stones after stone extraction, IDUS found bile duct stones (mean size: 2.6 mm) in 32 patients with initial normal cholangiography. After stone extraction with negative balloon occlusion cholangiogram, IDUS was able to show residual stones (mean size: 2.2 mm) in 28 (40%) patients, which were all flushed out by saline solution irrigation.^[6]

BILIARY STRICTURES

To differentiate between benign and malignant biliary strictures is always a clinical challenge.^[7] Conventional ERCP-guided tissue acquisition methods have pooled sensitivity of 45% for brush cytology, 48.1% for forceps biopsy, and 59.4% for the combination of both for diagnosing indeterminate biliary strictures (IDBSs).^[8] IDUS improves diagnostic yields significantly. Features

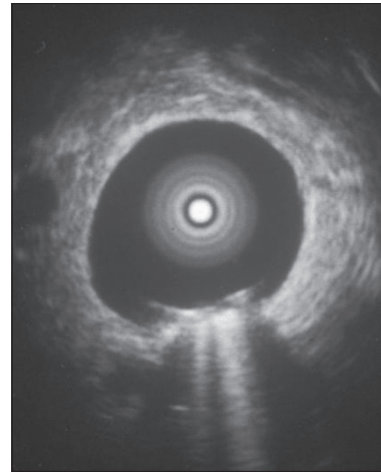


Figure 2: Air bubble in common bile duct seen on intraductal ultrasonography

suggestive of malignancy on IDUS include disruption of normal bile duct wall layers, eccentric wall thickening, hypoechoic mass with signs of adjacent tissue or vascular invasion, and the presence of enlarged lymph nodes.^[9] In a retrospective study of 379 patients, sensitivity, specificity, and accuracy of IDUS, when using histopathology or longterm followup results as the gold standard, were 93.2%, 89.5%, and 91.4%, respectively.^[10]

IDUS is more accurate than EUS, transpapillary biopsy, or brush cytology for the identification of biliary malignancy. Compared to EUS, IDUS has been shown to have greater sensitivity (91% vs. 76%, respectively) and accuracy (89% vs. 76%, respectively) in differentiating a malignant from a benign stricture.^[11]

In a retrospective study of 234 patients with IDBSs, using histological or long-term followup as the gold standard, sensitivity, specificity, and accuracy of 93%, 89%, and 91%, respectively, for IDUS combined with ERCP; 94%, 89%, and 92%, respectively, for IDUS combined with endoscopic transpapillary forceps biopsies (ETP); 71%, 78%, and 74%, respectively, for EUS; and 67%, 82%, and 73%, respectively, for CT. The detection rate of biliary malignancy by combining IDUS with ERCP was superior to ETP, EUS, or CT.^[12] There are no head-to-head trials to compare cholangioscopy and IDUS for the evaluation of biliary strictures. Both have similar accuracies, with IDUS having the advantage of visualizing adjacent structures in proximal CBD and the CBD wall.

CHOLANGIOCARCINOMA

IDUS appeared superior to cholangiography in the evaluation of longitudinal extension of CCA. In a prospective study of 42 patients with borderline resectable hilar CCA, IDUS showed an accuracy of 90%

in the assessment of tumor extension, which was superior to cholangiogram (60%) and CT (66.6%).^[13]

IDUS is more accurate than EUS for T-staging of hilar CCA but has low accuracy in N-staging.^[14] In a prospective study of 56 patients with biliary strictures, IDUS was more accurate than EUS in preoperative T-staging of biliary malignancies (IDUS, 77.7%; EUS, 54.1%, $P < 0.001$), but there was no significant difference in lymph node staging between EUS and IDUS (IDUS, 60%; EUS, 62.5%).^[15] IDUS can help differentiate between primary sclerosing cholangitis (PSC) and IgG4-related cholangitis. Irregular inner margin, diverticulum-like outpouching, and disappearance of three layers are specific IDUS findings for PSC compared to IgG4-SC. IDUS is a more useful procedure than ERC for the early detection of diverticulum-like outpouching.

EVALUATION OF PANCREATIC DISEASES

The most common indication of IDUS in pancreatic diseases is on the detection of extension of IPMN preoperatively and determine the extent of surgical resection.^[16,17] In a prospective study of forty patients with IPMN who underwent surgical resection, IDUS was more accurate than other imaging modalities (85% vs. 50%, respectively, $P = 0.018$) in the preoperative assessment of tumor extension.^[16] In another retrospective study of 24 patients with branch-type IPMN, the lateral spreading of tumor was associated with the dilation of main pancreatic duct (≥ 6 mm) ($P < 0.05$). IDUS showed a sensitivity, specificity, and accuracy of 92%, 91%, and 92%, respectively, in the assessment of tumor extension along the main pancreatic duct.^[17]

EVALUATION OF TUMOR OF AMPULLA OF VATER

IDUS showed excellent diagnostic accuracy for ampullary tumors in detecting intraductal tumor extension and guiding for surgical resection or endoscopic papillectomy. In a study of 48 patients with ampullary tumors before surgical resection or endoscopic papillectomy, there was no significant difference in the accuracy of EUS and IDUS for the evaluation of focal extension of tumors into the ducts (90% and 88%, respectively, for infiltration into the CBD and 92% and 88%, respectively, for extension into the PD). The overall accuracy of EUS and IDUS was 85% and 80% for T-staging, 97% and 94% for adenoma and pTis, 73% and 73% for pT1, 50% and 50% for pT2, and 50% and 100% for pT3-T4.^[18]

Limitations

IDUS has its own limitations. First, cannulation is prerequisite to perform IDUS. Second, IDUS probe can be damaged by cannulation maneuver. Third, it is difficult to maintain the probe in the central position of

the duct, especially in dilated duct. Fourth, air inside the duct hampers image resolution.

CONCLUSION

IDUS is a promising diagnostic tool in the evaluation of pancreatobiliary diseases. It is more sensitive than other conventional methods. By combining IDUS with other techniques, preoperative diagnostic accuracy can be improved significantly. IDUS has been validated in numerous pancreatobiliary diseases and has the potential for growth with further modifications.

Financial support and sponsorship

Nil.

Conflicts of interest

There are no conflicts of interest.

REFERENCES

1. Sun B, Hu B. The role of intraductal ultrasonography in pancreatobiliary diseases. *Endosc Ultrasound* 2016;5:291-9.
2. ASGE Standards of Practice Committee, Chandrasekhara V, Chathadi KV, Acosta RD, Decker GA, Early DS, *et al.* The role of endoscopy in benign pancreatic disease. *Gastrointest Endosc* 2015;82:203-14.
3. Singh A, Gelrud A, Agarwal B. Biliary strictures: Diagnostic considerations and approach. *Gastroenterol Rep (Oxf)* 2015;3:22-31.
4. Kim DC, Moon JH, Choi HJ, Chun AR, Lee YN, Lee MH, *et al.* Usefulness of intraductal ultrasonography in icteric patients with highly suspected choledocholithiasis showing normal endoscopic retrograde cholangiopancreatography. *Dig Dis Sci* 2014;59:1902-8.
5. Endo T, Ito K, Fujita N, Noda Y, Kobayashi G, Obana T, *et al.* Intraductal ultrasonography in the diagnosis of bile duct stones: When and whom? *Dig Endosc* 2011;23:173-5.
6. Ang TL, Teo EK, Fock KM, Lyn Tan JY. Are there roles for intraductal US and saline solution irrigation in ensuring complete clearance of common bile duct stones? *Gastrointest Endosc* 2009;69:1276-81.
7. Chen L, Lu Y, Wu JC, Bie L, Xia L, Gong B, *et al.* Diagnostic utility of endoscopic retrograde cholangiography/Intraductal ultrasound (ERC/IDUS) in distinguishing malignant from benign bile duct obstruction. *Dig Dis Sci* 2016;61:610-7.
8. Navaneethan U, Njei B, Lourdasamy V, Konjeti R, Vargo JJ, Parsi MA, *et al.* Comparative effectiveness of biliary brush cytology and intraductal biopsy for detection of malignant biliary strictures: A systematic review and meta-analysis. *Gastrointest Endosc* 2015;81:168-76.
9. Khashab MA, Fockens P, Al-Haddad MA. Utility of EUS in patients with indeterminate biliary strictures and suspected extrahepatic cholangiocarcinoma (with videos). *Gastrointest Endosc* 2012;76:1024-33.
10. Meister T, Heinzow HS, Woestmeyer C, Lenz P, Menzel J, Kucharzik T, *et al.* Intraductal ultrasound substantiates diagnostics of bile duct strictures of uncertain etiology. *World J Gastroenterol* 2013;19:874-81.
11. Domagk D, Poremba C, Dietl KH, Senninger N, Heinecke A, Domschke W, *et al.* Endoscopic transpapillary biopsies and intraductal ultrasonography in the diagnostics of bile duct strictures: A prospective study. *Gut* 2002;51:240-4.

12. Heinzow HS, Kammerer S, Rammes C, Wessling J, Domagk D, Meister T, *et al.* Comparative analysis of ERCP, IDUS, EUS and CT in predicting malignant bile duct strictures. *World J Gastroenterol* 2014;20:10495-503.
13. Choi ER, Chung YH, Lee JK, Lee KT, Lee KH, Choi DW, *et al.* Preoperative evaluation of the longitudinal extent of borderline resectable hilar cholangiocarcinoma by intraductal ultrasonography. *J Gastroenterol Hepatol* 2011;26:1804-10.
14. American Society for Gastrointestinal Endoscopy (ASGE) Standards of Practice Committee, Anderson MA, Appalaneni V, Ben-Menachem T, Decker GA, Early DS, *et al.* The role of endoscopy in the evaluation and treatment of patients with biliary neoplasia. *Gastrointest Endosc* 2013;77:167-74.
15. Menzel J, Poremba C, Dietl KH, Domschke W. Preoperative diagnosis of bile duct strictures – Comparison of intraductal ultrasonography with conventional endosonography. *Scand J Gastroenterol* 2000;35:77-82.
16. Cheon YK, Cho YD, Jeon SR, Moon JH, Jeong SW, Hur KY, *et al.* Pancreatic resection guided by preoperative intraductal ultrasonography for intraductal papillary mucinous neoplasm. *Am J Gastroenterol* 2010;105:1963-9.
17. Kobayashi G, Fujita N, Noda Y, Ito K, Horaguchi J, Obana T, *et al.* Lateral spread along the main pancreatic duct in branch-duct intraductal papillary-mucinous neoplasms of the pancreas: Usefulness of intraductal ultrasonography for its evaluation. *Dig Endosc* 2011;23:62-8.
18. Okano N, Igarashi Y, Hara S, Takuma K, Kamata I, Kishimoto Y, *et al.* Endosonographic preoperative evaluation for tumors of the ampulla of Vater using endoscopic ultrasonography and intraductal ultrasonography. *Clin Endosc* 2014;47:174-7.