

Macroglossia in neurosurgery

Melissa Brockerville, Lakshmikumar Venkatraghavan, Pirjo Manninen

Abstract

Macroglossia, an abnormal swelling of the tongue, is a rare post-operative complication often associated with serious airway obstruction and prolonged intubations. Currently, there is a paucity of information on the true incidence, aetiology, and complications associated with macroglossia. A thorough review of the literature was carried out so as to summarise the characteristics of reported cases of macroglossia and to present potential treatments and preventive strategies. A literature search was conducted in PubMed to identify human case reports of macroglossia after neurosurgical procedures including spine, published in English from 1974 to December 2015. A total of 26 reports with 36 cases of macroglossia were identified. Macroglossia was most commonly reported after sub-occipital and/or posterior fossa craniotomies and spine surgeries in prone or park-bench positions. It is more common after procedures lasting >8 h. The aetiology of macroglossia is multi-factorial and possible mechanisms included local mechanical tongue compression interfering with venous and/or lymphatic drainage, regional venous thrombosis and/or local trauma. Complications included airway obstruction, re-intubation, difficult re-intubation, prolonged intubation and Intensive Care Unit stay and tongue necrosis. Prevention, awareness of the possibility, and early recognition are the best forms of treatment.

Key words: Macroglossia, neurosurgery, spinal surgery

INTRODUCTION

Macroglossia, an abnormal swelling of the tongue that may occur in the post-operative period, has been associated with many serious consequences such as acute airway obstruction and prolonged intensive care unit (ICU) admissions [Figure 1]. The incidence of macroglossia following neurosurgical procedures is not known. Moore *et al.* reviewed all posterior fossa craniotomies performed at their institution over 6 years and reported an incidence of 1%.^[1] However, this potentially serious complication is likely to be more common.

Department of Anaesthesia, Toronto Western Hospital, University Health Network, University of Toronto, Toronto, Ontario, Canada

Address for correspondence:

Dr. Lakshmikumar Venkatraghavan, Department of Anaesthesia, Toronto Western Hospital, 399 Bathurst Street, Toronto, Ontario M5T 2S8, Canada.
E-mail: lashmi.venkatraghavan@uhn.ca

A review of the literature revealed that there were many case reports of macroglossia following neurosurgery and spine surgery; however, there were no recent complete reviews. Aim of this manuscript was to present a thorough review of the literature to highlight the characteristics of reported cases of macroglossia and to discuss the possible aetiology, potential treatments and preventive strategies as suggested in the available literature.

LITERATURE SEARCH

A literature search was conducted in PubMed to identify human case reports of macroglossia after neurosurgical procedures including spine, published in English from 1974 to December 2015. The keywords used for this search included 'macroglossia', 'angioedema', 'hemimacroglossia', 'oropharyngeal swelling', 'tongue', 'swelling', 'swollen', 'enlargement', 'lingual oedema', 'lingual swelling', 'neurosurgery', 'spine', 'spinal'

This is an open access article distributed under the terms of the Creative Commons Attribution-NonCommercial-ShareAlike 3.0 License, which allows others to remix, tweak, and build upon the work non-commercially, as long as the author is credited and the new creations are licensed under the identical terms.

For reprints contact: reprints@medknow.com

How to cite this article: Brockerville M, Venkatraghavan L, Manninen P. Macroglossia in neurosurgery. *J Neuroanaesthesiol Crit Care* 2017;4:78-84.

Access this article online	
Quick Response Code:	Website: www.jnaccjournal.org
	DOI: 10.4103/jnacc.jnacc_64_16

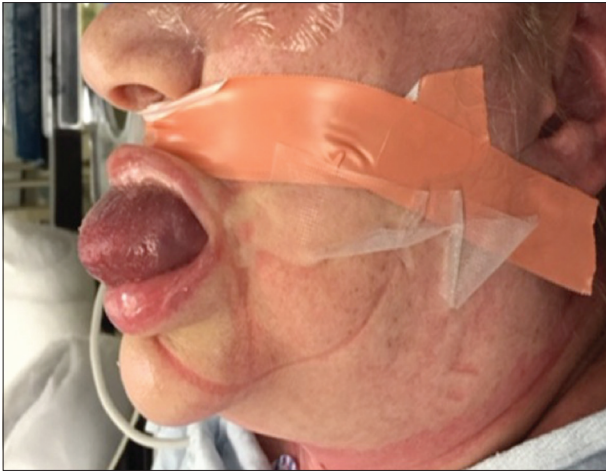

Figure 1: Macroglossia in a neurosurgical patient after spine surgery in prone position (permission obtained from the patient)

‘cervical’, ‘thoracic’, ‘lumbar’, ‘prone’, ‘park-bench’, ‘supine’, and ‘sitting’. Additional articles were identified from the references of the selected literature.

Inclusion criteria

Articles were included if they were case reports that involved macroglossia after neurosurgical procedures in paediatric and adult patients.

Exclusion criteria

Cases were excluded if the surgery was not completed, if swelling also occurred in areas below the neck, if there was a pre-existing congenital macroglossia or if there were multiple surgeries and it was unclear after which surgery the patient developed macroglossia [Table 1] for the list of case reports included in this review.

Table 1: Case reports

Authors	Title
Chowhury et al. ^[8]	Macroglossia in a child undergoing posterior fossa surgery in the sitting position
Carie et al. ^[4]	Postoperative massive tongue edema in craniostomotic children
Denney ^[12]	Postoperative macroglossia causing airway obstruction
Drummond ^[27]	Macroglossia, déjà vu
Ellis et al. ^[3]	Massive swelling of the head and neck
Hassani et al. ^[11]	A reminder for a very rare entity: Massive tongue swelling after posterior fossa surgery
Iwuchukwu et al. ^[13]	Macroglossia associated with brainstem injury
Jakobson et al. ^[32]	Life-threatening macroglossia after trauma
Kawaguchi et al. ^[17]	Pharyngeal packs can cause massive swelling of the tongue after neurosurgical procedures
Koizumi et al. ^[19]	An operation in the park bench position complicated by massive tongue swelling
Kuhnert et al. ^[18]	Postoperative macroglossia: Report of a case with rapid resolution after extubation of the trachea
Krnacik et al. ^[6]	Severe angioedema causing airway obstruction after anterior cervical surgery
Lam et al. ^[5]	Macroglossia: Compartment syndrome of the tongue?
Mayhew et al. ^[9]	Macroglossia in a 16 month-old child after craniotomy
Moore et al. ^[1]	Macroglossia and posterior fossa disease
McAllister ^[25]	Macroglossia - A positional complication
Munshi et al. ^[30]	Postoperative unilateral facial odema: A complication of acute flexion of the neck
Miura et al. ^[7]	Massive tongue swelling as a complication after spinal surgery
Nimjee et al. ^[14]	Tongue swelling and necrosis after brain tumor surgery
Pivalizza et al. ^[24]	Massive macroglossia after posterior fossa surgery in the prone position
Sokhal et al. ^[31]	Postoperative lingual edema is not always a predictor of airway compromise
Sinha et al. ^[2]	Oropharyngeal swelling and macroglossia after cervical spine surgery in the prone position
Tattersall ^[26]	Massive swelling of the face and tongue
Teeple et al. ^[15]	Hemimacroglossia and unilateral ischemic necrosis of the tongue in a long- duration neurosurgical procedure
Toyama et al. ^[16]	Massive macroglossia developing fast and immediately after endotracheal extubation
Tsung et al. ^[23]	Macroglossia after posterior fossa surgery in the prone position - A case report
Vermeersch et al. ^[10]	Life threatening macroglossia after posterior fossa surgery: A surgical positioning problem?

Data collection

Case reports of macroglossia were reviewed for specific surgical and patient characteristics including: Surgical position, surgical procedure, duration of surgery, timing of the development of macroglossia, location and duration of swelling, any required airway interventions (intubation, tracheostomy, cricothyroidotomy) and the intraoperative use of a bite block, oropharyngeal airway or throat pack. The case reports were also reviewed for patient complications, possible aetiologies, treatments, and recommendations for prevention of macroglossia.

CASE REPORTS

A total of 26 reports with 36 cases of macroglossia (29 following neurosurgery and 7 following spinal surgery) met the inclusion criteria and were reviewed. Eight patients were < age 18. Characteristics of the procedures are shown in Figure 2a-c. Fifty per cent of macroglossia cases occurred in procedures lasting longer than 8 h. The most common surgical positions associated with macroglossia were prone (30.6%), park-bench (25.0%) and sitting (19.4%). The most

common procedures associated with macroglossia were sub-occipital and/or posterior fossa craniotomies (38.9%) and spinal surgery (19.4%). Information about the specific surgical procedure was not available for 13 (36.1%) cases. Duration of macroglossia varied, lasting from 24 h to 12 weeks: <7 days in 6 cases (16.7%), ≥7 days in 18 cases (50.0%), and unknown in 12 cases (33.3%).

The timing to the onset of macroglossia after surgery and required airway interventions for acute airway obstruction (intubation and/or surgical airway) is shown in Table 2. The timing of the onset of macroglossia varied from being present before extubation to >24 h after extubation. Information about timing of macroglossia and required airway interventions was not available for 27.8% of patients. Of the 14 cases of macroglossia present at the end of the surgery before extubation, 8 of these patients were not extubated. There was one additional patient who was not extubated after the surgical procedure for planned mechanical ventilation but later developed macroglossia ≥24 h post-operatively and was subsequently not extubated until post-operative day 12. All other patients included in this review were extubated immediately after surgery. In many patients, re-intubation was reported to be difficult after the development of macroglossia and emergency tracheostomies or cricothyroidotomies were required in some patients.^[1-7]

The location of the swelling was pre-dominantly isolated to the tongue in 58.3% (n = 21) of patients. The use of a bite block, oropharyngeal airway and throat pack was reported in 27.8% (n = 10), 5.6% (n = 2) and 16.7% (n = 6) of patients, respectively. One patient had a mouth pack and one patient had gauze packed around the endotracheal tube.

Ten patients required a late tracheostomy. In these patients, the tongue swelling failed to resolve and pressure from the endotracheal tube was thought to be a contributing factor.^[1,4,5,8-13]

In addition to airway obstruction, other complications reported included pain associated with the

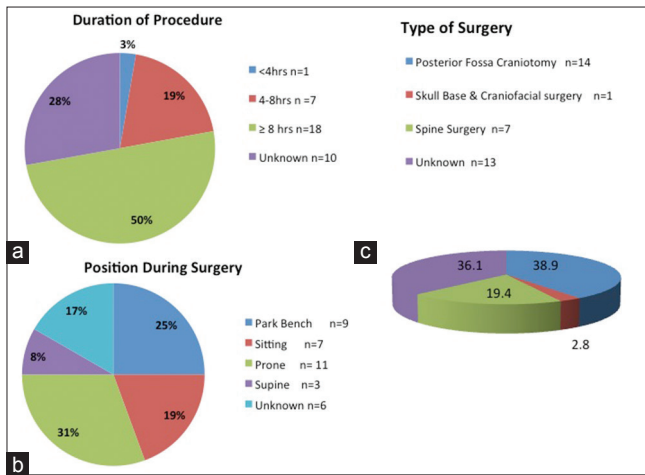


Figure 2: Characteristics of surgical procedures where macroglossia occurred. a) Duration of procedure; (b) position during surgery; (c) type of surgery

Table 2: Onset time to Macroglossia and Incidence of Airway Management

Macroglossia onset time	Number (%) (total n=36)	Re-intubation required	Emergency surgical airways required
Prior to extubation	14 (38.9%)	4	1
≤ 30 mins after extubation	5 (13.9%)	4	1
30 min-8hrs after extubation	4 (11.1%)	3	3
8-24 hrs after extubation	1 (2.8%)	0	0
≥ 24 hrs after extubation	1 (2.8%)	0	0
≥ 24 hrs post-operatively	1 (2.8%)	1	1
Unclear	10 (27.8%)		

macroglossia,^[1,14,15] difficulty with speech and swallowing^[12,14-16] protrusion of the tongue leading to chronic drying and fissuring with superimposed infection,^[12] necrosis,^[5,7,14,15,17] ulceration^[7,18-20] and haematomas of the tongue.^[15] In one case, mechanical dental compression worsened the macroglossia and resulted in a laceration.^[16] Some patients needed surgery (lingual debridement,^[9,14] or partial glossectomy^[17]) as the tongue necrosis was severe. Long-term consequences such as cosmetic disfigurement of the tongue^[14] and chronic dysarthria have also been reported.^[14] There were no reported cases of death directly attributable to post-operative macroglossia.

AETIOLOGY

The exact aetiology of macroglossia was difficult to define and the reports listed many possible causes and contributing factors. These are listed in Table 3. However, there are also other considerations in the differential diagnosis of macroglossia. Angioedema may cause macroglossia; but depending on the aetiology, the skin and mucosa of the extremities, bowel, genitalia, face and throat may also be involved.^[21] Enlargement of the tongue could be related to infections which could occur acutely from bleeding or odontogenic infections spreading into the floor of the mouth.^[22] Excess fluid intake may also be a cofactor for macroglossia; however, the swelling was not be isolated to the tongue.^[7] Patients can have pre-existing or chronic macroglossia from conditions such as Beckwith-Wiedemann syndrome, venous and/or lymphatic malformations, focal tumours, amyloidosis, mucopolysaccharidoses and chronic infection. The tongue can be relatively large if the mandible or maxilla is small, or if there is muscular hypotonia.^[22]

Different patterns in the development of macroglossia, such as mild and severe, have also been described.^[5,23] The mild form is caused by local venous or lymphatic congestion secondary to local compression or venous obstruction. The onset of this macroglossia tends to be immediate. Obstruction of the airway is unlikely because the swelling will be recognised before extubation and the swelling tends to be isolated to the tongue.^[23] The severe form is secondary to a re-perfusion injury. The onset may be delayed and may be more dangerous because it can occur after the patient is extubated. In the severe form, areas other than the tongue may be involved.^[23]

TREATMENT

Various considerations for the treatments were reported in the literature; however, their effectiveness has not been evaluated. In general, patients were placed in the upright position^[2,14] to

Table 3: Etiology of Macroglossia

Etiology	Pathogenesis
Local mechanical compression of the tongue	Objects placed in the mouth may interfere with venous and lymphatic drainage of the tongue and/or arterial inflow leading to ischaemia (see Figure 3 A, B). Pressure related myonecrosis may also occur.
Regional obstruction	Venous and/or lymphatic obstruction may occur in larger veins draining the head and neck (see Figure 3a and b) Obstruction may occur secondary to positioning (neck flexion or head down position) or external compression
Local or regional venous thrombosis	May occur locally in the tongue or in larger vessels draining the tongue. A thrombosis may interfere with the venous drainage of the tongue.
Reperfusion injury	Compression of lingual arteries may occur secondary to venous/lymphatic obstruction or from direct compression of the tongue, when obstruction relieved, reperfusion injury may occur. May explain the delayed onset of macroglossia seen in some patients because it does not occur until the venous congestion is relieved to allow arterial inflow.
Dependant oedema	Dependant oedema may occur in the tongue when in the dependant position for a prolonged period of time secondary to the effects of gravity on venous drainage
Neurogenic origin	Surgical manipulation of the brain stem, which is thought to be intimately involved with autonomic nervous system supply of the tongue, may lead to abnormal brainstem discharges resulting in macroglossia.
Trauma induced	Trauma may occur secondary to intubation, motor evoked potential monitoring, or from a bite injury from seizures.

improve venous drainage. The use of medications included oral steroids (dexamethasone,^[1,4,9,11,13,18,23-25] hydrocortisone,^[23,26] methylprednisolone^[10,16,17] and triamcinolone, unspecified^[6,7,14,19]), and topical and oral analgesics.^[1] However, steroid treatment was reported to be ineffective in some cases.^[9-11] Antibiotics and anti-fungal treatments were used when concomitant infection was suspected.^[14] Additional medications that were used included: sodium succinate,^[10] ranitidine,^[10] aerosols (ipratropium bromide, albuterol sulphate),^[10] tranexamic acid,^[10] promethazine,^[10] cetirizine,^[10]

furosemide^[4] and phenylephrine.^[4] Other treatment modalities included humidified oxygen^[1,18] and wrapping the tongue in wet gauze to prevent desiccation.^[5,18] Some patients required neck exploration,^[5] debridement,^[12] and hemi-glossectomy.^[17] Glossal massage was reported to hasten the resolution of the lymphatic oedema and stimulate the patient to move their tongue, more which may have contributed, to the resolution of macroglossia.^[12] The insertion of single^[4,16,18] or bilateral bite blocks^[1] after the macroglossia has developed has been suggested to relieve pressure on the tongue.

Many patients required a tracheostomy later in their post-operative course^[1,4,5,8-13] to reduce pressure on the tongue from the endotracheal tube.^[10] A nasal endotracheal tube may cause less compression on an already swollen tongue and maybe more comfortable for the patient^[1] though this has not been shown to be the situation in all patients.^[4,18,26]

PREVENTION

Many recommendations on the prevention of macroglossia were reported. An oral airway (such as Guedel) should not be used because it may cause a tongue compression injury,^[2,16,23] especially as most of the pressure from the airway occurs posteriorly in the midline of the tongue and this has a greater effect on the arterial system [Figure 3a and b].^[12] The use of pharyngeal packs^[16] and oral packing^[10] should also be avoided unless required because the airway may be contaminated with blood and/or tissue during the surgery. The use of a soft bite block placed between the teeth has been recommended^[2,16,24,25,27] as this keeps the mouth in a slightly open position and prevents protrusion of the tongue between the upper and lower teeth.^[23] This is important, especially in the lateral, prone, or sitting position, where the tongue may come to rest between the upper and lower teeth.^[27] The bite block can move during patient positioning and should be secured to prevent dislodgement and should again be periodically inspected during the case.^[28] Although

bite blocks are used to prevent injury to the tongue and macroglossia, they can also cause trauma.^[29] The position of the bite block should be inspected to ensure that the tongue and the lips are clear of the teeth and not trapped by the bite block.^[28] 'Overcrowding' of the mouth leading to tongue compression can easily occur with the use of multiple objects in the mouth - (endotracheal tube, oral gastric tube, temperature probe, oesophageal stethoscope), especially in patients with small mouths or with large tongues.^[24] A nasal gastric tube, alternate site for temperature monitoring and precordial stethoscope could be used.^[24] A nasal endotracheal tube intraoperatively may decrease the risk of macroglossia and would be less likely to do further damage if swelling developed.^[1]

If head fixation is with a head holder using a chin bar, the bar that supports the mandible should be checked to ensure that it does not cause soft tissue compression.^[2,25] Extreme flexion of the neck should be avoided^[2,16] as this may prevent venous drainage and compress the airway, endotracheal tube and tracheal rings against the base of the tongue.^[2,23] There should be a distance of a least two finger breadths between the chin and the sternum to avoid this extreme flexion.^[23] After positioning, patients should be checked carefully for signs of obstruction (discoloration in the face, lips and tongue).^[15,23] The hydration status of the patient should also be carefully monitored as hypervolemic states may produce more swelling.^[12]

DISCUSSION

Macroglossia is an uncommon and rare, but potentially dangerous complication following neurosurgery and spinal surgery. In our review of the literature, we found 36 cases of macroglossia following neurosurgical and spine procedures. Macroglossia has been most commonly reported after suboccipital/posterior fossa craniotomies and spine surgeries and after surgeries in the prone, park-bench and sitting positions. Macroglossia most often occurred after procedures lasting >8 h. The aetiology of macroglossia is likely multi-factorial and varies from case to case. Potential aetiologies include local mechanical compression interfering with venous and/or lymphatic drainage and/or arterial inflow, regional venous and/or lymphatic obstruction, local or regional venous thrombosis, reperfusion injury, neurological origin or trauma associated. Complications included airway obstruction, re-intubation, difficult re-intubation, prolonged intubation and ICU stay and tongue necrosis.

In our review of the literature, there was no standardised approach for the treatment of the patient with acute macroglossia. There was no recommendation about how specifically the airway should be managed in a patient

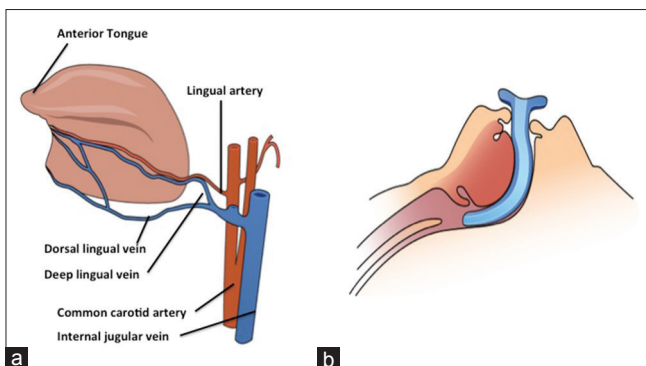


Figure 3: The blood supply of tongue (a) and the effect of oral airway on the tongue vascular supply (b)

Table 4: Summary of Recommendations

Risk factors	Duration of surgery: >8 hrs Type of surgery: Sub-occipital and/or posterior fossa craniotomies and spine surgeries Position: Prone, park-bench, sitting positions
Management	If there is evidence of macroglossia at the end of the case, the patient should not be extubated. If macroglossia develops after extubation, early airway management should be considered. Airway management maybe challenging and a surgical airway maybe needed. Other supportive treatments include head up position, avoidance of further tongue compression, steroids, keeping the tongue moist to prevent desiccation, and analgesics if required.
Prevention	Avoid tongue compression. Place a soft bite block between the teeth to keep the mouth in a slightly open position and to prevent protrusion of the tongue between the upper and lower teeth. Avoid extreme neck flexion. After positioning, patients should be checked carefully for signs of obstruction (discoloration in the face, lips and tongue). Avoid excessive fluid intake.

with macroglossia; however, airway management can be challenging and a surgical airway may be needed. Early recognition and more importantly prevention of macroglossia was suggested as the best way to avoid the potentially serious complications of macroglossia. The many different recommendations suggested are summarised in Table 4.

CONCLUSION

Macroglossia following neurosurgical and spine procedures is not common but when it occurs it can be a devastating complication. All patients who are at risk for macroglossia should be carefully examined for any evidence at the end of the procedure. If a patient has any evidence of macroglossia, the safest approach is to leave the patient's trachea intubated until the swelling subsides. Prevention, awareness of the possibility and early recognition are the best forms of treatment.

Financial support and sponsorship
Nil.

Conflicts of interest

There are no conflicts of interest.

REFERENCES

- Moore JK, Chaudhri S, Moore AP, Easton J. Macroglossia and posterior fossa disease. *Anaesthesia* 1988;43:382-5.
- Sinha A, Agarwal A, Gaur A, Pandey CK. Oropharyngeal swelling and macroglossia after cervical spine surgery in the prone position. *J Neurosurg Anesthesiol* 2001;13:237-9.
- Ellis SC, Bryan-Brown CW, Hyderally H. Massive swelling of the head and neck. *Anesthesiology* 1975;42:102-3.
- Carie CM, White DR, Discolo CM. Postoperative massive tongue edema in craniostomized children. *Int J Pediatr Otorhinolaryngol* 2011;75:1173-5.
- Lam AM, Vavilala MS. Macroglossia: Compartment syndrome of the tongue? *Anesthesiology* 2000;92:1832-5.
- Krnacik MJ, Heggeness MH. Severe angioedema causing airway obstruction after anterior cervical surgery. *Spine (Phila Pa 1976)* 1997;22:2188-90.
- Miura Y, Mimatsu K, Iwata H. Massive tongue swelling as a complication after spinal surgery. *J Spinal Disord* 1996;9:339-41.
- Chowdhury T, Gupta N, Rath GP. Macroglossia in a child undergoing posterior fossa surgery in sitting position. *Saudi J Anaesth* 2012;6:85-6.
- Mayhew JF, Miner M, Katz J. Macroglossia in a 16-month-old child after a craniotomy. *Anesthesiology* 1985;62:683-4.
- Vermeersch G, Menovsky T, De Ridder D, De Bodt M, Saldien V, Van de Heyning P. Life-threatening macroglossia after posterior fossa surgery: A surgical positioning problem? *B-ENT* 2014;10:309-13.
- El Hassani Y, Narata AP, Pereira VM, Schaller C. A reminder for a very rare entity: Massive tongue swelling after posterior fossa surgery. *J Neurol Surg A Cent Eur Neurosurg* 2012;73:171-4.
- Denneny JC 3rd. Postoperative macroglossia causing airway obstruction. *Int J Pediatr Otorhinolaryngol* 1985;9:189-94.
- Iwuchukwu I, Ardelt A, Cueva W, Reshi R, Goldenberg F, Frank J. Macroglossia associated with brainstem injury. *Neurocrit Care* 2014;20:106-10.
- Nimjee SM, Wright DR, Agrawal A, McDonagh DL, Husain AM, Britz GW. Tongue swelling and necrosis after brain tumor surgery. *Asian J Neurosurg* 2012;7:214-6.
- Teeple E, Maroon J, Rueger R. Hemimacroglossia and unilateral ischemic necrosis of the tongue in a long-duration neurosurgical procedure. *Anesthesiology* 1986;64:845-6.
- Toyama S, Hoya K, Matsuoka K, Numai T, Shimoyama M. Massive macroglossia developing fast and immediately after endotracheal extubation. *Acta Anaesthesiol Scand* 2012;56:256-9.
- Kawaguchi M, Sakamoto T, Ohnishi H, Karasawa J. Pharyngeal packs can cause massive swelling of the tongue after neurosurgical procedures. *Anesthesiology* 1995;83:434-5.
- Kuhnert SM, Faust RJ, Berge KH, Piepgras DG. Postoperative macroglossia: Report of a case with rapid resolution after extubation of the trachea. *Anesth Analg* 1999;88:220-3.
- Koizumi H, Utsuki S, Inukai M, Oka H, Osawa S, Fujii K. An operation in the park bench position complicated by massive tongue swelling. *Case Rep Neurol Med* 2012;2012:165860.
- Ishiyama T, Murakami N, Takeda T, Yamamoto M. Macroglossia after neck clipping of a VA-PICA (vertebral artery-posterior inferior cerebellar artery) aneurysm. *Masui* 1990;39:503-7.
- Barbara DW, Ronan KP, Maddox DE, Warner MA. Perioperative angioedema: Background, diagnosis, and management. *J Clin Anesth* 2013;25:335-43.
- Perkins JA. Overview of macroglossia and its treatment. *Curr Opin Otolaryngol Head Neck Surg* 2009;17:460-5.
- Tsung YC, Wu CT, Hsu CH, Yeh CC, Lin SL, Wong CS.

- Macroglossia after posterior fossa surgery in the prone position – A case report. *Acta Anaesthesiol Taiwan* 2006;44:43-6.
24. Pivalizza EG, Katz J, Singh S, Liu W, McGraw-Wall BL. Massive macroglossia after posterior fossa surgery in the prone position. *J Neurosurg Anesthesiol* 1998;10:34-6.
 25. McAllister RG. Macroglossia – A positional complication. *Anesthesiology* 1974;40:199-200.
 26. Tattersall MP. Massive swelling of the face and tongue. A complication of posterior cranial fossa surgery in the sitting position. *Anaesthesia* 1984;39:1015-7.
 27. Drummond JC. Macroglossia, *deja vu*. *Anesth Analg* 1999;89:534-5.
 28. Tamkus A, Rice K. The incidence of bite injuries associated with transcranial motor-evoked potential monitoring. *Anesth Analg* 2012;115:663-7.
 29. Deiner SG, Osborn IP. Prevention of airway injury during spine surgery: Rethinking bite blocks. *J Neurosurg Anesthesiol* 2009;21:68-9.
 30. Munshi CA, Dhamee MS, Gandhi SK. Postoperative unilateral facial oedema: A complication of acute flexion of the neck. *Can Anaesth Soc J* 1984;31:197-9.
 31. Sokhal N, Chowdhury T, Goyal K. Postoperative lingual edema is not always a predictor of airway compromise. *Saudi J Anaesth* 2012;6:79-80.
 32. Jakobson DJ, Einav S, Krichevsky I, Sprung CL, Sela MS. Traumatic macroglossia: A life-threatening complication. *Crit Care Med* 1999;27:1643-5.