

Letter to the Editor

Musculoskeletal chronic graft versus host disease – A rare complication of allogeneic hematopoietic stem cell transplantation: A case report and review of its literature

DOI: 10.4103/sajc.sajc_145_17

Dear Editor,

Chronic graft versus host disease (cGVHD), the most common complication after allogeneic hematopoietic stem cell transplant (Allo-HSCT), is the main contributory factor for morbidity and mortality in transplant patients. Musculoskeletal GVHD is a rare manifestation of cGVHD, with a potential to cause functional impairment, disability, and affect the quality of life. Here, we report a 36 years male, who had chronic skin and musculoskeletal GVHD after 9 months of Allo-HSCT. The patient was successfully treated with steroids. Musculoskeletal chronic GVHD is an extremely rare complication of allogeneic stem cell transplantation. We present a case of musculoskeletal cGVHD and review of its literature.

A 34-year-old male was diagnosed with Philadelphia chromosome-positive chronic myeloid leukemia in chronic phase in November 2014. The patient was started on imatinib 400 mg once a day. He developed bilateral cervical lymphadenopathy, for which he underwent excision of

the cervical lymph node. Histopathological examination revealed T-cell lymphoblastic lymphoma. He received four cycles of chemotherapy regimen of cyclophosphamide, vincristine, Adriamycin, Dexamethasone, cytarabine, and methotrexate and dasatinib. After treatment, he achieved complete molecular remission. Then, he underwent human leukocyte antigen-matched, major ABO mismatch Allo-HSCT on September 2015. In the posttransplant period, he was treated with cyclosporine and short-term methotrexate as GVHD prophylaxis, and cyclosporine was stopped after 6 months. His chimeric studies showed complete donor chimera and his blood group changed to donor type. His breakpoint cluster region-Abelson kinase (BCR-ABL) (real-time quantitative polymerase chain reaction [RQ-PCR]) was normal. However, he developed grade 2 skin and oral chronic GVHD after discontinuation of cyclosporine which was treated with steroids and had good response to it and was tapered. While the steroids were being tapered off, he presented with acute onset weakness of both upper and lower limbs along with swollen, red, and tender muscles. Investigations revealed high creatinine phosphokinase MM (1027 U/L). Neurologist opinion was taken for limb weakness. His bone marrow studies and BCR-ABL (RQ-PCR) were normal. Chimeric studies by variable number tandem repeat also showed donor cells. His viral marker studies including cytomegalovirus and adenovirus

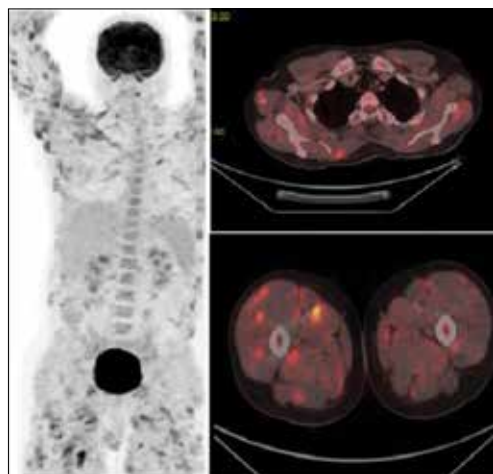


Figure 1: Positron emission tomography-computed tomography showing multiple minimally enhancing lesions in the muscles of body

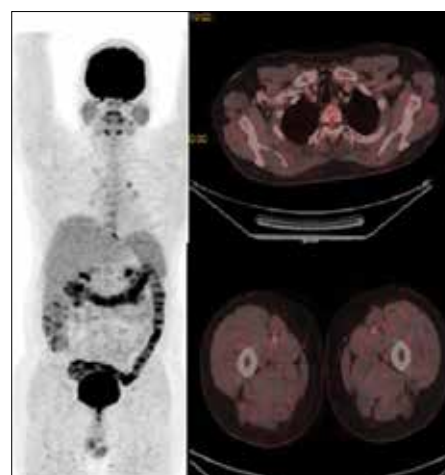


Figure 2: Positron emission tomography-computed tomography scan after 4 months of treatment showing near complete resolution of multiple minimally enhancing lesions in muscles of body (Continue on page 168...)

(Letter to the editor continue from page 150...)

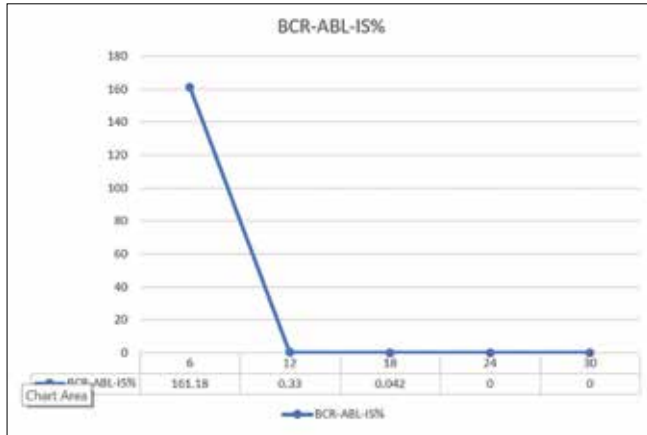


Figure 3: Breakpoint cluster region – Abelson kinase is normalized copy percentage trend from diagnosis, that is, 161.18%–0.00% suggesting complete molecular remissions

were normal. Positron emission tomography-computed tomography (PET-CT) showed multiple minimally enhancing lesions in the muscles of body (maximum standardized uptake value of 5.7) [Figure 1]. He underwent muscle biopsy, which revealed mononuclear infiltrates. After extensive investigations, he was diagnosed with musculoskeletal chronic GVHD and was treated with steroids with good response. His weakness gradually improved and he was discharged. PET-CT scan done after 4 months showed near complete resolution of multiple minimally enhancing lesions in muscles of body (maximum standardized uptake value of 1.72) [Figure 2]. He was on regular follow-up, and his disease is under complete molecular remission with his BCR-ABL IS normalized copy 0.00% which at the time of diagnosis was 161.18% [Figure 3].

Chronic GVHD is an immune-mediated disorder that affects multiple organs and tissues with varying severity. Musculoskeletal complications of chronic GVHD are rare with incidence ranging from 0.54%–0.55% to 2%–3%^[1,2] after Allo-HSCT. These complications are important contributory factor for morbidity; and thus, significantly impair functional status and quality of life of patients with increased risk of mortality.^[3] The pathophysiology of chronic GVHD is incompletely understood. It has been postulated that defective selection of T-cells by damage to the thymus, T-regulatory cell deficiencies, aberrancy in B-cells leading to autoantibody production, and formation of profibrotic lesions are hypothetical theories that emerged from experimental studies.^[4] A biopsy read as “consistent with” or “unequivocal” GVHD will be considered sufficient to support the diagnosis of chronic GVHD if accompanied by at least one distinctive clinical manifestation.^[5] The skeletal muscle biopsy changes have been reported to range from mild perimysial lymphocytic infiltrates to extensive endomysial inflammation with necrosis and regeneration of fibers.^[6] Corticosteroids are the mainstay of treatment for musculoskeletal chronic GVHD. Improvement occurs within days in many cases or may be delayed up to 4–6 weeks.^[7] Our patient has distinct clinical feature of musculoskeletal chronic GVHD supported by histopathology.

He has ocular and oral GVHD. He responded to corticosteroids, and eventually, steroids were tapered, and now his muscular weakness has improved, and the disease is under complete molecular remission.

A musculoskeletal complication of chronic GVHD is extremely rare. Early recognition of these complications is of high importance for appropriate treatment and avoidance of potentially life-threatening events. Our report also highlights the teamwork between hematologists, radiologists, neurologists, neurophysiologists, and physiotherapists, which is important for the better care of musculoskeletal chronic GVHD-related diseases.

Financial support and sponsorship

Nil.

Conflicts of interest

There are no conflicts of interest.

Vasu Babu Goli, Reetu Jain, Ganapathi Bhat, Anjana Sainani, S. H. Advani

Department of Medical Oncology and Bone Marrow Transplant, Jaslok Hospital, Mumbai, Maharashtra, India

Correspondence to: Dr. Vasu Babu Goli, E-mail: vasu2honey@gmail.com

References

1. Oda K, Nakaseko C, Ozawa S, Nishimura M, Saito Y, Yoshida F, *et al.* Fasciitis and myositis: An analysis of muscle-related complications caused by chronic GVHD after allo-SCT. *Bone Marrow Transplant* 2009;43:159-67.
2. Openshaw H. Neurological manifestations of chronic graft versus host disease. In: Vogelsang GB, Pavletic SZ, editors. *Chronic Graft Versus Host Disease*. New York: Cambridge University Press; 2009. p. 243-51.
3. Duell T, van Lint MT, Ljungman P, Tichelli A, Socié G, Apperley JF, *et al.* Health and functional status of long-term survivors of bone marrow transplantation. EBMT working party on late effects and EULEP study group on late effects. *European group for blood and marrow transplantation. Ann Intern Med* 1997;126:184-92.
4. Min CK. The pathophysiology of chronic graft-versus-host disease: The unveiling of an enigma. *Korean J Hematol* 2011;46:80-7.
5. Shulman HM, Kleiner D, Lee SJ, Morton T, Pavletic SZ, Farmer E, *et al.* Histopathologic diagnosis of chronic graft-versus-host disease: National Institutes of Health consensus development project on criteria for clinical trials in chronic graft-versus-host disease: II. Pathology working group report. *Biol Blood Marrow Transplant* 2006;12:31-47.
6. Shulman HM, Sullivan KM, Weiden PL, McDonald GB, Striker GE, Sale GE, *et al.* Chronic graft-versus-host syndrome in man. A long-term clinicopathologic study of 20 Seattle patients. *Am J Med* 1980;69:204-17.
7. Grauer O, Wolff D, Bertz H, Greinix H, Köhl JS, Lawitschka A, *et al.* Neurological manifestations of chronic graft-versus-host disease after allogeneic haematopoietic stem cell transplantation: Report from the Consensus Conference on Clinical Practice in chronic graft-versus-host disease. *Brain* 2010;133:2852-65.

This is an open access article distributed under the terms of the Creative Commons Attribution-NonCommercial-ShareAlike 3.0 License, which allows others to remix, tweak, and build upon the work non-commercially, as long as the author is credited and the new creations are licensed under the identical terms.

How to cite this article: Goli VB, Jain R, Bhat G, Sainani A, Advani SH. Musculoskeletal chronic graft versus host disease – A rare complication of allogeneic hematopoietic stem cell transplantation: A case report and review of its literature. *South Asian J Cancer* 2017;6:150-68.

© 2017 The South Asian Journal of Cancer | Published by Wolters Kluwer - Medknow