

Letter to the Editor

Triple primary malignancies in head-and-neck region: A report of four cases

DOI: 10.4103/sajc.sajc_225_17

Dear Editor,

Patients presented with head and neck malignancy after being treated are in high risk to develop multiple cancers. The frequency of double primary cancers found in an individual has been increasing. However, synchronous or metachronous triple primary cancers have rarely been reported. Meta-analyses show the frequency of second primary tumor as 3%–5%, a third tumor as 0.5%, and a fourth tumor (QT) as 0.3%.^[1,2] A better overall and prolonged survival due to early diagnosis and improved treatment are one of the known possible reasons for rising incidence of multiple primary tumors, and other reason could be the persistent carcinogenic influence on the mucosa, genetic instability, chemoradiotherapy, and prolonged survival after some primary tumors.^[3]

Four patients with triple primary malignancy of head-and-neck region were included in this study. Patients were diagnosed and treated at Max Super Speciality Hospital, Delhi-NCR, having a biopsy-proven first and subsequent primary tumor. A thorough clinical, radiological, and histopathological means were used to exclude a metastasis from first primary tumor. The Warren and Gates criteria have been used to designate a case as multiple primary tumors. The data collected and analyzed with respect to location of primary tumor, histopathology, time elapsed between




Figure 1: First Case : First primary in Buccal Mucosa

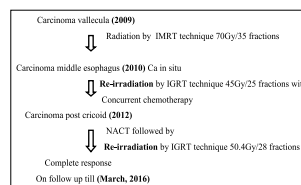


Figure 3: Third Case: First primary in Vallecula

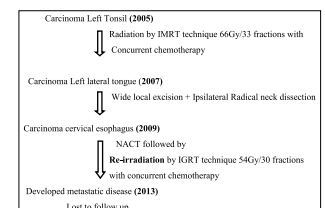


Figure 2: Second Case: First primary in Tonsil

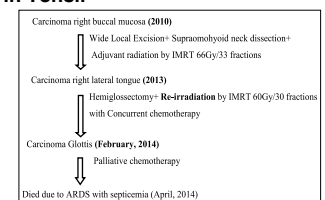


Figure 4: Fourth Case: First primary in Buccal Mucosa

two tumors, treatment received, and the outcome for the all primary tumors [Figures 1-4].

Earlier in this group of patients' palliative systemic chemotherapy was treatment of choice because reirradiation and resurgery were not considered to be feasible. Patients managed with systemic chemotherapy had a median survival of only about 6–8 months, and a cure was unlikely.^[4] Hereby, we are treating our patients with intensity-modulated radiotherapy/image-guided radiotherapy) and concurrent chemotherapy with or without surgery. Two of the four patients were on follow-up 2 and 3 years after the treatment of third malignancies and then lost to follow-up. One patient developed metastatic disease 4 years after the treatment of

third malignancy and one patient died from acute respiratory distress syndrome with septicemia after the treatment of third malignancy.

The management of second and third malignancies remains a challenge but with judicious patient selection and use of appropriate treatment modalities the patients can be successfully treated. We further need an improvement of our knowledge of the risk and pattern of second and subsequent malignancies so that we can offer the best management to our patients.

Financial support and sponsorship

Nil.

Conflicts of interest

There are no conflicts of interest.

Manjari Shah¹, Rashi Agarwal², Sweety Gupta³, Shashank Srinivasan⁴, Prekshi Chaudhary², Sandeep Agarwal⁵, Sudarsan De¹

¹Department of Radiation Oncology, Jaypee Hospital, Noida,

²Department of Radiation Oncology, Max Super Speciality Hospital, Delhi-NCR, ³Department of Radiation Oncology, All India Institute of Medical

Science, Rishikesh, Uttarakhand, ⁴Department of Radiation Oncology, Tata Memorial Hospital, Mumbai, Maharashtra, ⁵Department of Radiation Oncology, Max Super Speciality Hospital, Delhi, India

Correspondence to: Dr. Manjari Shah,
E-mail: manjarishah29@gmail.com

References

1. Bittorf B, Kessler H, Merkel S, Brückl W, Wein A, Ballhausen WG, *et al.* Multiple primary malignancies: An epidemiological and pedigree analysis of 57 patients with at least three tumours. *Eur J Surg Oncol* 2001;27:302-13.
2. National Cancer Institute. SEER Program Code Manual. 3rd ed. Bethesda (MD): National Cancer Institute; 1998.
3. Mehdi I, Shah AH, Moona MS, Verma K, Abussa A, Elramih R, *et al.* Synchronous and metachronous malignant tumours expect the unexpected. *J Pak Med Assoc* 2010;60:905-9.
4. Forastiere AA, Metch B, Schuller DE, Ensley JF, Hutchins LF, Triozzi P, *et al.* Randomized comparison of cisplatin plus fluorouracil and carboplatin plus fluorouracil versus methotrexate in advanced squamous-cell carcinoma of the head and neck: A Southwest Oncology group study. *J Clin Oncol* 1992;10:1245-51.

This is an open access article distributed under the terms of the Creative Commons Attribution-NonCommercial-ShareAlike 3.0 License, which allows others to remix, tweak, and build upon the work non-commercially, as long as the author is credited and the new creations are licensed under the identical terms.

For reprints contact: reprints@medknow.com

How to cite this article: Shah M, Agarwal R, Gupta S, Srinivasan S, Chaudhary P, Agarwal S, *et al.* Triple primary malignancies in head-and-neck region: A report of four cases. *South Asian J Cancer* 2017;6:194-5.