

Case report

Active Herpes Zoster Infection Involving Lumbosacral Dermatome, an Unusual Site of Manifestation and Incidental Finding in Fluorine-18 Fluorodeoxyglucose Positron Emission Tomography/Computed Tomography Scan

Deepa Singh, Rajender Kumar, Gaurav Prakash¹, Anish Bhattacharya, Bhagwant Rai Mittal

Departments of Nuclear Medicine and ¹Internal Medicine, PGIMER, Chandigarh, India

Abstract

Herpes zoster virus reactivation in the lumbosacral dermatomal distribution is an unusual site of manifestation and atypical in presentation than its usual sites in thoracolumbar (D3–L2) and facial (V1) dermatomes. Here, we are reporting a patient of marginal zone lymphoma who on fluorine-18 fluorodeoxyglucose (FDG) positron emission tomography/computed tomography scan performed for chemotherapy response evaluation showed hypermetabolic cutaneous and subcutaneous lesions in the right vulva and posteromedial aspect of the right thigh along with ipsilateral pelvic lymph nodes involvement as an incidental finding. Subsequently, FDG active lesions were considered to be as herpes zoster virus reactivation rather than the recurrence of lymphoma and treated with antiviral drug.

Keywords: Cutaneous lesions, fluorine-18 fluorodeoxyglucose positron emission tomography, herpes zoster virus, lumbosacral dermatome, lymph nodes

Introduction

Herpes zoster is the clinical manifestation of activation and replication of dormant herpes zoster virus in individual with decreased cell-mediated immunity. Although diagnosis is clinical, sometimes may be found incidentally during imaging for any other disease. Here, we are presenting a 45-year-old female patient with the primary diagnosis of marginal zone lymphoma, treated with chemotherapy, and incidentally detected to have herpes zoster virus manifestation

in the lumbosacral dermatome during fluorine-18 fluorodeoxyglucose (¹⁸F-FDG) positron emission tomography/computed tomography (PET/CT) scan, seen as hypermetabolic cutaneous lesions in the right vulval and posteromedial thigh regions with associated ipsilateral lymph nodes involvement.

Case Report

A 45-year-old female patient initially developed complaint of chest pain with hemoptysis, and antitubercular treatment was started empirically. During subsequent

Address for correspondence:

Prof. Bhagwant Rai Mittal, Department of Nuclear Medicine, PGIMER, Chandigarh - 160 012, India.
E-mail: brmittal@yahoo.com

Access this article online

Quick Response Code:



Website:
www.wjnm.org

DOI:
10.4103/wjnm.WJNM_104_16

This is an open access article distributed under the terms of the Creative Commons Attribution-NonCommercial-ShareAlike 3.0 License, which allows others to remix, tweak, and build upon the work non-commercially, as long as the author is credited and the new creations are licensed under the identical terms.

For reprints contact: reprints@medknow.com

How to cite this article: Singh D, Kumar R, Prakash G, Bhattacharya A, Mittal BR. Active herpes zoster infection involving lumbosacral dermatome, an unusual site of manifestation and incidental finding in fluorine-18 fluorodeoxyglucose positron emission tomography/computed tomography scan. World J Nucl Med 2018;17:52-5.

evaluation, right lower lung (RLL) consolidation and right intermediate bronchial stenosis were noted and diagnosed as marginal zone non-Hodgkin lymphoma on biopsy.

She was subjected to ^{18}F -FDG PET/CT scan for staging of primary disease in June 2014. The scan showed FDG avid soft tissue lesion (maximum standardized uptake value [SUVmax] 9.0) in the RLL along with mediastinal, abdominal, and bilateral pelvic lymph nodal involvement. The PET stage was III E.

She was treated with 5 cycles of chemotherapy (rituximab and bendamustine) and an interim PET/CT scan performed in November 2014 showed metabolically active residual disease in the RLL (SUVmax 11.5) and mediastinal lymph nodes. The Deauville score was 4. Thereafter, she received 2 more cycles of chemotherapy. Subsequent PET/CT scan done in July 2015 showed minimal residual disease in RLL (SUV max 2.45) along with metabolically active mediastinal lymph nodes with relatively increased FDG activity as compared to the previous PET, thus suspicious for disease recurrence. However, biopsy from the lymph node was nonreactive. The Deauville score at this time was 2.

In this well-responded disease, PET scan done in January 2016 showed resolution of FDG avidity and a significant decrease in size of the right lung lesion (SUVmax 1.45) along with significant decrease in size and FDG avidity of mediastinal lymph nodes. However, new appearance of FDG avidity in the cutaneous and subcutaneous plane of the right vulva and posteromedial aspect of the right thigh along with the right external iliac and right inguinal lymph nodes were noted as new lesions, thus Deauville score was labeled as X [Figures 1 and 2]. During the examination, she was found to have pain and blisters at the hypermetabolic cutaneous site and clinically diagnosed as herpes zoster virus manifestation. She received tablet valacyclovir 3 times a day, tablet pregabalin once a day orally for 10 day, and responded well. She is under regular follow-up and doing well for the last 11 months.

Discussion

The present case of marginal zone lymphoma was a well-responded disease to chemotherapy in the interim and end chemotherapy FDG PET/CT scan. However, the follow-up PET scan showed FDG avid new lesions at the unusual cutaneous and subcutaneous site in the

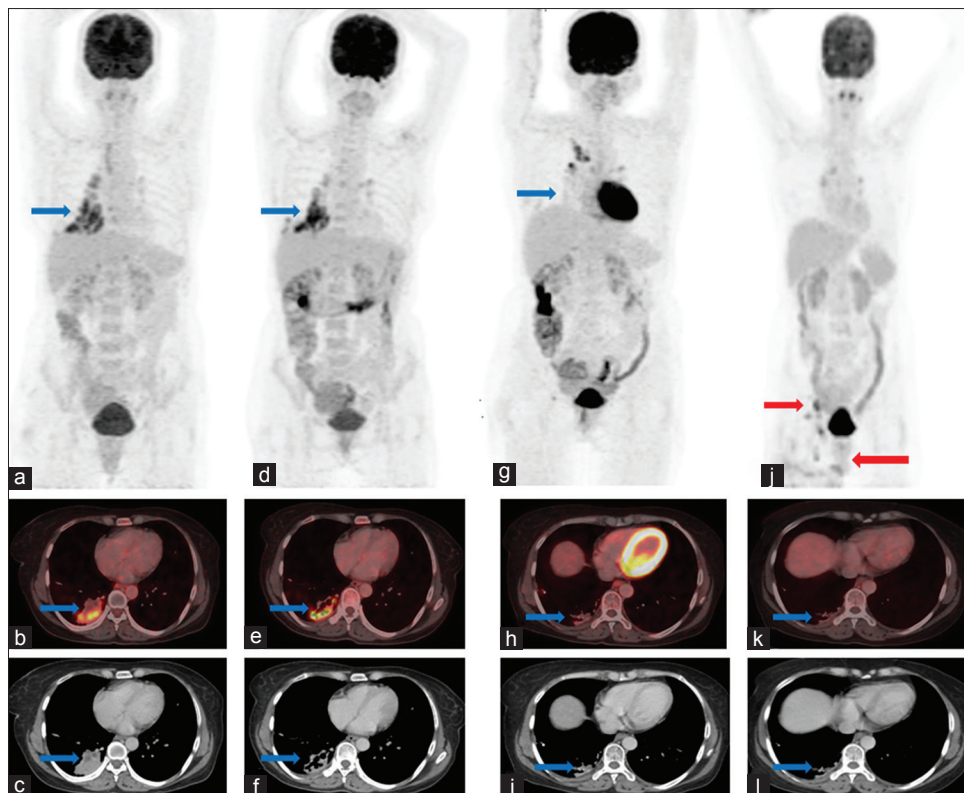


Figure 1: Fluorodeoxyglucose positron emission tomography/computed tomography showing maximum intensity projection, transaxial positron emission tomography/computed tomography, and computed tomography images of thorax: (a-c) Positron emission tomography scan done in June 2014 showing lesions in the right lower lung and mediastinal lymph nodes, (d-f) scan in November 2014 showing residual disease in the right lower lung and mediastinal lymph nodes, (g-i) scan in July 2015 showing minimal residual disease in right lower lung, (j-l) scan in January 2016 showing faintly fluorodeoxyglucose avid mediastinal lymph nodes with resolution of fluorodeoxyglucose avidity of the right lung lesion but appearance of fluorodeoxyglucose avid cutaneous lesion in the right thigh, and right side pelvic lymph nodes as new findings

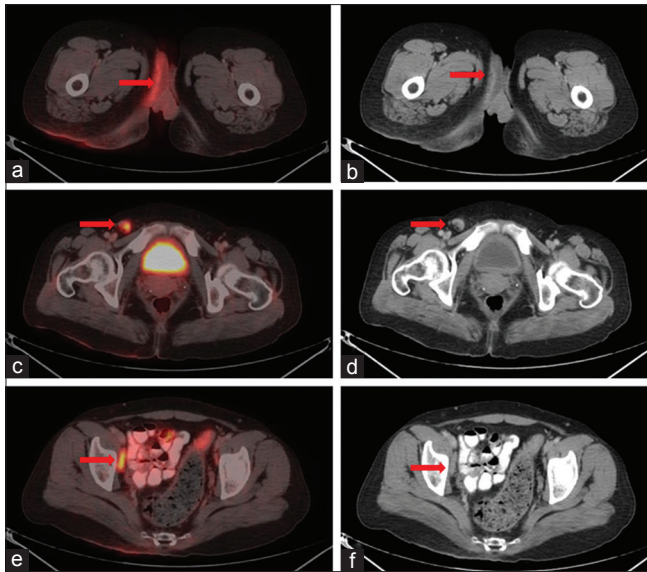


Figure 2: Fluorine-18 fluorodeoxyglucose positron emission tomography/computed tomography scan done in January 2016, showing transaxial images. (a and b) Fused positron emission tomography/computed tomography and computed tomography images showing fluorodeoxyglucose avid cutaneous thickening involving right vulva and posteromedial aspect of right thigh (marked with red arrow), (c and d) fused positron emission tomography/computed tomography and computed tomography images showing fluorodeoxyglucose avid right inguinal lymph node, (e and f) fused positron emission tomography/computed tomography, and computed tomography images showing fluorodeoxyglucose avid right external iliac lymph node

right vulva and posteromedial aspect of the right thigh along with ipsilateral pelvic lymph nodes involvement. As these lesions were not present in any of the previously done PET scan, the Deauville score was rated as X. Although in the first instance, it looked like recurrence of disease, but the characteristic nature of unilateral involvement in a specific dermatome was an interesting feature. During the subsequent clinical evaluation, she was diagnosed to have herpes zoster virus reactivation.

The varicella-zoster virus a neurotropic virus travels centripetally along sensory nerve endings from infected cutaneous and mucosal lesions to dorsal root and cranial nerve ganglia after the resolution of primary varicella infection in childhood and remains in the latent phase. The latent virus reactivates when cell-mediated immunity decreases due to any chronic disease, immune dysregulation, immunosuppressive drug therapy as in malignancy or organ transplantation, trauma, sunburn, stress, or rarely in old age. The newly synthesized varicella-zoster virions transport along the sensory nerve to release into the cutaneous or mucosal sites and manifest as unilateral blisters or vesicular eruption in one or two specific dermatomes in the innervations of involved sensory nerve. This painful rash usually remains for 7–10 days but normal appearance of the skin comes after 2–4 weeks. The most common dermatomes

involved in the disease are thoracolumbar (T3–L2) and facial (V1) dermatomes.^[1,2] Our case is unique due to atypical appearance of cutaneous lesions in the lumbosacral dermatome, an unusual site of presentation and thus difficult in diagnosis.

The ¹⁸F-FDG PET/CT scan is a commonly used investigation to see the metabolic characteristic of disease in malignant patient for primary staging, restaging, and therapy monitoring. However, FDG PET has a limitation in disease characterization during the presence of active infection or inflammatory lesions which also shows high metabolic activity. As in the present case, the active virus infection initially looked like recurrence of disease.

A few previously reported case reports of FDG-PET scan in oncology patients with herpes zoster infection showed either the presence of active cutaneous lesions or hypermetabolic lymph nodes.^[3-7] However, Wadih *et al.*^[8] and Sharma *et al.*^[9] reported the presence of both the active cutaneous manifestation and lymph nodes involvement in the same patient during PET scan.

Both of them reported the presence of cutaneous lesion and lymph nodes in the thoracic dermatome, the usual sites of herpes zoster reactivation. However, the present study showed the unusual site of disease manifestation in the lumbosacral dermatome. As we know that herpes zoster is primarily a clinical diagnosis and gluteal region, medial thigh or perianal mucosa is the common sites of infection. Thus, these areas should not be labeled as genital herpes until unless specific dermatomal distribution along with clinical and/or serological confirmation made.

Conclusion

¹⁸F-FDG PET/CT scan, the routinely used imaging modality in oncology patient may be associated with uptake in active infection and/or inflammatory lesions. A careful scan interpretation by experienced nuclear medicine physician along with proper clinical evaluation of the patient avoids unnecessary or invasive investigations and improper management.

Financial support and sponsorship
Nil.

Conflicts of interest

There are no conflicts of interest.

References

1. Simmons A. Clinical manifestations and treatment considerations of herpes simplex virus infection. *J Infect Dis* 2002;186 Suppl 1:S71-7.

2. Chen TM, George S, Woodruff CA, Hsu S. Clinical manifestations of varicella-zoster virus infection. *Dermatol Clin* 2002;20:267-82.
3. Sheehy N, Israel DA. Acute varicella infection mimics recurrent Hodgkin's disease on F-18 FDG PET/CT. *Clin Nucl Med* 2007;32:820-1.
4. Egan C, Silverman E. Increased FDG uptake along dermatome on PET in a patient with herpes zoster. *Clin Nucl Med* 2013;38:744-5.
5. Joyce JM, Carlos T. Herpes Zoster mimicking recurrence of lymphoma on PET/CT. *Clin Nucl Med* 2006;31:104-5.
6. Muzaffar R, Fesler M, Osman MM. Active shingles infection as detected on (18) F-FDG PET/CT. *Front Oncol* 2013;3:103.
7. Kerrou K, Montravers F, Grahek D, Younsi N, Perniceni T, Godeberge P, *et al.* [18F]-FDG uptake in soft tissue dermatome prior to herpes zoster eruption: An unusual pitfall. *Ann Nucl Med* 2001;15:455-8.
8. Wadih A, Rehm PK, Deng C, Douvas M. Active herpes zoster infection with cutaneous manifestation and adenopathy on FDG PET/CT. *Radiol Case Rep* 2015;10:27-9.
9. Sharma R, Jaimini A, Mondal A, Tripathi M. Pitfall of 18F-FDG-PET imaging in oncology: Herpes zoster with axillary lymphadenopathy. *Hell J Nucl Med* 2008;11:51-2.