

Case Report

Neuroendocrine prostate cancer or prostatitis? An unusual false positive on gallium-68 DOTA-Tyr3-octreotate positron emission tomography/computed tomography in a patient with known metastatic neuroendocrine tumor

ABSTRACT

The importance of gallium-68 DOTA-Tyr3-octreotate (^{68}Ga DOTATATE) positron emission tomography/computed tomography (PET/CT) in the imaging of neuroendocrine tumors (NETs) has grown substantially over the past decade and is becoming markedly more common. We present the case of a male with known metastatic NET who underwent ^{68}Ga DOTATATE PET/CT for restaging, incidentally revealing intense uptake of the prostate with a maximum standard uptake value of 17.4. Due to the patient's medical history, this finding was concerning for neuroendocrine prostate cancer. However, core biopsies of the prostate were negative for malignancy and positive for chronic inflammation. Chronic prostatitis is a very common condition in adult males and is often asymptomatic. Inflammatory conditions, including prostatitis, are important causes of false-positive findings on ^{68}Ga DOTATATE PET/CT and should be considered as part of the differential diagnosis, even in an asymptomatic patient.

Keywords: False positive, gallium-68 DOTA-Tyr3-octreotate, neuroendocrine prostate cancer, neuroendocrine tumor, nuclear medicine, positron emission tomography/computed tomography, prostatitis

INTRODUCTION

Gallium-68 DOTA-Tyr3-octreotate (^{68}Ga DOTATATE) is a radiolabeled somatostatin receptor analog with rising use in positron emission tomography/computed tomography (PET/CT), especially in the imaging of neuroendocrine tumors (NETs). With a sensitivity of 95.1%, many would argue that ^{68}Ga DOTATATE PET/CT is the new gold standard in NET imaging.^[1] We present a case of a unique false positive on a ^{68}Ga DOTATATE PET/CT study in which the prostate showed diffuse, intense avidity. There was initially concern for neuroendocrine prostate cancer (NEPC), but on biopsy, the uptake was found to be due to asymptomatic inflammatory prostatitis (AIP).

CASE REPORT

A 60-year-old male with metastatic NET presented after a surveillance CT showed progression of his disease. He was initially diagnosed with NET 3 years earlier, after presenting

for a small bowel obstruction. Surgical pathology at the time showed a well-differentiated, low-grade NET originating in the small bowel with a Ki-67 of 2%. Imaging was suggestive of metastatic disease with multiple liver lesions and intra-abdominal and peripancreatic lymph nodes, of which one liver lesion and one lymph node were pathologically confirmed to be NET. He was treated with lanreotide, a somatostatin analog in the interim.

MATTHEW Q SCHMIDT, ZACHARY TRENBEATH¹, BENNETT B CHIN¹

Department of Internal Medicine, Saint Joseph Hospital, Denver, ¹Department of Radiology, Division of Nuclear Medicine, University of Colorado School of Medicine, Aurora, Colorado, USA


Address for correspondence: Dr. Bennett B Chin, Department of Radiology, Division of Nuclear Medicine, University of Colorado School of Medicine, Aurora, Colorado, USA. E-mail: bennett.chin@ucdenver.edu

This is an open access journal, and articles are distributed under the terms of the Creative Commons Attribution-NonCommercial-ShareAlike 4.0 License, which allows others to remix, tweak, and build upon the work non-commercially, as long as appropriate credit is given and the new creations are licensed under the identical terms.

For reprints contact: reprints@medknow.com

How to cite this article: Schmidt MQ, Trenbeath Z, Chin BB. Neuroendocrine prostate cancer or prostatitis? An unusual false positive on gallium-68 DOTA-Tyr3-octreotate positron emission tomography/computed tomography in a patient with known metastatic neuroendocrine tumor. World J Nucl Med 2019;18:304-6.

Submission: 01-Feb-19, **Accepted:** 01-Apr-19

Access this article online	
Website: www.wjnm.org	Quick Response Code 
DOI: 10.4103/wjnm.WJNM_11_19	

The patient was followed with surveillance CT scans every 4–6 months. His most recent surveillance CT showed increased size of the major metastatic liver lesion and increased intra-abdominal lymphadenopathy, prompting this presentation. At this time, he had no urinary, bowel, sexual, or pelvic pain complaints that would suggest prostatic disease and was otherwise asymptomatic. Eight months before the current presentation, he was found to have an elevated prostate-specific antigen (PSA) of 4.3 ng/mL, though his PSA had since normalized to 1.42 ng/mL. A ⁶⁸Ga DOTATATE PET/CT was performed to further characterize his disease and assess his candidacy for peptide receptor radionuclide therapy.

⁶⁸Ga DOTATATE PET/CT showed radiotracer avid metastatic disease of the liver, mesentery, and peripancreatic lymph nodes, with a maximum standard uptake value (SUVmax) of 23.9, indicating that the previously identified disease progression was somatostatin receptor positive (Figure 1, Arrow: Metastasis to Liver). Surprisingly, the scan also showed

focal, intense uptake of the prostate with an SUVmax of 17.4 [Figure 2, arrows]. With concern that this could represent NEPC, the patient underwent ultrasound-guided biopsy of the prostate. Twelve core biopsies showed multiple foci of acute and chronic inflammation, no organisms, and no concern for neoplasm. The patient has since begun ¹⁷⁷Lu-DOTATATE therapy for his disease and is doing well 8 months later.

DISCUSSION

Among clinicians, NEPC is of increasing interest. NEPC is a rare group of castrate-resistant cancers with neuroendocrine genetic alterations, most commonly small cell carcinoma. As opposed to prostate adenocarcinoma, NEPC is not driven by testosterone stimulation, rendering NEPC impervious to the standard prostate cancer therapies that target the androgen system. NEPC is much more aggressive than prostate adenocarcinoma, those diagnosed with *de novo* NEPC have a dismal median survival of only 10 months and 5-year overall survival of 12.6%, compared to a 5-year overall survival that approaches 100% for localized prostate adenocarcinoma.^[2-4] Thus, it is of great importance to identify NEPC to initiate the proper treatment algorithms and provide an accurate prognosis for the patient.

Prostatitis is a common condition, as it is estimated that 50% of males will experience symptoms of prostatitis at some point in their lives. The National Institutes of Health divides prostatitis into four categories: acute bacterial prostatitis, chronic bacterial prostatitis, chronic prostatitis/chronic pelvic pain syndrome, and AIP.^[5] AIP is the least understood of these subtypes, although it appears to be relatively common. As the name implies, these patients have no symptoms of prostatitis and are often diagnosed incidentally, usually after an elevated PSA leads to a biopsy for the workup for prostate cancer, or when elevated semen leukocyte levels are discovered during

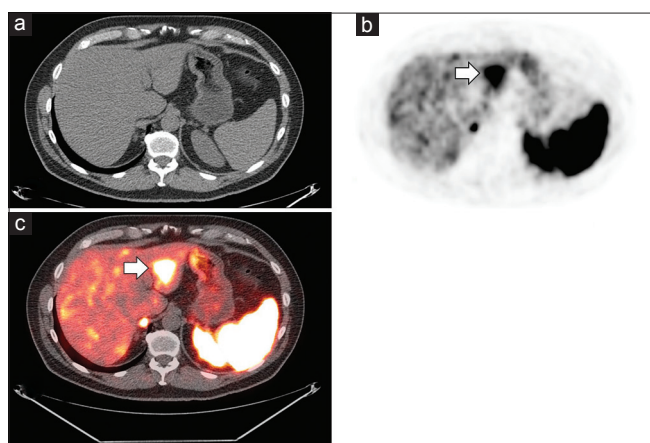


Figure 1: Axial views of the computed tomography (a), positron emission tomography (b), and positron emission tomography/computed tomography fusion (c) demonstrating the largest liver metastasis (arrows) with a maximum standard uptake value of 23.9

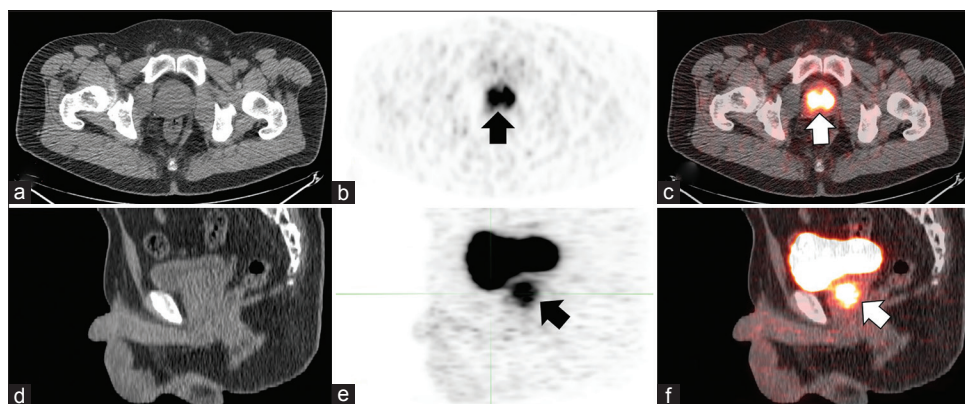


Figure 2: Intense Gallium-68 DOTA-Tyr3-octreotate uptake is seen diffusely throughout the prostate gland (arrows) (maximum standard uptake value = 17.4). (a-c) show the axial views, and panels (d-f) show the sagittal views of the computed tomography, positron emission tomography, and positron emission tomography/computed tomography fusion, respectively

an infertility workup. It is difficult to determine the exact prevalence of AIP since it often goes undetected, although it has been estimated that anywhere between 6.0% and 32.2% of males could show evidence of AIP at a given time.^[6] Our patient is a typical presentation of AIP, as it was not discovered until there was a concern for NEPC.

Active inflammation is known to cause false-positive DOTATATE uptake, which is thought to be due to the high concentration of somatostatin receptors expressed by white blood cells.^[7] The American College of Radiology guidelines on ⁶⁸Ga DOTATATE in NET reports that prostatitis causes physiologic uptake of the radiotracer.^[8] However, actual evidence of this in the literature is scarce. Furthermore, studies have shown that prostate uptake is usually in the range of SUV 3.5–7.^[9,10] Due to the magnitude of the uptake above this threshold with an SUVmax of 17.4, there was a concern initially that this patient had neuroendocrine variant of prostate cancer.

This case demonstrates important teaching points for the increasing number of nuclear medicine physicians who are using ⁶⁸Ga DOTATATE PET/CT. In the event of an unexpected positive finding of prostate uptake, it is critical to know that prostatitis, regardless of symptomatology, can cause false-positive uptake. Thus, the next step in the management should be to reexamine the patient with a particular focus on genitourinary signs and symptoms. The positive uptake of the prostate is much more likely to be due to prostatitis than NEPC simply because of the relative prevalence of the two diseases. However, in this patient with a history of NET, evidence of progression of disease, and radiotracer uptake that was more avid than what would be expected in prostatitis, further workup was deemed appropriate to confirm the extent of his disease before escalating therapy.

Declaration of patient consent

The authors certify that they have obtained all appropriate patient consent forms. In the form the patient(s) has/have given his/her/their consent for his/her/their images and

other clinical information to be reported in the journal. The patients understand that their names and initials will not be published and due efforts will be made to conceal their identity, but anonymity cannot be guaranteed.

Financial support and sponsorship

Nil.

Conflicts of interest

There are no conflicts of interest.

REFERENCES

1. Sadowski SM, Neychev V, Millo C, Shih J, Nilubol N, Herscovitch P, *et al.* Prospective study of ⁶⁸Ga-DOTATATE positron emission tomography/Computed tomography for detecting gastro-entero-pancreatic neuroendocrine tumors and unknown primary sites. *J Clin Oncol* 2016;34:588-96.
2. Zaffuto E, Pompe R, Zanaty M, Bondarenko HD, Leyh-Bannurah SR, Moschini M, *et al.* Contemporary incidence and cancer control outcomes of primary neuroendocrine prostate cancer: A SEER database analysis. *Clin Genitourin Cancer* 2017;15:e793-800.
3. Marcus DM, Goodman M, Jani AB, Osunkoya AO, Rossi PJ. A comprehensive review of incidence and survival in patients with rare histological variants of prostate cancer in the United States from 1973 to 2008. *Prostate Cancer Prostatic Dis* 2012;15:283-8.
4. DeSantis CE, Lin CC, Mariotto AB, Siegel RL, Stein KD, Kramer JL, *et al.* Cancer treatment and survivorship statistics, 2014. *CA Cancer J Clin* 2014;64:252-71.
5. Nickel JC, Nyberg LM, Hennenfent M. Research guidelines for chronic prostatitis: Consensus report from the first national institutes of health international prostatitis collaborative network. *Urology* 1999;54:229-33.
6. Carver BS, Bozeman CB, Williams BJ, Venable DD. The prevalence of men with national institutes of health category IV prostatitis and association with serum prostate specific antigen. *J Urol* 2003;169:589-91.
7. Hofman MS, Lau WF, Hicks RJ. Somatostatin receptor imaging with ⁶⁸Ga DOTATATE PET/CT: Clinical utility, normal patterns, pearls, and pitfalls in interpretation. *Radiographics* 2015;35:500-16.
8. Subramaniam RM, Bradshaw ML, Lewis K, Pinho D, Shah C, Walker RC, *et al.* ACR practice parameter for the performance of gallium-68 DOTATATE PET/CT for neuroendocrine tumors. *Clin Nucl Med* 2018;43:899-908.
9. Moradi F, Jamali M, Barkhodari A, Schneider B, Chin F, Quon A, *et al.* Spectrum of ⁶⁸Ga-DOTA TATE uptake in patients with neuroendocrine tumors. *Clin Nucl Med* 2016;41:e281-7.
10. Shastry M, Kayani I, Wild D, Caplin M, Visvikis D, Gacinovic S, *et al.* Distribution pattern of ⁶⁸Ga-DOTATATE in disease-free patients. *Nucl Med Commun* 2010;31:1025-32.