

## Case Report

# Can radium 223 be a conservative non-surgical management of medication-related osteonecrosis of the jaw?

## ABSTRACT

Osteonecrosis of the jaw (ONJ) is a rare and severe necrotic bone disease reflecting a compromise in the body's osseous healing mechanisms and unique to the craniofacial region. Radium 223 dichloride (Ra223) is the only targeted alpha therapy able to extend survival in patients with bone metastases from prostate cancer. Mechanism of action and data currently available focused mainly on osteoblastic metastases from prostate cancer. In 2018, a Caucasian 54-year-old woman presented to our institution for a breast cancer with bone metastases. Since the patient refused any treatment and taking into account the bone disease, our multidisciplinary team evaluated a supplementary strategy with radium 223. A total of six treatments were planned with a dose of 50 KBq/kg every 4 weeks according to Phase 2 data. Four days after the second cycle administration, the patient presented for examination with a self-extracted necrotic bone fragment. Oroantral communication remained in the absence of algic symptomatology or suppuration. The multidisciplinary approach between oncologists, nuclear physicians, and dental health teams is crucial throughout the treatment process to avoid unnecessary suffering in patients at risk. More prospective studies are needed; however, considering the limitation of the present case, radio 223 may play an adjuvant role in the medical treatment of cancer patients with active ONJ.

**Keywords:** Bone metastases, breast cancer, osteonecrosis of the jaw, radium 223

## INTRODUCTION

Osteonecrosis of the jaw (ONJ) is a rare and severe necrotic bone disease reflecting a compromise in the body's osseous healing mechanisms and unique to the craniofacial region; it is an adverse drug reaction described as the progressive destruction and death of bone that affects the mandible and maxilla of patients exposed to several medications, known to increase the risk of disease, in the absence of a previous radiation treatment. Antiresorptive and antiangiogenic medications have been suggested to be associated with the occurrence of ONJ; yet, the pathophysiology of this disease has not been fully elucidated.<sup>[1]</sup> Among therapies available to manage bone metastases in patients with advanced stages of cancer, radium 223 dichloride (Ra223) (Xofigo injection, Bayer HealthCare Pharmaceuticals Inc.,) is the only targeted alpha therapy approved by health authorities to extend survival.<sup>[2,3]</sup> This drug demonstrated to improve overall survival in a large Phase 3 trial conducted in males with castration-resistant

prostate cancer, symptomatic bone metastases, and no visceral metastases.<sup>[4]</sup> Ra223 is a bone-seeking, alpha-emitting radionuclide which mimics calcium and emits high energy, and the short-range alpha-particles induces double-strand breaks in DNA, with a killing action on the surrounding cells.<sup>[5]</sup> The

**RENATO PATRIZIO COSTA<sup>1</sup>, VINCENZO TRIPOLI<sup>1</sup>,  
ALESSANDRO PRINCIOTTA<sup>1</sup>, ALESSANDRA MURABITO<sup>1</sup>,  
MARIALICARI<sup>1</sup>, RODOLFO MAUCERI<sup>2</sup>, GIUSEPPINA CAMPISI<sup>2</sup>,  
ANTONIO PINTO<sup>3</sup>**

<sup>1</sup>Nuclear Medicine, Biomedical Department of Internal and Specialist Medicine, <sup>2</sup>Clinical Sector of Oral Medicine, Department of Surgical, Oncological and Oral,

<sup>3</sup>Internal Medicine, Biomedical Department of Internal and Specialist Medicine, University of Palermo, Italy


**Address for correspondence:** Dr. Renato Patrizio Costa, Nuclear Medicine, Biomedical Department of Internal and Specialist Medicine, University of Palermo, Via del Vespro, 129 Palermo, Palermo 90127, Italy.  
E-mail: renatopatrizio.costa@gmail.com

This is an open access journal, and articles are distributed under the terms of the Creative Commons Attribution-NonCommercial-ShareAlike 4.0 License, which allows others to remix, tweak, and build upon the work non-commercially, as long as appropriate credit is given and the new creations are licensed under the identical terms.

**For reprints contact:** reprints@medknow.com

**How to cite this article:** Costa RP, Tripoli V, Princiotta A, Murabito A, Licari M, Mauceri R, *et al.* Can radium 223 be a conservative non-surgical management of medication-related osteonecrosis of the jaw?. World J Nucl Med 2019;18:307-9.

**Submission:** 18-Jan-19, **Accepted:** 04-Mar-19

Access this article online	
<b>Website:</b> www.wjnm.org	<b>Quick Response Code</b> 
<b>DOI:</b> 10.4103/wjnm.WJNM_7_19	

decay process of Ra223 is accompanied by gamma emissions; this permits the use of a gamma camera scintigraphy to get quantitative imaging of the radiopharmaceutical with 30–60 min acquisition times.<sup>[6]</sup> Using this technique, important biodistribution studies discovered that the preferential uptake of Ra223 was overlapping with images previously detected by technetium-99 scans, confirming that Ra223 was localized in tissues of bone formation of osteoblastic bone metastases.<sup>[7]</sup> Nowadays, literature data refer effectiveness of Ra223 mainly on tumors with bone osteoblastic activity, such as prostate cancer. Phases 1 and 2 trials documented a clinical efficacy also in breast cancer patients with predominately bone disease, highlighting a reduction in alkaline phosphatase and other bone biomarkers.<sup>[7,8]</sup> Notwithstanding, studies are currently ongoing on tumors associated with mixed osteolytic/osteoblastic lesions.<sup>[9]</sup> To the best of our knowledge, here, we present the first evidence of a possible activity of Ra223 in osteolytic bone metastases arising from a patient with breast cancer.

## CASE REPORT

In 2018, a Caucasian 54-year-old woman presented to our institution of Nuclear Medicine for a breast cancer with bone metastases. She reported fulvestrant therapy and ten cycles of radiotherapy and she also reported the beginning of zoledronate therapy (i.e., zometa) in June 2015, which was suspended in June 2017 due to the appearance of bone exposure, after the dental extraction of the upper right first molar.

The intraoral clinical examination showed an area of exposed necrotic bone, with oroantral communication associated with suppuration and pain. The computed tomography (CT) scan showed how ONJ process involved the entire upper right maxilla, and the ONJ was classified as Stage 3 (SICMF-SIPMO staging system). The patient underwent medical treatment based on the administration of ampicillin and sulbactam (1 g i. m. 2 × daily for 7 days) and metronidazole (250 mg per os 2 × daily for 7 days) as well as the use of antiseptic mouthwashes (chlorhexidine 0.2%, 30 ml swished up to 60 sec, 3 × daily for 7 days). Initial antibiotic therapy for ONJ is an ineffective conservative treatment because ONJ was classified as Stage 3.

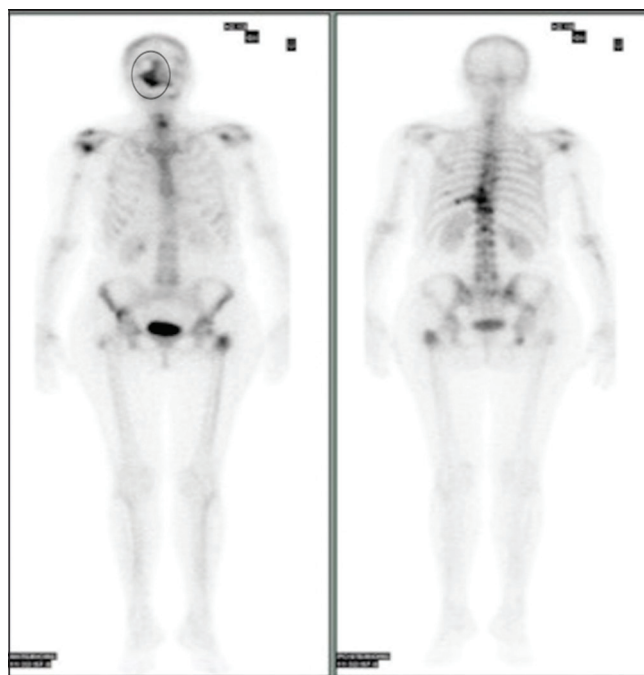
At Stage 3 of the disease, most antibiotic regimens fail without appropriate surgical treatment.

In February 12, 2018, a bone scan with <sup>99m</sup>Tc-methylene diphosphonate confirmed neoplastic bone lesions. The technetium polyphosphate <sup>99m</sup>Tc scan demonstrated increased

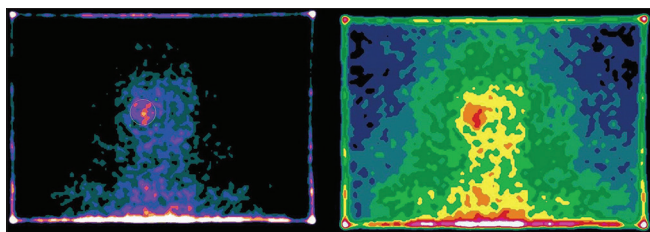
<sup>99m</sup>Tc accumulation in areas of increased blood flow and new bone formation secondary to the infection [Figure 1].

Since the patient refused any treatment and taking into account the bone disease, our multidisciplinary team evaluated a supplementary strategy with a possible bone-targeted agent targeting bone metastasis with Ra223. Additional goal was to select a therapy aiming to maintain the quality of life to avoid a new refuse of the patient for the therapy proposed. Based on Phase 2 clinical data, we decided to propose the off-label use of the radiopharmaceutical Ra223.<sup>[8]</sup> The patient was instructed about the risks (as expected adverse events) and potential benefits of the therapy, the off-label use, as well as required precautions to be taken after Ra223 administration. A complete blood count and chemistry profile ensured that the patient was eligible for Ra223 therapy; subsequently, the agreement on informed consent for the off-label use was obtained. Hospital administration approved the authorization for the off-label use of Ra223 at September 2017. A total of six treatments were planned with a dose of 55 KBq/kg every 4 weeks according to Phase 2 data; the first administration of 3300 KBq of Ra223 was given on March 13, 2018, and a deposit area of radium 223 was detected in ONJ [Figure 2].

On September 29, 2017, CT scan shows evidence of necrosis [Figure 3].



**Figure 1:** On February, 12, 2018, technetium-99m hydroxydiphosphonate shows bone metastases disseminated at the vertebral column, pelvic bones, femur, and humerus levels, finding hypercaptation at the jawbone's dx level as osteonecrosis of the jaw



**Figure 2: Radium 223 planar whole-body scan demonstrated that radium 223 is captured from the jawbone dx**

On May 3, 2018, the patient presented for examination with a self-extracted necrotic bone fragment [Figure 3]. Oroantral communication remained in the absence of algic symptomatology or suppuration.

The weather radium 223 causing to self-bone extraction is about 50 days, after two administrations of Ra223.

## DISCUSSION/CONCLUSIONS

Despite the progress in the prevention of ONJ, a specific evidence-based treatment for the management of ONJ is still missing.

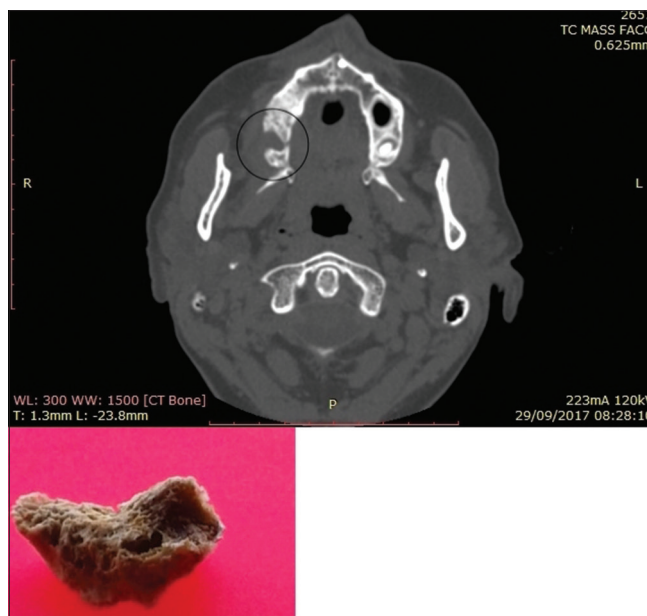
ONJ is a potentially painful and debilitating condition that can considerably affect the quality of life of patients. For these reasons, special attention should be paid to cancer patients in treatment with ONJ-related drug, promoting preventive oral care strategies that have been shown to reduce the risk of ONJ onset.

The multidisciplinary approach between oncologists, nuclear physicians, and dental health teams is crucial throughout the treatment process to avoid unnecessary suffering in patients at risk. Cancer patients, where bone health is already compromised, should be evaluated by a dentist with specific knowledge of ONJs risk factors before starting radio 223. Surgery treatment is the most important treatment for ONJ at Stages 3 and 4; radium 223 may have contributed to the treatment of ONJ as evidenced by the self-bone extraction associated with radium 223 therapy.

Ra223 is able to emit alpha particles in bone tissue, where bone metastases are localized, thanks to its ability to mime calcium. It is detected by osteomyelitis, and it helps identify a sick bone from a healthy bone, as shown in the self-bone extraction. We think that the radiometabolic therapy with Ra223 affects incidental osteomyelitis and the osteonecrosis processes in addition to its analgesic effect as seen by the alleviation of bone pain both at the level of the right jaw and of the known sites of bone metastases.

## Financial support and sponsorship

Nil.



**Figure 3: Computed tomography scan to show evidence of necrosis and self-extracted necrotic bone**

## Conflicts of interest

There are no conflicts of interest.

## REFERENCES

1. Chang J, Hakam AE, McCauley LK. Current understanding of the pathophysiology of osteonecrosis of the jaw. *Curr Osteoporos Rep* 2018;16:584-95.
2. Carroll PR, Parsons JK, Andriole G, Bahnson RR, Castle EP, Catalona WJ, et al. NCCN guidelines insights: Prostate cancer early detection, version 2.2016. *J Natl Compr Canc Netw* 2016;14:509-19.
3. AIOM 2016 – Prostate Cancer Guidelines; 2017. Available from: [http://www.aiom.it/C\\_Common/Download.asp?file=/Site/les/doc/LG/2017\\_LGAIOM\\_Prostata.pdf](http://www.aiom.it/C_Common/Download.asp?file=/Site/les/doc/LG/2017_LGAIOM_Prostata.pdf). [Last accessed on 2018 Dec 10].
4. Parker C, Sartor O. Radium-223 in prostate cancer. *N Engl J Med* 2013;369:1659-60.
5. Carrasquillo JA, O'Donoghue JA, Pandit-Taskar N, Humm JL, Rathkopf DE, Slovin SF, et al. Phase I pharmacokinetic and biodistribution study with escalating doses of <sup>223</sup>Ra-dichloride in men with castration-resistant metastatic prostate cancer. *Eur J Nucl Med Mol Imaging* 2013;40:1384-93.
6. Hindorf C, Chittenden S, Aksnes AK, Parker C, Flux GD. Quantitative imaging of <sup>223</sup>Ra-chloride (Alpharadin) for targeted alpha-emitting radionuclide therapy of bone metastases. *Nucl Med Commun* 2012;33:726-32.
7. Nilsson S, Larsen RH, Fosså SD, Balteskard L, Borch KW, Westlin JE, et al. First clinical experience with alpha-emitting radium-223 in the treatment of skeletal metastases. *Clin Cancer Res* 2005;11:4451-9.
8. Coleman R, Aksnes AK, Naume B, Garcia C, Jerusalem G, Piccart M, et al. A phase IIa, nonrandomized study of radium-223 dichloride in advanced breast cancer patients with bone-dominant disease. *Breast Cancer Res Treat* 2014;145:411-8.
9. Nguyen NC, Shah M, Appleman LJ, Parikh R, Mountz JM. Radium-223 therapy for patients with metastatic castrate-resistant prostate cancer: An update on literature with case presentation. *Int J Mol Imaging* 2016;2016:2568031.