

## Original article

# Synovectomy using Samarium-153 Hydroxyapatite in the Elbows and Ankles of Patients with Hemophilic Arthropathy

José Ulisses Manzzini Calegari, Davi de Podestá Haje, Julian Machado, Mariana Sayago<sup>1</sup>, Danielle Cicarini de Landa

Hospital de Base do Distrito Federal, <sup>1</sup>Hospital de Apoio da Secretaria de Estado, Brasília, DF, Brazil

## Abstract

This study aimed to evaluate synovectomy with samarium-153 hydroxyapatite (<sup>153</sup>Sm-HA) in synovitis of the elbows and ankles of hemophilic patients. The synovectomy was performed using 185 MBq of <sup>153</sup>Sm-HA in 166 joints of 82 hemophilic patients, with a mean age of 24.4 years and follow-up of 12 and 42 months, comprising 63 ankles and 84 elbows. Arthropathy was characterized by recurrent joint bleeding. Episodes of hemarthrosis, use of clotting factors, and pain intensity were evaluated before and after treatment. Scintigraphic controls and adverse effects were also considered. Statistical analyses used  $P \leq 0,005$  as significant. The results pointed that (a) reduction in hemarthrosis was 78% and 68% in elbows and 82% and 72% in ankles; (b) use of clotting factors was 80% and 70% in elbows and 85% and 75% in ankles; (c) pain was 37% and 34% in elbows and 61% and 57% in ankles, after 12 and 42 months, respectively. Three cases of mild reactive synovitis were observed in ankles and four in elbows. There was no joint effusion in any of the cases. In conclusion, the use of <sup>153</sup>Sm-HA in elbows and ankles was effective, very safe, minimally invasive and showed consistency over time, is another material to utilize in median hemophilic joints.

**Keywords:** Hemophilic arthropathy, radioactive synovectomy, samarium-153 hydroxyapatite

## Introduction

Hemophilia is a hereditary disease associated with the X chromosome that predisposes sufferers to bleeding. In Brazil, it is estimated that one in every 20,000 newborns is hemophilic. Genetic changes may be caused by deletions, inversions, or mutations in bridge regions. Since it is associated with the X sex-determining chromosome and is recessive, hemophilia is transmitted by mothers and disease occurs almost exclusively in men.<sup>[1]</sup>

There are two main types of hemophilia, classified according to deficiency: type A, caused by factor VIII

deficiency, and type B, which is rarer and the result of a deficiency in factor IX. These can also be subdivided into degrees in accordance with the plasmatic activity of the clotting factor: mild, function of 5%–25% of normal activity with posttrauma bleeding; moderate, function of 1%–5%; severe, function lower than 1% with spontaneous bleeding. Hemarthroses account for 80% of bleeding in hemophilic patients, with half of these exhibiting deformities and functional joint limitation.<sup>[2]</sup> The joints that are most affected in decreasing order are knees 45%; elbows 30%; ankles 15%; shoulders 3%; wrists 3%; and hips 2%.<sup>[1]</sup>

Repeated joint effusion leads to a local inflammatory response, with the formation of hyperplastic and

### Address for correspondence:

Dr. José Ulisses Manzzini Calegari, Hospital de Base do Distrito Federal, Brasília, DF, Brazil.  
E-mail: jum.calegari@gmail.com

### Access this article online

#### Quick Response Code:



Website:  
[www.wjnm.org](http://www.wjnm.org)

DOI:  
10.4103/wjnm.WJNM\_91\_16

This is an open access article distributed under the terms of the Creative Commons Attribution-NonCommercial-ShareAlike 3.0 License, which allows others to remix, tweak, and build upon the work non-commercially, as long as the author is credited and the new creations are licensed under the identical terms.

For reprints contact: [reprints@medknow.com](mailto:reprints@medknow.com)

**How to cite this article:** Manzzini Calegari JU, de Podestá Haje D, Machado J, Sayago M, de Landa DC. Synovectomy using samarium-153 hydroxyapatite in the elbows and ankles of patients with hemophilic arthropathy. *World J Nucl Med* 2018;17:6-11.

hypertrophic cells and subsequent buildup of hemosiderin. Fibroblasts proliferate and produce collagenases and proteinases that act on the synovium, cartilage, and bone. The buildup of iron leads to chondral destruction which in association with other factors promotes a decrease in the joint space, resulting in bone remodeling. Motion limitation causes muscle atrophy. Acute episodes are usually treated with clotting factor, limb immobilization, and ice, while aspiration is reserved for cases with searing pain and pressure that may result in skin necrosis.<sup>[2]</sup> Another mechanism involved is the damage caused by direct action of red blood cells on the cartilaginous surface of the joint lining.<sup>[3]</sup>

Chemical, radioactive, or surgical synovectomies are useful in the event of synovial hypertrophy, preventing further bleeding. Joint contractures can be managed with traction or immobilization by serial casting. Arthroplasties are considered restorative measures.<sup>[4]</sup>

Radiosynoviorthesis or radiation synovectomy started in 1952 using chromic phosphate (<sup>32</sup>P) as an alternative treatment for rheumatoid arthritis and later villonodular synovitis, ankylosing spondylitis, collagenosis, and psoriatic arthritis.<sup>[5,6]</sup> The use of radioactive material for synovectomy in hemophilia began in 1971.<sup>[7]</sup> Since then, a number of different materials have been used, including chromic phosphate (<sup>32</sup>P), rhenium (<sup>186</sup>Re), yttrium (<sup>90</sup>Y), erbium (<sup>169</sup>Er), dysprosium (<sup>165</sup>Dy), and holmium (<sup>166</sup>Ho), and the procedure is considered safer and less invasive than arthroscopic synovectomy.

We introduced samarium-153 hydroxyapatite (<sup>153</sup>Sm-HA) in the treatment of hemophilic arthropathy.<sup>[8]</sup> The aim of this study was to evaluate the response of hemophilic arthropathy of medium joints - elbows and ankles - to radiation synovectomy with <sup>153</sup>Sm-HA at 12 and 42 months.

## Materials and Methods

This study was approved by the Ethics Committee of the local government Health Department. Patients and their legal guardians were advised of the risks and benefits of the procedure and signed a consent form.

This prospective study was conducted from 2003 to 2009, assessing a total of 82 hemophilic patients subjected to radiosynoviorthesis using <sup>153</sup>Sm associated with hydroxyapatite, including a total of 166 joints, namely 84 elbows (48% affected on the right side and 52% on the left) and 82 ankles (50% for each side). The mean age of patients was 24.4 years (ranging from 5 to 56 years) and follow-up time was 1 year (12 months) and 3.5 years (42 months) after treatment. Patients selected for treatment were those who exhibited chronic synovitis or recurring hemarthrosis (at least once a month) that

did not respond to conventional treatment, including clotting factors, braces, physical therapy, pain killers, and anti-inflammatory agents. Fifty-five patients suffered from hemophilia A (39, severe and 16, moderate) and 27 from hemophilia B (20 severe cases and 7 moderate).

Exclusion criteria were local skin infections and other forms of synovitis. None of the patients showed inhibitors against clotting factors.

Radiographs of the joints were taken, and the Pettersson score<sup>[9]</sup> was established before puncture [Chart 1].

The <sup>153</sup>Sm-HA used was provided by the Institute of Energy and Nuclear Research (IPEN-São Paulo, Brazil), an organization of the National Nuclear Energy Commission. At the IPEN, <sup>153</sup>Sm was combined with hydroxyapatite particles with diameters ranging from 1 to 12 µm and radiochemical purity >95%, over a period of 24 h. Samarium emits beta particles with energies of 808 keV (17.5%), 705 keV (49.6%), and 635 keV (32.2%), allowing maximum penetration into soft tissue of 3.1 mm (average 0.8 mm). It emits gamma radiation of 103.18 keV (30%), enabling its scintigraphic characterization. The stability of the compound used was 96.6%, 1,440 min after processing. The half-life that characterizes decay of the radioactive nuclide <sup>153</sup>Sm is 46.3 h; however, its elimination from the body occurs with a biological half-life of 50.6 days.<sup>[10]</sup>

Before radiosynoviorthesis, a clotting factor was administered to all patients (1–6 h before infiltration). The intra-articular puncture was followed by the administration of 0.5 ml radioactive solution (fixed dose of 185 MBq or 5 mCi). The needle lumen (23-gauge) was then washed using a saline solution, without exceeding the final volume of 2.0 ml. In the presence of clinically evident joint effusion, the joint was punctured using local anesthetic and the radiopharmaceutical was injected through the same route, without further injuries. No immobilization was carried out after the procedure.

Any radioactive material left inside the syringe or on the cotton dressing was measured with a dose

**Chart 1: Pettersson score for radiological assessment**

	Absent	Present	Pronounced
Osteoporosis	0	1	-
Enlarged epiphysis	0	1	-
Irregular subchondral bone	0	1	2
Decreased joint space	0	1 (<50%)	2 (>50%)
Subchondral cyst formation	0	1 (1 cyst)	2 (>1 cyst)
Joint margin erosion	0	1	-
Joint incongruity	0	1	2
Deformities	0	1	2

calibrator. Applications were performed by experienced orthopedists using an aseptic method in a procedure room suited to sterile injections and handling radioactive material.

Images of all the patients were captured 1–2 h and 3–7 days after the procedure using a gamma-camera Millennium GE® with a wide field of vision, low-energy collimator, and the window centered at the 100 KeV photopeak.

Pain level (visual analog scale from 1 to 10), frequency of hemarthrosis, and monthly use of a clotting factor were recorded at all visits before and after the procedure.

The Student’s *t*-test was applied for statistical analysis of qualitative variables (*P* < 0.05).

## Results

Analysis of the Pettersson score showed a mean score of 3.78 for ankles and 5.5 for elbows [Table 1].

In the sample under study, the degree of pain relief as assessed by the visual scale was higher for ankles (71% and 61% improvement after 12 and 42 months, respectively) as compared to elbows (46% and 37% at 12 and 42 months, respectively), and both showed significant improvement in pain following radiosynoviorthesis (*P* < 0.05) [Table 2].

There was a significant reduction of 85% and 74% in the use of the clotting factor in ankles at 12 and 42 months after radiosynoviorthesis and 80% and 70% in elbows for the same periods, despite the fact that some patients also exhibited bleeding and/or synovitis in their knees, which prevented a more thorough assessment of the actual decrease. These data are shown in Table 3.

The decline in hemarthrosis episodes following radiosynoviorthesis with <sup>153</sup>Sm-HA was statistically significant (*P* < 0.05), namely 82% and 72% for ankles and 78% and 68% for elbows after 12 and 42 months, respectively, [Table 4].

No cases of infection (septic arthritis) were observed during the study. Mild clinical symptoms of reactive synovitis occurred in three ankle and four elbow joints.

The scintigraphic controls found no joint effusion in any of the patients, indicating adequate intra-articular distribution of the radioactive material. Counts of the puncture material were found to be consistently slightly above the background radiation.

**Table 1: Assessment of the Pettersson score**

Pettersson score	Ankle, n (%)	Elbow, n (%)
0	15 (18.3)	7 (8.3)
1	9 (11)	4 (4.8)
2	6 (7.3)	2 (2.4)
3	10 (12.2)	7 (8.3)
4	11 (13.4)	9 (10.7)
5	8 (9.7)	14 (16.7)
6	9 (11)	12 (14.3)
7	5 (6.1)	10 (11.9)
8	3 (3.7)	6 (7.1)
9	2 (2.4)	3 (3.6)
10	2 (2.4)	4 (4.8)
11	1 (1.2)	3 (3.6)
12	0	2 (2.4)
13	1 (1.2)	1 (1.2)
Mean	3.78	5.5

**Table 2: Pain reduction following radiosynoviorthesis with samarium-153 hydroxyapatite (scale from 1 to 10)**

Joint	1 year later	3.5 years later (P)
Ankles, %	71	61 (<0.05)
Elbows, %	46	37 (<0.05)

**Table 3: Reduction in the use of the clotting factor after treatment with samarium-153 hydroxyapatite**

Joint	1 year later	3.5 years later (P)
Ankles, %	85	74 (<0.05)
Elbows, %	80	70 (<0.05)

**Table 4: Reduction in the number of hemarthrosis episodes after treatment with <sup>153</sup>Sm-hydroxyapatite**

Joint	1 year later	3.5 years later (P)
Ankles, %	82	72 (<0.05)
Elbows, %	78	68 (<0.05)

## Discussion

In primary prophylaxis, initiated before or shortly after the first hemorrhagic episode, patients are regularly given a sufficient dose of a specific clotting factor concentrate every 3 days, which is maintained above 1% to prevent spontaneous hemarthrosis and the emergence of a “target joint.”<sup>[11]</sup>

The aim of secondary prophylaxis is to prevent additional damage to the previously hemorrhaging joint<sup>[4]</sup> and involve administering a specific clotting factor concentrate on a daily basis or every 3 days until the joint returns to its normal state. However, when a patient has experience repeated hemarthrosis and chronic synovitis, the prophylactic use of a clotting factor does not provide the expected results.

Of the hemophilic patients with synovitis, only 40% achieved adequate control of hemarthrosis through a carefully supervised prophylactic clotting factor protocol, even with the use of higher doses than those recommended for primary prophylaxis during a 9-month follow-up period.<sup>[12]</sup> In addition to the limited therapeutic benefit, other drawbacks of this treatment include its high cost and the inherent risks of prolonged exposure to plasma products, especially if viral inactivation is not performed. With respect to chronic synovitis, this study demonstrated that radiosynoviorthesis can be considered an important method for inhibiting further bleeds and the likely worsening of arthropathy.

Surgical excision of a hypertrophied synovial membrane can be performed through open or arthroscopic interventions and in our view should be used after failed radiosynoviorthesis when synovectomy is still recommended.

In chemical synoviorthesis, substances with fibrosing ability are used for the synovial membrane, such as the broad-spectrum antibiotics rifampicin or oxytetracycline hydrochloride. We opted to use radioactive substances rather than antibiotics in our study due to their higher effectiveness as previously confirmed. Chemical synoviorthesis with antibiotics is a low-cost procedure but is usually painful, and several weekly interventions are needed to obtain satisfactory results.<sup>[13,14]</sup>

Radiation synovectomy and/or radiosynoviorthesis are terms commonly used to describe the synovial fibrosis achieved by an intra-articular injection of radioisotopes. Although multiple isotopes are used for this purpose, the ideal isotope should have a suitable half-life and limited range of beta emission. Thus, the effect is concentrated in the synovial membrane, preventing the risk of radiation to surrounding tissues with potential degradation of the joint cartilage and early progression to arthrosis.<sup>[15]</sup> Chromic phosphate <sup>32</sup>P is most used in the United States and Canada,<sup>[6]</sup> while in Europe and Latin America, including Brazil, yttrium Y 90 and <sup>153</sup>Sm-HA are preferred.<sup>[4,16,17]</sup>

There are several advantages to using <sup>153</sup>Sm in association with hydroxyapatite. The first is that the substance is produced in Brazil, reducing costs and providing a certain degree of independence from imported raw materials. Moreover, the emission of low-energy gamma rays allows for the scintigraphic monitoring of its biological distribution, radioactive half-life, and low-energy beta emission, resulting in a material that is not aggressive to the extra-articular tissue (low penetration). The use of yttrium on joints with thinner cartilage lining, such as the elbow (average thickness of

2 mm), may result in a chondral lesion since penetration is deeper than that of samarium.<sup>[18-20]</sup>

In regard to joint effusion, there is an inverse relationship with particle size. Binding samarium to hydroxyapatite to produce <sup>153</sup>Sm-HA results in particles that are suitably sized for incorporation by the existing macrophages in the inflamed synovium, with less possibility of joint effusion, making the compound safer to use. The <sup>153</sup>Sm-HA bond is highly stable, and on dissociation, samarium is found in the trivalent form, resulting in the formation of insoluble compounds with synovial fluid elements, precipitating in the joint. These properties differentiate samarium from other materials due to its higher deposition on the joint and lower systemic circulation.<sup>[21]</sup> In this study, scintigraphy performed 1-2 h and 3-7 days later revealed no leakage, as well as homogeneous distribution on the joint [Figure 1].

After almost 40 years using radiosynoviorthesis, no damage has been reported in terms of radioactive materials.<sup>[14]</sup> A major concern regarding radiosynoviorthesis is the risk of carcinogenesis; however, analysis of chromosomal aberrations has yet to confirmed this hypothesis.<sup>[22,23]</sup>

There was a significant decrease in the amount of the clotting factor used, which was similar to previously published studies, showing an improvement by 76%-80%.<sup>[4,16,24-26]</sup> This aspect has an economic impact because the cost of blood products is still high.

Assessment of the Pettersson score showed a mean score of 3.78 and for ankles and 5.5 for elbows, demonstrating that hemophilic arthropathy was more advanced in elbows than in ankles, explaining the higher level of pain. Decreased pain following radiosynoviorthesis with <sup>153</sup>Sm-HA, assessed using a visual scale (1-10), was shown to be higher in ankles when compared to elbows.

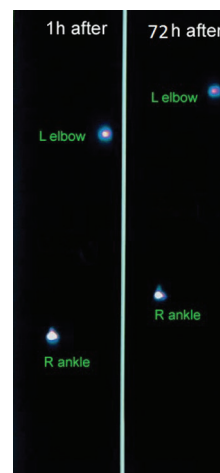


Figure 1: Scintigraphic evaluation showing no scape from joints

One explanation is the fact that the elbows exhibited more advanced degrees of hemophilic arthropathy: the procedure treats synovitis and not the existing joint lesion.<sup>[27]</sup>

Adverse reactions were limited and mild in intensity, occurring in three ankles and four elbows. There was no need for the systematic use of simultaneously injected corticosteroids to reduce reactive synovitis as reported in the literature. This study is one of the few that evaluates only the therapeutic effect of the intra-articular radioactive material. This is because its administration in association with corticosteroids creates bias in result analysis since these are also used with the same purpose in hemophilic arthropathy therapy.<sup>[28,29]</sup> This association has previously been called into question<sup>[30]</sup> and was therefore not used here;<sup>[8]</sup> in addition, there was no information in the literature characterizing the nature of its effect, whether competitive, addictive, or synergic.

## Conclusion

The use of <sup>153</sup>Sm-HA for the treatment of hemophilic arthropathy in elbows and ankles was a safe, cost-effective, minimally invasive, and effective procedure in controlling bleeding and pain. The results of this study corroborate those reported in the literature, demonstrating the benefits of radiosynoviorthesis with <sup>153</sup>Sm-HA and consistency over time.

## Financial support and sponsorship

Nil.

## Conflicts of interest

There are no conflicts of interest.

## References

- Antunes SV. Hereditary Bleeding Disorders. In: Borges DR, Rothschild HA, editors. Therapeutic Actualization. 21<sup>st</sup> ed. São Paulo:Artes Mécicas;2003.p. 788-97.
- Rodríguez-Merchán EC. Pathogenesis, early diagnosis, and prophylaxis for chronic hemophilic synovitis. Clin Orthop Relat Res 1997;343:6-11.
- Jansen NW, Roosendaal G, Bijlsma JW, DeGroot J, Theobald M, Lafeber FP. Degenerated and healthy cartilage are equally vulnerable to blood-induced damage. Ann Rheum Dis 2008;67:1468-73.
- Manco-Johnson MJ, Nuss R, Geraghty S, Funk S, Kilcoyne R. Results of secondary prophylaxis in children with severe hemophilia. Am J Hematol 1994;47:113-7.
- Schneider P, Farahati J, Reiners C. Radiosynovectomy in rheumatology, orthopedics, and hemophilia. J Nucl Med 2005;46 Suppl 1:48S-54S.
- Silva M, Luck JV, Llinas A. Chronic hemophilic synovitis: The role of radiosynovectomy. Treatment of hemophilia monograph series, no. 33. Montréal, Canada: World Federation of Hemophilia; 2004.
- Ahlberg A. Radioactive gold in the treatment of chronic synovial effusion in hemophilia. In: Ana F, Denson R, editors. Hemophilia. Proceedings of VII Congress World Federation of Hemophilia. Amsterdam, Holland: Teherat Excerpta Medica; 1971. p. 212-5.
- Calegario JU, Machado J, DE Paula JC, DE Almeida JS, Casulari LA. Clinical evaluation after 1 year of 153-samarium hydroxyapatite synovectomy in patients with haemophilic arthropathy. Haemophilia 2009;15:240-6.
- Pettersson H, Ahlberg A, Nilsson IM. A radiologic classification of hemophilic arthropathy. Clin Orthop Relat Res 1980;149:153-9.
- Barboza MF, Casiglia MT, Souza AA, Herrerias R, Bambalas E, Santos C, et al. 153Sm-HA: Radiopharmaceutical agent for synovectomy. Q J Nucl Med Mol Imaging 2006;50 Suppl 1:46-47.
- Nilsson IM, Berntorp E, Löfqvist T, Pettersson H. Twenty-five years' experience of prophylactic treatment in severe haemophilia A and B. J Intern Med 1992;232:25-32.
- Greene WB, McMillan CW, Warren MW. Prophylactic transfusion for hypertrophic synovitis in children with hemophilia. Clin Orthop Relat Res 1997;343:19-24.
- Caviglia HA, Fernández-Palazzi F, Maffei E, Galatro G, Barrionuevo A. Chemical synoviorthesis for hemophilic synovitis. Clin Orthop Relat Res 1997;343:30-6.
- Rodríguez-Merchan EC, Wiedel JD. General principles and indications of synoviorthesis (medical synovectomy) in haemophilia. Haemophilia 2001;7 Suppl 2:6-10.
- Erken EH. Radiocolloids in the management of hemophilic arthropathy in children and adolescents. Clin Orthop Relat Res 1991;264:129-35.
- Fernandez-Palazzi F, Rivas S, Cibeira JL, Dib O, Viso R. Radioactive synoviorthesis in hemophilic hemarthrosis: Materials, techniques, and dangers. Clin Orthop Relat Res 1996;328:37-41.
- Pusuwan P, Asavatanabodee P, Chaudakshetrin P, Chatiamnuay P, Intarasupht T. Efficacy of radiopharmaceutical synovectomy with samarium-153-particulate hydroxyapatite in chronic refractory synovitis. World J Nucl Med 2002;1 Suppl 1:S241-52.
- Clunie G, Lui D, Cullum I, Ell PJ, Edwards JC. Clinical outcome after one year following samarium-153 particulate hydroxyapatite radiation synovectomy. Scand J Rheumatol 1996;25:360-6.
- O'Duffy EK, Clunie GP, Lui D, Edwards JC, Ell PJ. Double blind glucocorticoid controlled trial of samarium-153 particulate hydroxyapatite radiation synovectomy for chronic knee synovitis. Ann Rheum Dis 1999;58:554-8.
- Heim M, Tiktinsky R, Amit Y, Martinowitz U. Yttrium synoviorthesis of the elbow joints in persons with haemophilia. Haemophilia 2004;10:590-2.
- Chinol M, Vallabhajosula S, Goldsmith SJ, Klein MJ, Deutsch KF, Chinen LK, et al. Chemistry and biological behavior of samarium-153 and rhenium-186-labeled hydroxyapatite particles: Potential radiopharmaceuticals for radiation synovectomy. J Nucl Med 1993;34:1536-42.
- Falcón de Vargas A, Fernandez-Palazzi F. Cytogenetic studies in patients with hemophilic hemarthrosis treated by 198Au, 186Rh, and 90Y radioactive synoviorthesis. J Pediatr Orthop B 2000;9:52-4.
- O'Duffy EK, Oliver FJ, Chatters SJ, Walker H, Lloyd DC, Edwards JC, et al. Chromosomal analysis of peripheral lymphocytes of patients before and after radiation synovectomy with samarium-153 particulate hydroxyapatite. Rheumatology (Oxford) 1999;38:316-20.
- Luck JV Jr., Silva M, Rodríguez-Merchan EC, Ghalambor N, Zehri CA, Finn RS. Hemophilic arthropathy. J Am Acad Orthop Surg 2004;12:234-45.

25. Ofluoglu S, Schwameis E, Zehetgruber H, Havlik E, Wanivenhaus A, Schweeger I, *et al.* Radiation synovectomy with (166) Ho-ferric hydroxide: A first experience. *J Nucl Med* 2002;43:1489-94.
26. van der Zant FM, Jahangier ZN, Moolenburgh JD, van der Zee W, Boer RO, Jacobs JW. Radiation synovectomy of the ankle with 75 MBq colloidal 186rhenium-sulfide: Effect, leakage, and radiation considerations. *J Rheumatol* 2004;31:896-901.
27. Rodriguez-Merchan EC. Musculoskeletal complications of hemophilia. *Haemophilia* 2010;6:37-42.
28. Shupak R, Teitel J, Garvey MB, Freedman J. Intra-articular methylprednisolone therapy in hemophilic arthropathy. *Am J Hematol* 1988;23:26-9.
29. Fernández-Palazzi F, Caviglia HA, Salazar JR, López J, Aoun R. Intraarticular dexamethasone in advanced chronic synovitis in hemophilia. *Clin Orthop Relat Res* 1997;343:25-9.
30. Gedik GK, Ugur O, Atilla B, Dündar S. Is corticosteroid coinjection necessary for radiosynoviorthesis of patients with hemophilia? *Clin Nucl Med* 2004;29:538-41.