

Case Report

Bone scintigraphy imaging of cardiac amyloidosis

ABSTRACT

Transthyretin-related cardiac amyloidosis (ATTR) amyloidosis is an aggressive, rapidly progressive, and fatal disease, for which several promising therapies are in development. This condition is frequently underdiagnosed because of the limited specificity of echocardiography and the traditional requirement for histological diagnosis. It is well known that ^{99m}Tc -labeled bone scan radiotracers can localize in the myocardial amyloid deposits, but the use of this imaging modality to differentiate between the two subtypes has only lately been revisited. We report a case of a 76-year-old man with a clinical diagnosis of amyloidosis who underwent a bone scan that had features of ATTR amyloidosis. To the best of our knowledge, this is the first case report in Sub-Saharan Africa.

Keywords: AL, bone scintigraphy, cardiac amyloidosis, transthyretin ATTR

INTRODUCTION

Cardiac amyloidosis is a rare cause of rapidly progressive, restrictive cardiomyopathy and congestive heart failure.^[1] It is mostly difficult to diagnose and almost always associated with poor prognosis. There are two main subtypes of cardiac amyloidosis: transthyretin-related cardiac amyloidosis (ATTR) and cardiac light-chain (AL) amyloidosis.^[2,3] Differentiating the two is important for both prognosis and management, and this was only possible through invasive biopsy procedures. Recently, however, a few published cases have shown that bone scintigraphy is able to reliably distinguish between the two.^[4] In this case, we report findings on the bone scan that supported the diagnosis of ATTR cardiac amyloidosis.

CASE REPORT

A 76-year-old male who had clinical suspicion for cardiac amyloidosis was referred to our department for bone scintigraphy to try and differentiate between the two main clinical subtypes. Planar whole-body images were performed in the anterior and posterior projections 4 h after intravenous administration of 718 MBq (19.4 mCi) of ^{99m}Tc -methylene diphosphonate (^{99m}Tc MDP).

The bone scan images [Figure 1] demonstrated diffusely increased tracer uptake in the heart and attenuated tracer uptake throughout the bones. Increased tracer uptake was also seen in the soft tissues of deltoid, gluteal, and abdominal walls. No other site of abnormal tracer concentration was seen.

Figure 1a and b shows the planar whole-body bone scan in the anterior projection [Figure 1a] and a zoomed image [Figure 1b] demonstrating moderately intense cardiac uptake with soft tissue uptake involving the shoulders, chest, abdominal walls, and hips. Skeletal tracer uptake appears mildly suppressed.

DISCUSSION

Cardiac amyloidosis is a rare cause of rapidly progressive, restrictive cardiomyopathy and congestive heart failure.^[1] It

ISSA MENGE KURIA, SAMUEL NGUKU GITAU, KHALID BASHIR MAKHDOMI

Department of Imaging and Diagnostic Radiology, Aga Khan University Hospital, Nairobi, Kenya


Address for correspondence: Dr. Issa Menge Kuria, General Radiologist, Department of Imaging and Diagnostic Radiology, Aga Khan University Hospital, Nairobi, Kenya. E-mail: mengetr006@gmail.com

This is an open access journal, and articles are distributed under the terms of the Creative Commons Attribution-NonCommercial-ShareAlike 4.0 License, which allows others to remix, tweak, and build upon the work non-commercially, as long as appropriate credit is given and the new creations are licensed under the identical terms.

For reprints contact: reprints@medknow.com

How to cite this article: Kuria IM, Gitau SN, Makhdomi KB. Bone scintigraphy imaging of cardiac amyloidosis. World J Nucl Med 2019;18:314-6

Submission: 11-Jan-19, **Accepted:** 20-Mar-19

Access this article online	
Website: www.wjnm.org	Quick Response Code 
DOI: 10.4103/wjnm.WJNM_9_19	

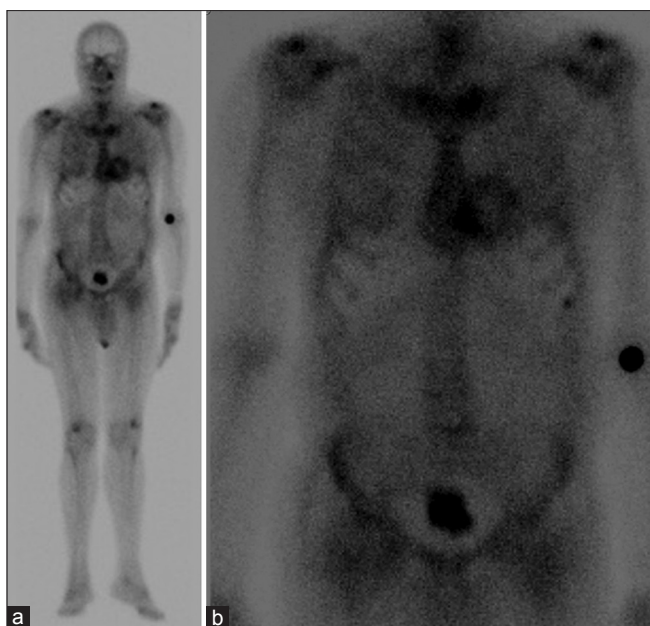


Figure 1: (a and b) shows the planar whole-body bone scan in the anterior projection (a) and a zoomed image (b) demonstrating moderately intense cardiac uptake with soft tissue uptake involving the shoulders, chest, abdominal walls, and hips. Skeletal tracer uptake appears mildly suppressed

is mostly difficult to diagnose and almost always associated with poor prognosis. There are two main subtypes of cardiac amyloidosis: transthyretin-related cardiac amyloidosis (ATTR) and cardiac light-chain (AL) amyloidosis.^[2,3] ATTR amyloidosis may be acquired and hereditary that is either associated with variants in the transthyretin gene or associated with wild-type transthyretin (also called senile systemic amyloidosis).

Cardiac AL amyloidosis is more rapidly progressive than the ATTR type where the former is associated with >50% mortality within 6 months after the diagnosis while the ATTR subtype has a favorable prognosis of 98% 2-year survival.^[5,6] The treatment options for the two subtypes are also different with AL subtype likely to benefit from cytotoxic chemotherapy,^[7] while more novel therapies are used for ATTR including inotersen, which was recently approved by the FDA for the treatment of hereditary ATTR amyloidosis polyneuropathy.^[8] Differentiating the type of cardiac amyloidosis (ATTR or AL) is thus vital in guiding patient management.

Because cardiac amyloidosis has nonspecific clinical symptoms as well as nonspecific electrocardiogram and echocardiographic findings,^[9] it remains a diagnostic challenge and is often underdiagnosed. The gold standard for the diagnosis of amyloidosis is through biopsy of a clinically affected organ, with Congo red histology demonstrating green birefringence. However, when amyloidosis is clinically suspected, biopsy of the salivary glands, rectum,

or subcutaneous fat usually yields the diagnosis in 60%–80% of patients with AL amyloidosis.^[10] Unfortunately, a much lower yield is observed in patients with ATTR amyloidosis that requires for endomyocardial biopsy (EMB) to confirm the diagnosis.^[11] EMB has its own risks including myocardial perforation, tamponade, and fatality. It also requires expertise and this can introduce diagnostic delays.^[12]

Cardiac magnetic resonance imaging (CMR) is a more discriminating method for cardiac amyloidosis but does not differentiate types of amyloidosis and cannot be performed in the presence of implanted devices.^[13] All of these factors contribute to under diagnosis, which is crucial given the poor prognosis of AL and ATTR cardiac amyloidosis and the increasing availability of novel therapies for both subtypes.^[14,15]

Radionuclide bone scans with ^{99m}Tc-labeled bisphosphonates have been anecdotally reported to localize cardiac amyloid deposits, although the molecular basis for this remains unknown.^[16] The cardiac uptake on the planar images is visually scored using the Perugini grading system.^[17] Briefly, it is categorized as follows: Grade 0 – no cardiac uptake and normal bone uptake; Grade 1 – cardiac uptake which is less intense than the bone signal; Grade 2 – cardiac uptake with intensity similar or greater than bone signal; and Grade 3 – cardiac uptake with much attenuated or absent bone signal. An uptake of Grade 2 and above is considered significant.^[17] A systematic evaluation of bone scans of 857 patients with histologically proven amyloid revealed that cardiac ATTR amyloidosis can be reliably diagnosed in the absence of histology provided that all of the following criteria are met: heart failure with an echocardiogram or CMR that is consistent with or suggestive of amyloidosis, Grade 2 or 3 cardiac uptake on a radionuclide scan with ^{99m}Tc-labeled 3,3-diphosphono-1,2-propanodicarboxylic acid (^{99m}Tc-DPD), ^{99m}Tc-labeled pyrophosphate (^{99m}Tc-PYP), or ^{99m}Tc-labeled hydroxymethylene diphosphonate, and absence of a detectable monoclonal protein.^[4] More recently, studies^[18,19] have shown that ^{99m}Tc-labeled MDP can also preferentially bind to ATTR as similar to ^{99m}Tc PYP and ^{99m}Tc DPD.

Given that ^{99m}Tc-MDP is more readily available than DPD or PYP and already in use for routine bone scans, it would provide a more feasible option in this diagnostic algorithm. Unfortunately, cardiac localization of radiotracers also occurs in a small proportion of patients with AL amyloidosis, and although it is usually low grade, it can confound distinguishing between cardiac AL and ATTR subtypes.^[20] A recent study by Hutt *et al.*^[21] that had a cohort of 321 patients with suspected cardiac amyloidosis that used ^{99m}Tc DPD as the radiotracer

demonstrated that in addition to the intense cardiac uptake in patients with ATTR, these patients also demonstrated extensive soft tissue uptake in the deltoid, abdominal wall, and gluteal muscles that was not seen in the AL amyloidosis patients. They concluded that the soft tissue uptake in those sites is specific to ATTR. Our patient demonstrated intense cardiac uptake in addition to soft tissue uptake in the deltoid, gluteal, and abdominal wall muscles that is relatively specific to ATTR amyloidosis.

CONCLUSION

Several studies^[4,20] have concluded that cardiac transthyretin amyloidosis can be reliably diagnosed in the absence of histology provided that all of the following criteria are met: heart failure with an echocardiogram or CMR that is consistent with or suggestive of amyloidosis, intense cardiac uptake on a ^{99m}Tc labeled bisphosphonate bone scan, no detectable monoclonal protein in serum with normal serum-free light chains. AL amyloidosis is unlikely in any patient satisfying all the above criteria. Invasive EMB can therefore be avoided in elderly patients who satisfy these criteria. In this regard, ^{99m}Tc-labeled bisphosphonate bone scans serve an integral role in the workup of patients with suspected cardiac amyloidosis. Histological confirmation and typing of amyloid should be sought in all cases of suspected cardiac amyloidosis in whom these criteria are not met.

Declaration of patient consent

The authors certify that they have obtained all appropriate patient consent forms. In the form the patient(s) has/have given his/her/their consent for his/her/their images and other clinical information to be reported in the journal. The patients understand that their names and initials will not be published and due efforts will be made to conceal their identity, but anonymity cannot be guaranteed.

Acknowledgement

We thank our many cardiology colleagues for referring and caring for the patients.

Financial support and sponsorship

Nil.

Conflicts of interest

There are no conflicts of interest.

REFERENCES

- Merlini G, Bellotti V. Molecular mechanisms of amyloidosis. *N Engl J Med* 2003;349:583-96.
- Westermarck P, Benson MD, Buxbaum JN, Cohen AS, Frangione B, Ikeda S, *et al.* Amyloid: Toward terminology clarification. Report from the Nomenclature Committee of the International Society of Amyloidosis. *Amyloid* 2005;12:1-4.
- Vrana JA, Gamez JD, Madden BJ, Theis JD, Bergen HR 3rd, Dogan A. Classification of amyloidosis by laser microdissection and mass spectrometry-based proteomic analysis in clinical biopsy specimens. *Blood* 2009;114:4957-9.
- Gillmore JD, Maurer MS, Falk RH, Merlini G, Damy T, Dispenzieri A, *et al.* Nonbiopsy diagnosis of cardiac transthyretin amyloidosis. *Circulation* 2016;133:2404-12.
- Ruberg FL, Maurer MS, Judge DP, Zeldenrust S, Skinner M, Kim AY, *et al.* Prospective evaluation of the morbidity and mortality of wild-type and V122I mutant transthyretin amyloid cardiomyopathy: The transthyretin amyloidosis cardiac study (TRACS). *Am Heart J* 2012;164:222-80.
- Rapezzi C, Quarta CC, Riva L, Longhi S, Gallelli I, Lorenzini M, *et al.* Transthyretin-related amyloidoses and the heart: A clinical overview. *Nat Rev Cardiol* 2010;7:398-408.
- Ng B, Connors LH, Davidoff R, Skinner M, Falk RH. Senile systemic amyloidosis presenting with heart failure: A comparison with light chain-associated amyloidosis. *Arch Intern Med* 2005;165:1425-9.
- FDA Approves New Treatment for Hereditary Transthyretin-Mediated Amyloidosis. Available from: <https://www.mdedge.com/clinicalneurologynews/article/176617/rare-diseases/fda-approves-new-treatment-hereditary>. [Last accessed on 2019 Jan 07].
- Falk RH. Diagnosis and management of the cardiac amyloidoses. *Circulation* 2005;112:2047-60.
- Ansari-Lari MA, Ali SZ. Fine-needle aspiration of abdominal fat pad for amyloid detection: A clinically useful test? *Diagn Cytopathol* 2004;30:178-81.
- Zotero | Home. Available from: <https://www.zotero.org/>. [Last accessed on 2018 Jan 21].
- Maurer MS. Noninvasive identification of ATTRwt cardiac amyloid: The re-emergence of nuclear cardiology. *Am J Med* 2015;128:1275-80.
- Sachchithanatham S, Wechalekar AD. Imaging in systemic amyloidosis. *Br Med Bull* 2013;107:41-56.
- Dubrey S, Ackermann E, Gillmore J. The transthyretin amyloidoses: Advances in therapy. *Postgrad Med J* 2015;91:439-48.
- Sekijima Y, Kelly JW, Ikeda S. Pathogenesis of and therapeutic strategies to ameliorate the transthyretin amyloidoses. *Curr Pharm Des* 2008;14:3219-30.
- Ali A, Turner DA, Rosenbush SW, Fordham EW. Bone scintigram in cardiac amyloidosis: A case report. *Clin Nucl Med* 1981;6:105-8.
- Hutt DF, Fontana M, Burniston M, Quigley AM, Petrie A, Ross JC, *et al.* Prognostic utility of the Perugini grading of ^{99m}Tc-DPD scintigraphy in transthyretin (ATTR) amyloidosis and its relationship with skeletal muscle and soft tissue amyloid. *Eur Heart J Cardiovasc Imaging* 2017;18:1344-50.
- Lu Y, Groth JV, Emmadi R. Cardiac amyloidosis detected on Tc-99m bone scan. *Nucl Med Mol Imaging* 2015;49:78-80.
- Ak I, Vardareli E, Erdinç O, Kasapoğlu E, Ata N. Myocardial Tc-99m MDP uptake on a bone scan in senile systemic amyloidosis with cardiac involvement. *Clin Nucl Med* 2000;25:826-7.
- Bokhari S, Castaño A, Pozniakoff T, Deslisle S, Latif F, Maurer MS. (99m) Tc-pyrophosphate scintigraphy for differentiating light-chain cardiac amyloidosis from the transthyretin-related familial and senile cardiac amyloidoses. *Circ Cardiovasc Imaging* 2013;6:195-201.
- Hutt DF, Quigley AM, Page J, Hall ML, Burniston M, Gopaul D, *et al.* Utility and limitations of 3,3'-diphosphono-1,2-propanodicarboxylic acid scintigraphy in systemic amyloidosis. *Eur Heart J Cardiovasc Imaging* 2014;15:1289-98.