

Multiple bilateral variations in urogenital vasculature- A clinico-embryological perspective

THAKUR, A.^{1*}, LOH, H. K.², MEHTA, V. ², SURI, R. K.³ and RATH, G.⁴

¹MD, Assistant Professor, Department of Anatomy, Vardhman Mahavir Medical College & Safdarjung hospital, New Delhi- 110029, India

²MS, Professor, Department of Anatomy, Vardhman Mahavir Medical College & Safdarjung hospital, New Delhi- 110029, India

³MS, Director Professor, Department of Anatomy, Vardhman Mahavir Medical College & Safdarjung hospital, New Delhi- 110029, India

⁴MS, FIAMS, Director Professor, Department of Anatomy, Vardhman Mahavir Medical College & Safdarjung hospital, New Delhi- 110029, India

*e-mail: thakuravns@gmail.com

Abstract

Precise knowledge of urogenital vascular anomalies has become extremely important in the past decade with increasing numbers of renal transplantations, minimally invasive vascular surgeries and numerous radiologic procedures. We report the presence of multiple variations in urogenital vasculature bilaterally in a 52 year old male Indian cadaver. Twin renal arteries were encountered bilaterally. Main renal artery was originating bilaterally at L1 vertebral level and accessory renal arteries were originating as ventral branches of abdominal aorta at L3 vertebral level and were travelling to the lower part of the respective kidneys. Twin renal veins were draining the right kidney independently whereas the left renal vein was bifurcating into two tributaries and draining separately into the inferior vena cava. Multiple testicular veins were found bilaterally. This report will prove to be helpful in various surgical and radiological interventions performed in the field of urology.

Keywords: renal artery, renal veins, testicular vein, renal transplant.

1 Introduction

Renal arteries are a pair of lateral branches of the abdominal aorta given at the lower border of first lumbar vertebra. Most commonly a single renal artery supplies each kidney. But variations in the number and origin of renal arteries have been described in the literature by many authors (SHAKERI, TUBBS, SHOJA et al., 2007; RAO, BHAT, VENKATARAMANA et al., 2006; SATYAPAL, HAFJEJEE, SINGH et al., 2000; LOH, GUPTA, ARORA et al., 2009; DHURIA, LOH, GUPTA et al., 2011). Variations in the renal arteries have been reported to be ranging from 9 to 76% (SATYAPAL, HAFJEJEE, SINGH et al., 2000). Renal veins are large veins arising at the hilum and draining into the inferior vena cava at right angles. The left renal vein is longer and travels anterior to the abdominal aorta. Multiple renal veins have been reported in the literature (NAYAK, 2008; MADHYASTHA, SURESH and RAO, 2001; KAYALVIZHI, MONISHA and USHA, 2011). Pampiniform plexus draining the testis form four testicular veins at the superficial inguinal ring which traverse through the inguinal canal and join to form two veins at the deep inguinal ring. These two veins unite to form a single testicular vein in the posterior abdominal wall. The left testicular vein drains into the left renal vein and the right testicular vein drains into the inferior vena cava. Accessory renal vessels may be associated with other vascular variations including testicular veins (KAYALVIZHI, MONISHA and USHA, 2011; BERGMAN, CASSELL, SAHINOGLU et al., 1992). In this study we report multiple numbers of rare variations of the

urogenital vasculature and their clinical and embryological relevance. Knowledge of these vascular anomalies is essential for medical professionals performing different radiological and urological interventions.

2 Case Report

Multiple variations in the vasculature of kidneys and gonads were encountered bilaterally during routine dissection of a 52 year old male cadaver for educational purposes in the department of anatomy of Vardhman Mahavir Medical College and Safdarjung hospital, New Delhi. Presence of these variations deferred the normal hilar anatomy bilaterally.

On the left side, the left main renal artery (LMRA) was originating as a lateral branch of the abdominal aorta at the lower border of first lumbar vertebra and coursed towards the superior part of the hilum of left kidney. LMRA divided into two branches 1.9 cms distal to its origin from the abdominal aorta. The superior branch coursed downwards and entered the anterior part of the middle of the hilum just anterior to the left renal vein and pelvis. The inferior branch further divided into two branches which entered the upper part of the hilum of the kidney posterior to the left renal vein. Hence the left renal vein was sandwiched between the two branches of the LMRA. The left accessory renal artery (LARA) originated as a ventral branch of the abdominal aorta at the lower border of third lumbar vertebra 1.7 cms distal to the origin of inferior mesenteric artery. It coursed posterior

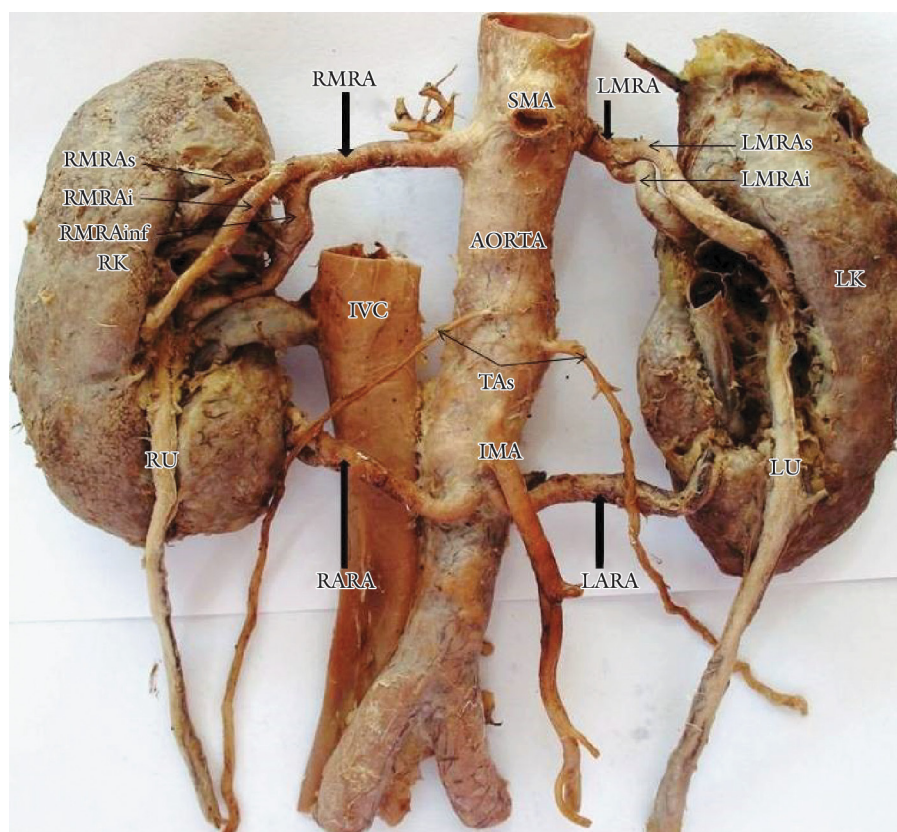


Figure 1. RMRA- right main renal artery; LMRA- left main renal artery; RMRAs, RMRAi, RMRAinf- superior, intermediate & inferior branches of right main renal artery; LMRAs, LMRAi- superior & inferior branches of left main renal artery; RK- right kidney; LK- left kidney; IVC- inferior vena cava; TAs- testicular arteries; SMA- superior mesenteric artery; IMA- inferior mesenteric artery; RARA- right accessory renal artery; LARA- left accessory renal artery; RU- right ureter; LU- left ureter.

to the inferior mesenteric artery and the left testicular vessels to reach the lower part of the hilum of left kidney (Figure 1).

The main trunk of the left renal vein was formed by union of three hilar tributaries. This trunk divided into two terminal tributaries (superior & inferior) 2.1 cms distal to its formation. The superior tributary coursed in front of the aorta and posterior to the superior mesenteric artery to drain into the inferior vena cava at the lower border of first lumbar vertebra. It received a common trunk formed by the union of the left inferior phrenic and left suprarenal veins 2.4 cms proximal to its termination in the inferior vena cava. The inferior tributary coursed downwards posterior to the left testicular vessels, LARA and the abdominal aorta to drain into the inferior vena cava at the lower border of third lumbar vertebra. It received the 2nd, 3rd and 4th left lumbar veins on its posterior aspect.

On the left side, double testicular veins were present at the deep inguinal ring. They coursed upwards on both sides of the left testicular artery to join and form a single left testicular vein at the lower border of third lumbar vertebra. There was an anastomotic communication between the two left testicular veins 5.2 cms from the left deep inguinal ring. The single testicular vein passed anterior to the left testicular artery and the superior tributary of the left renal vein to drain into the common trunk formed by the union of left inferior phrenic and left suprarenal veins. Further, this common trunk drained into the superior tributary of the left renal vein (Figure 2).

On the right side, the right main renal artery (RMRA) originated from the lateral side of the abdominal aorta at the lower border of first lumbar vertebra 0.6 cms below the origin of superior mesenteric artery. It coursed laterally posterior to the inferior vena cava and divided into three branches 3.6 cms distal to its origin. The superior branch further divided into two branches and entered the superior part of the hilum of the right kidney. The intermediate branch travelled anterior to the right superior renal vein to enter the anterior part of the renal hilum anterior to the left renal pelvis. The inferior branch travelled posterior to the right superior renal vein and further divided into two branches, one of which reached the upper part of the right renal hilum and the other entered the middle of the renal hilum just posterior to the right renal pelvis. This arrangement of RMRA and its branches sandwiched the right renal pelvis and the right superior renal vein between the intermediate and inferior branches. The right accessory renal artery (RARA) originated from the ventral aspect of abdominal aorta at the lower border of third lumbar vertebra very close to the origin of LARA. It coursed anterior to the inferior vena cava and the right testicular vessels and divided into three branches which entered the lower part of the kidney just below the renal hilum (Figure 1).

Twin renal veins were encountered on the right side and were called the right superior and inferior renal veins (RSRV, RIRV). RSRV was formed by the union of three tributaries at the renal hilum. It traversed upwards and drained into the

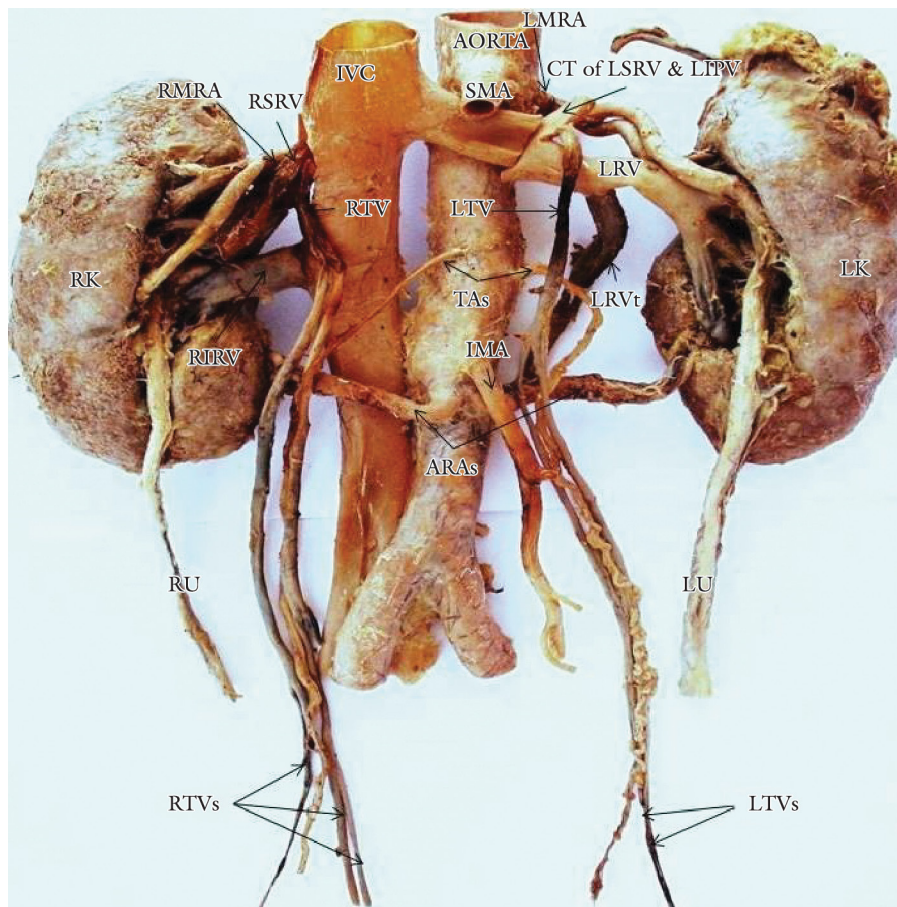


Figure 2. LMRA- left main renal artery; RMRA- right main renal artery; RSRV- right superior renal vein; RIRV- right inferior renal vein; LRV- left renal vein; LRVt- left renal vein tributary; RTV- right testicular vein; LTV- left testicular vein; CT of LSRV & LIPV- common trunk of left suprarenal vein & left inferior phrenic vein; TAs- testicular arteries; IVC- inferior vena cava; SMA- superior mesenteric artery; IMA- inferior mesenteric artery; ARAs- accessory renal arteries; RTVs- tributaries of right testicular vein; LTVs- tributaries of left testicular vein; RU- right ureter; LU- left ureter; RK- right kidney; LK left kidney.

inferior vena cava at the lower border of first lumbar vertebra. Just proximal to its termination it received the common trunk of the right testicular veins. RIRV was formed by two hilar tributaries and it coursed laterally posterior to the right testicular vessels to drain into the inferior vena cava at the level of second lumbar vertebra.

Three right testicular veins emerged at the deep inguinal ring. Two of the medial testicular veins joined together to form a common tributary 6.8 cms from the deep inguinal ring. This common tributary had an anastomotic communication with the lateral vein 7.4 cms from the deep inguinal ring. The two testicular veins hence formed travelled upwards on both sides of the testicular artery and were related anteriorly to the RARA and RIRV. A common trunk of right testicular vein was formed by the union of the two testicular tributaries at the level of second lumbar vertebra just lateral to the inferior vena cava. This common trunk drained into the terminal portion of the RSRV just before the later opened into the inferior vena cava (Figure 2).

Left and right ureters coursed anterior to the lower pole of the kidney. The left hilum was enlarged and was extremely deep measuring 4.2 cms vertically, 3.3 cms transversely and 1.8 cms deep. The right hilum was also enlarged measuring 3.6 cms vertically and 3.1 cms transversely. The hilar anatomy

was altered bilaterally due the presence of multiple variations of renal vessels. The arrangement of structures in the hilum of the left kidney from anterior to posterior was superior branch of LMRA, left renal pelvis, renal vein and inferior branch of LMRA. LARA lied in a posterior plane in the lower portion of the hilum. The arrangement of structures in the hilum of the right kidney from anterior to posterior was intermediate branch of RMRA, right renal pelvis, RSRV & RIRV and inferior branch of RMRA.

3 Discussion

Although variations in the renal and gonadal vessels have been reported in the past, but there are no reports of unique urogenital vascular pattern as reported in this study. In the literature additional renal arteries have been referred to as accessory, aberrant, anomalous, supernumerary, multiple and polar. Bergman et al. reported the incidence of twin renal arteries to be 10% based on their study of 10,967 kidneys (BERGMAN, CASSELL, SAHINOGLU et al., 1992) whereas Khamanarong et al. found it to be 17.43% (KHAMANARONG, PRACHANEY, UTRARAVICHIEEN et al., 2004). Bordei et al. studied 272 kidneys and found the incidence of double renal

arteries to be 20% (BORDEI, SAPTE and ILIESCU, 2004). Additional renal arteries are more frequently unilateral. Sampaio and Passos reported the incidence of bilateral double renal arteries to be 4.5% (SAMPAIO and PASSOS, 1992). The incidence of accessory renal arteries has been reported to be different in different ethnic races (African-37.1%, Indian-17.4%, Caucasian- 35.3% and Colored-18.5%). The abnormalities in renal arteries are due to its different developmental position. Kidney starts developing in the pelvic cavity and ascends to its normal position in the lumbar region. While the kidneys ascend to lumbar region, their arterial supply also shifts from common iliac artery to the abdominal aorta (ASALA, CHAUDHARY, MASUMBUKO-KAHAMBA et al., 2001). But in the present case, though kidneys were situated in the lumbar region, they were supplied by an accessory renal arteries arising from the ventral aspect of abdominal aorta at the level third lumbar vertebra. This might be due to the failure in the disappearance of the mesonephric arteries which supplied the kidney during its ascend. Renal artery variations are categorized into two types, early branching and extra-renal arteries. In early branching main renal artery is more proximal to hilum. Extra-renal arteries are grouped into hilar (accessory) and polar (aberrant) arteries (SATYAPAL, HAFJEJEE, SINGH et al., 2000; CINMAN, OKEKE and SMITH, 2007). Urologists should be careful during vascular procedures as these extra-renal arteries are end arteries and their damage would lead to ischemia of the area supplied by them. Furthermore, care has to be taken to anastomose these arteries during renal transplantation.

Variations of the renal veins though reported are rare. Multiple renal veins have been reported in the past by a few authors (JANSCHKEK, ROTHE, HÖLZENBEIN et al., 2004; MALCIC-GÜRBÜZ, AKALIN, GÜMÜSCÜ et al., 2002). We have reported the presence of double renal veins on the right side and branching renal vein on the left side. These anomalies could be explained on the basis of persistence of renal venous collars and a particular developmental pattern of inferior vena cava (SATYAPAL, KALIDEEN, HAFJEJEE et al., 1999). Abnormal development and anastomosis of subcardinal and supracardinal venous channels can also lead to anomalies of renal vein. We have reported a retro-aortic branch of left renal vein which is of great clinical significance as an anomaly like this could lead to renal hypertension, thrombosis, hematuria and varicocele. Moreover, it poses a potential hazard to surgeons operating on the abdominal aorta.

Studies on variations of the testicular veins are very rare. Testicular veins develop from the post renal segment of the subcardinal vein and the sub-supracardinal anastomosis (right vein) during the 5th to 7th week of intra-uterine life. Asala, Chaudhary, Masumbuko-Kahamba et al. (2001) have reported the termination of the testicular vein into the right renal vein. Variations of testicular veins have been classified into four types (11); totally duplicated left veins (type 1), partially duplicated left veins (type 2), beaded bilateral veins (type 3), and high drainage into the inferior vena cava on the left and termination in the right renal vein on the right (type 4). Thus the testicular venous variations reported in the present study can be classified as type 1 and 4. We have also reported anomalous termination of testicular veins bilaterally which could be the main factor in causation and recurrence

of varicocele. Surgeons operating in cases of varicocele should be aware of these variations of the testicular veins to avoid recurrence.

Altered hilar arrangement of structures is of utmost importance during surgeries requiring hilar dissection. Variations in the hilar anatomy as reported in the present study should be borne in mind to avoid conversion of a laproscopic procedure into an open surgery.

References

- ASALA, S., CHAUDHARY, SC., MASUMBUKO-KAHAMBA, N. and BIDMOS, M. Anatomical variations in the human testicular blood vessels. *Annals of Anatomy - Anatomischer Anzeiger*, 2001, vol. 183, n. 6, p. 545-549. [http://dx.doi.org/10.1016/S0940-9602\(01\)80064-9](http://dx.doi.org/10.1016/S0940-9602(01)80064-9)
- BERGMAN, RA., CASSELL, MD., SAHINOGLU, K. and HEIDGER JUNIOR, PM. Human doubled renal and testicular arteries. *Annals of Anatomy - Anatomischer Anzeiger*, 1992, vol. 174, n. 4, p. 313-315. [http://dx.doi.org/10.1016/S0940-9602\(11\)80292-X](http://dx.doi.org/10.1016/S0940-9602(11)80292-X)
- BORDEI, P., SAPTE, E. and ILIESCU, D. Double renal arteries originating from the aorta. *Surgical and Radiologic Anatomy*, 2004, vol. 26, n. 6, p. 474-479. PMID:15378279. <http://dx.doi.org/10.1007/s00276-004-0272-9>
- CINMAN, NM., OKEKE, Z. and SMITH, AD. Pelvic kidney: associated diseases and treatment. *Journal of Endourology*, 2007, vol. 21, n. 8, p. 836-842. PMID:17867938. <http://dx.doi.org/10.1089/end.2007.9945>
- DHURIA, R., LOH, HK., GUPTA, V., MEHTA, V., ARORA, J., ROY, S., SURI, RK. and RATH, G. Multiple variations of abdominal arterial anatomy: morphological description and clinical relevance. *International Medical Journal*, 2011, vol. 18, n. 3, p. 240-242.
- JANSCHKEK, ECS., ROTHE, AU., HÖLZENBEIN, TJ., LANGER, F., BRUGGER, PC., POKORNY, H., DOMENIG, CM., RASOUL-ROCKENSCHAUB, S. and MÜHLBACHER, F. Anatomic basis of right renal vein extension for cadaveric kidney transplantation. *Urology*, 2004, vol. 63, n. 4, p. 660-664. PMID:15072874. <http://dx.doi.org/10.1016/j.urology.2003.11.010>
- KAYALVIZHI, I., MONISHA, B. and USHA, D. Accessory left testicular artery in association with double renal vessels: a rare anomaly. *Folia Morphologica*, 2011, vol. 70, n. 4, p. 309-311. PMID: 22117252
- KHAMANARONG, K., PRACHANEY, P., UTRARAVICHEN, A., TONG-UN, T. and SRIPAORAYA, K. Anatomy of renal arterial supply. *Clinical Anatomy*, 2004, vol. 17, n. 4, p. 334-336. PMID:15108340. <http://dx.doi.org/10.1002/ca.10236>
- LOH, HK., GUPTA, V., ARORA, J., MEHTA, V., SURI, R., KOHLI, M. and RATH, G. Atypical twin renal arteries with altered hilar anatomy. *International Journal of Anatomical Variations*, 2009, vol. 2, p. 124-126.
- MADHYASTHA, S., SURESH, R. and RAO, R. Multiple variations of renal vessels and ureter. *Indian Journal of Urology*, 2001, vol. 17, n. 2, p. 164-165.
- MALCIC-GÜRBÜZ, J., AKALIN, A., GÜMÜSCÜ, B. and ÇAVDAR, S. Clinical implications of concomitant variations of the testicular, suprarenal and renal veins: a case report. *Annals of Anatomy - Anatomischer Anzeiger*, 2002, vol. 184, n. 1, p. 35-39. [http://dx.doi.org/10.1016/S0940-9602\(02\)80031-0](http://dx.doi.org/10.1016/S0940-9602(02)80031-0)
- NAYAK, BS. Multiple variations of the right renal vessels. *Singapore Medical Journal*, 2008, vol. 49, n. 6, p. e153-155. PMID: 18581008

RAO, M., BHAT, S. M., VENKATARAMANA, V., DEEPTHINATH, R. and BOLLA, S. R. Bilateral prehilal multiple branching of renal arteries: a case report and literature review. *Kathmandu University Medical Journal (KUMJ)*, 2006, vol. 4, n. 3, p. 345-348. PMID: 18603933

SAMPAIO, F. J. B. and PASSOS, M. A. R. Renal arteries: anatomic study for surgical and radiological practice. *Surgical and Radiologic Anatomy*, 1992, vol. 14, n. 2, p. 113-117. PMID: 1641734. <http://dx.doi.org/10.1007/BF01794885>

SATYAPAL, K. S., HAFJEJEE, A. A., SINGH, B., RAMSAROOP, L., ROBBS, J. V. and KALIDEEN, J. M. Additional renal arteries incidence and morphometry. *Surgical and Radiologic Anatomy*, 2000, vol. 23, n. 1, p. 33-38. PMID: 11370140

SATYAPAL, K. S., KALIDEEN, J. M., HAFJEJEE, A. A., SINGH, B. and ROBBS, J. V. Left renal vein variations. *Surgical and Radiologic Anatomy*, 1999, vol. 21, n. 1, p. 77-81. PMID: 10370998

SHAKERI, A. B., TUBBS, R. S., SHOJA, M. M., PEZESHK, P., FARAHANI, R. M., KHAKI, A. A., EZZATI, F. and SEYEDNEJAD, F. Bipolar supernumerary renal artery. *Surgical and Radiologic Anatomy*, 2007, vol. 29, n. 1, p. 89-92. PMID: 17061029

Received December 18, 2013

Accepted December 1, 2014