

Double inferior vena cava and associated venous anomalies: a case report

KHAMANARONG, K.*

Department of Anatomy, Faculty of Medicine, Khon Kaen University, 40002, Khon Kaen, Thailand

*E-mail: kkimap@kku.ac.th

Abstract

Introduction: Double inferior vena cava and associated venous anomalies are rare. **Materials and Methods:** In the present case study, during routine cadaveric dissection of the retroperitoneal region, an interesting venous anomalies was seen in the retroperitoneal region of a 70 years old embalmed male cadaver from the department of Anatomy, Khon Kaen University, Thailand. **Results:** I describe here a case of double inferior vena cava (IVC) associated with double left suprarenal veins (LSRV) and double right testicular veins (RTV). Double IVC were connected with the transverse interiliac vein. While the upper LSRV is a tributary of IVC, the lower LSRV is a tributary of the left renal vein. Right testicular vein bifurcate at about the height of iliac cristae to form medial and lateral RTVs, which drain into right IVC at different heights. All these duplication and associated anomalies are assumed to occur during embryological development. **Conclusion:** These anomalies are rare, but the knowledge about the possibilities of such anomalies is of great importance during retroperitoneal surgeries, and interventional radiology.

Keywords: double inferior vena cava, double suprarenal veins, double right testicular veins, venous anomalies.

1 Introduction

Double inferior vena cava (IVC) is a congenital venous anomaly caused by an unusual embryological development of the inferior vena cava (MOORE, PERSAUD and TORCHIA, 2013), estimated to occur in 0.2-3% of the population (NG and NG, 2009). Most of double IVC are incidentally found during diagnostic intervention with computed tomography (CT) or magnetic resonance imaging (MRI) (KAPETANAKIS, PAPADOPOULOS, GALANI et al., 2010). Since the renal segment of the IVC has the same origin as the gonadal veins in embryogenesis (ITOH, MORIYAMA, TOKUNAGA et al., 2001), variations of the IVC are often accompanied with anomalies of the gonadal vein (TAKAGI, NOZAKA and OHSAWA, 1982). Double IVC has significant clinical implications, especially during retroperitoneal surgeries or in the treatment of thrombotic diseases (RADERMECKER, VAN DAMME, KERZMANN et al., 2008). Also, understanding of the variation of the LSRV is clinically important for the renal transplantatation, laparoscopic adrenalectomy, and adrenal venous sampling. Laparoscopic adrenalectomy has become the technique of choice in adrenal surgery, of which principal complication is intraoperative hemorrhage (BONJER, SORM, BERENDS et al., 2000; SUZUKI, USHIYAMA, IHARA et al., 1999). Adrenal venous sampling has been used as the golden standard test for the differentiation between unilateral adrenal adenoma and bilateral adrenal cortical hyperplasia, both of which are the most common causes of primary hyperaldosteronism (STACK, ROSCH, COOK et al., 2001). Likewise, prediction of the presence of duplicate testicular veins is important to avoid diagnostic and therapeutic errors during radiological and surgical procedures, especially ligation of varicocele, because, if unnoticed, it may cause recurrence of varicocele (TUBBS, SALTER and OAKES, 2005). Double IVC with coexistence of double right testicular veins (RTV) and double

LSRV is extremely rare, and awareness of such venous anomaly is necessary to reduce severe hemorrhage in retroperitoneal surgeries, and in interventional radiology (CHEN, EMURA, NAGASAKI et al., 2012).

The objective of this study is to present a case of a double IVC accompanied by a double LSRV and double RTV.

2 Case Report

This rare venous anomaly was found in a 70-year-old male Thai cadaver during routine cadaver dissection in the Department of Anatomy, Faculty of Medicine, Khon Kaen University, Thailand. To investigate the retroperitoneal visceral organs, the anterior abdominal organs were removed. The kidneys and the adrenal glands were dissected according to the standard technique. Double IVC were found together with double left suprarenal veins (LSRV) and double right testicular veins. While the upper LSRV was a tributary of IVC, the lower LSRV was that of the left renal vein (Figure 1). In this case, the IVC present normally on the right side of abdominal aorta, but another similar vein, which was identified as left IVC on the left side of aorta, is parallel to normal IVC. After joining with the left renal vein, the left IVC across the aorta and joined the right IVC. Then, the common IVC traverse the normal retrohepatic route before passing through the diaphragm into the right atrium in normal anatomical position. The right renal vein drained into the right IVC. The interiliac vein was situated ventral to the body of the fifth lumbar vertebra anastomosing the right and left IVC. The right testicular vein (RTV) was bifurcated at the height of the iliac crest, and the medial branch drained to the right IVC below the height of right kidney. The lateral branch also drained to the right IVC, but just below the point of drainage of the right renal vein

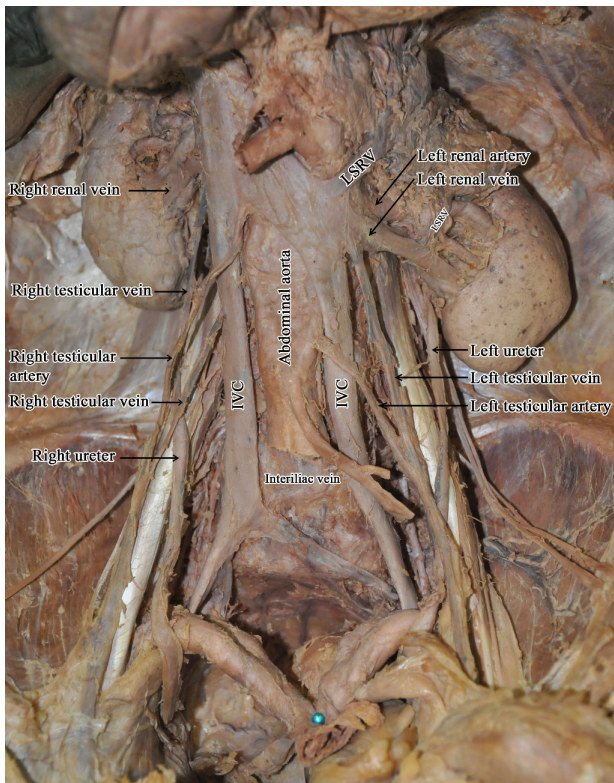


Figure 1. Photograph showing double inferior vena cava (IVC), double left suprarenal veins (LSRV), and double right testicular veins (RTV).

(Figure 1). The renal vessels followed the normal pattern. Both ureters lie laterally to the each IVC in their course to the pelvis, with no apparent abnormalities.

3 Discussion

The retroperitoneal venous system develops from three paired fetal venous systems, the posterior cardinal, subcardinal and the supracardinal systems (MAYO, GRAY, ST LOUIS et al., 1983). During normal development, IVC is converted to a unilateral, right-sided system, consisting of four components: (1) the infra-renal segment from the right supracardinal vein, (2) the renal segment from the right supracardinal anastomosis, (3) the suprarenal segment from the right subcardinal vein, and (4) the hepatic segment from the right hepatic vein. Double IVC is considered to happen because of the persistence of both supracardinal veins (MATHEWS, SMITH, FISHMAN et al., 1999; BASS, REDWINE, KRAMER et al., 2000). Chen, Emura, Nagasaki et al. (2012), reviewed 109 cases of IVC anomalies and found that 74 of them have interiliac anastomosis. According to their classification of IVC anomalies, our case reported here is compatible with their Type 2d, double IVC connected by transversely running interiliac vein, which is assumed to be the left common iliac vein in normal development (OERTEL, 1928).

Double IVC is a rare and usually clinically silent venous anomaly. Discovery of double IVC in the operating room would lead to unexpectedly serious technical difficulties in certain recipients in the laparoscopic nephrectomy (KENNEALEY, SAIDI, MARKMANN et al., 2009). There are several case

reports of thromboembolic events occurring in patients with double IVC (KOUROUKIS and LECLERC, 1996). In radiology, the presence of double IVC can be mistaken as lymphadenopathy (KLIMBERG and WAJSMAN, 1986) or left pyeloureteric dilatation (GAY, ARMISTEAD, WEBER et al., 1991). The interiliac vein might cause problems due to unexpected hemorrhage during retroperitoneal surgery, such as anterior lumbar interbody fusion (INAMASU and GUIOT, 2005). The interiliac vein is a decisive factor in determining the strategy for venous interventional radiology such as IVC filter placement because DIVC is a possible risk factor for deep venous thrombosis (ANNE, PALLAPOTHU, HOLMES et al., 2005).

The left SRV normally receives blood from the left suprarenal gland and drain into the left renal vein. Sèbe, Peyromaure, Raynaud et al. (2002) examined 88 venograms and found anatomical variations in 5% of the right and 6% of the left SRV. In adrenal venous sampling procedure, it is important to review anatomy of SRVs from thin slices of CT scan prior to the intervention. Catheter selection is determined according to the anatomy of the suprarenal veins. The approach to the left suprarenal vein should be made under different position according to the position of the venous anatomy. Detailed knowledge of the variation of left SRV including double left SRV is critically important for the effective planning for the sampling procedure interpretation (DAUNT, 2005). Also, in laparoscopic adrenalectomy procedure, it is important to know anatomical variation to avoid the risk of massive intraoperative hemorrhage. Excessive traction of an adrenal gland without control of the principal adrenal vein on the left may injure the renal vein or the IVC (SÈBE, PEYROMAURE, RAYNAUD et al., 2002). The gonadal veins may be misinterpreted as a double IVC because they run close to the ipsilateral IVC, particularly the left gonadal vein that drains into the left renal vein (CHEN, EMURA, NAGASAKI et al., 2012).

Embryologically, the SRVs are formed by the stem of the subcardinal veins (MOORE, PERSAUD and TORCHIA, 2013). In the present case, double left SRV were identified, the upper left SRV as a tributary of IVC, and the lower one as a tributary of the left renal vein. Malposition of the left suprarenal gland during embryonic development might cause a small distance of transposition of an intra-abdominal organ from its usual anatomic location which in turn alter its vascular variation (OZTURK, UZMANSEL, KARA et al., 2010). Recently we found a case of double left SRV in a 62 year-old-male cadaver (KHAMANARONG, SAWATPANICH and CHAICHUN, 2015). In that case, other vascular anomalies were not found and two left SRVs drain into the left renal vein. About the anomalies of testicular veins, bifurcation of the right testicular veins is very rare. The right testicular vein develops from the lower part of the right subcardinal vein. The terminal bifurcation of the right testicular vein might be due to the bifurcation of the right subcardinal vein during its development (NAYAK, RAO, SHETTY et al., 2013).

4 Conclusion

To our best knowledge, this is the first record of the coexistence of double IVC, double left SRV, and double right testicular veins. Those anomalies have particular importance for the various interventions that take place during retroperitoneal surgeries, and is essential for venous interventional radiologists,

orthopedists to reduce the risk of serious hemorrhage during surgical treatment and to avoid operative complication.

This study was approved by the Research and Ethics Committee of the Faculty of Medicine, Khon Kaen University with the approval number HE591077.

Acknowledgements: I gratefully acknowledge those who donated their body to the Department of Anatomy, Faculty of Medicine, Khon Kaen University, and their families for granting permission for cadaver dissection. I would like to thank Professor Yukifumi Nawa for critical reading this manuscript.

References

- ANNE, N., PALLAPOTHU, R., HOLMES, R. and JOHNSON, MD. Inferior vena cava duplication and deep venous thrombosis: case report and review of literature. *Annals of Vascular Surgery*, 2005, vol. 19, n. 5, p. 740-743. PMID:16034513.
- BASS, JE., REDWINE, MD., KRAMER, LA., HUYNH, PT. and HARRIS, JH Jr. Spectrum of congenital anomalies of the inferior vena cava: cross-sectional imaging findings. *Radiographics*, 2000, vol. 20, n. 3, p. 639-652. PMID:10835118.
- BONJER, HJ., SORM, V., BERENDS, FJ., KAZEMIER, G., STEYERBERG, EW., DE HERDER, WW. and BRUINING, HA. Lessons learned from 111 consecutive cases. *Annals of Surgery*, 2000, vol. 232, n. 6, p. 796-803. PMID:11088074.
- CHEN, H., EMURA, S., NAGASAKI, S. and KUBO, K. Double inferior vena cava with interiliac vein: a case report and literature review. *Okajimas Folia Anatomica Japonica*, 2012, vol. 88, n. 4, p. 147-151. PMID:22645906.
- DAUNT, N. Adrenal vein sampling: how to make it quick, easy, and successful. *Radiographics*, 2005, vol. 25, suppl. 1, p. 143-158. PMID:16227488.
- GAY, SB., ARMISTEAD, JP., WEBER, ME. and WILLIAMSON, BR. Left infrarenal region: anatomic variants, pathologic conditions, and diagnostic pitfalls. *Radiographics*, 1991, vol. 11, n. 4, p. 549-570. PMID:1887111.
- INAMASU, J. and GUIOT, BH. Laparoscopic anterior lumbar interbody fusion: a review of outcome studies. *Minimally Invasive Neurosurgery*, 2005, vol. 48, n. 6, p. 340-347. PMID:16432783.
- ITOH, M., MORIYAMA, H., TOKUNAGA, Y., MIYAMOTO, K., NAGATA, W., SATRIOTOMO, I., SHIMADA, K. and TAKEUCHI, Y. Embryological consideration of drainage of the left testicular vein into the ipsilateral renal vein. *International Journal of Andrology*, 2001, vol. 24, p. 142-152. PMID:11380703.
- KAPETANAKIS, S., PAPADOPOULOS, C., GALANI, P., DIMITRAKOPOULOU, G. and FISKA, A. Anomalies of the inferior vena cava: a report of two cases and a short review of the literature. *Folia Morphologica*, 2010, vol. 69, n. 3, p. 123-127. PMID:21154280.
- KENNEALEY, PT., SAIDI, RF., MARKMANN, JF., KO, DCC., KAWAI, T. and YEY, H. Duplicated inferior vena cava - something to consider in the evaluation of a living donor renal transplant. *Dialysis & Transplantation*, 2009, vol. 38, n. 10, p. 420-422.
- KHAMANARONG, K., SAWATPANICH, T. and CHAICHUN, A. Double left suprarenal vein and its clinical implication. *Srinagarind Medical Journal*, 2015, vol. 30, n. 5, p. 90.
- KLIMBERG, I. and WAJSMAN, Z. Duplicated inferior vena cava simulating retroperitoneal lymphadenopathy in a patient with embryonal cell carcinoma of the testicle. *The Journal of Urology*, 1986, vol. 136, n. 3, p. 678-679. PMID:3735548.
- KOUROUKIS, C. and LECLERC, JR. Pulmonary embolism with duplicated inferior vena cava. *Chest*, 1996, vol. 109, n. 4, p. 1111-1113. PMID:8635342.
- MATHEWS, R., SMITH, PA., FISHMAN, EK. and MARSHALL, FF. Anomalies of the inferior vena cava and renal veins: embryologic and surgical consideration. *Urology*, 1999, vol. 53, n. 5, p. 873-880. PMID:10223477.
- MAYO, J., GRAY, R., ST LOUIS, E., GROSMAN, H., MCLOUGHLIN, M. and WISE, D. Anomalies of the inferior vena cava. *American Journal of Roentgenology*, 1983, vol. 140, n. 2, p. 339-345. PMID:6336872.
- MOORE, KL., PERSAUD, TVN. and TORCHIA, MG. *The developing human clinically oriented embryology*. 9th ed. Canada: Elsevier Saunders, 2013. p. 292-514.
- NAYAK, BS., RAO, KGM., SHETTY, SD., SIRASANAGANDLA, SR., KUMAR, N. and GURU, A. Terminal bifurcation of the right testicular vein and left testicular arterio-venous anastomosis. *Kathmandu University Medical Journal*, 2013, vol. 11, n. 42, p. 168-170. PMID:24096228.
- NG, WT. and NG, SS. Double inferior vena cava: a report of three cases. *Singapore Medical Journal*, 2009, vol. 50, n. 6, p. e211-e213. PMID:19551299.
- OERTEL, O. Teilwaiser fortbestand der unteren cardinalvenen beieinem erwachsenen. *Anatomischer Anzeiger*, 1928, vol. 65, p. 312-314.
- OZTURK, NC., UZMANSEL, D., KARA, A. and OZTURK, H. Variation in the position, relation and vasculature of left suprarenal gland: a case report. *Surgical and Radiologic Anatomy*, 2010, vol. 32, n. 10, p. 985-988. PMID:20162417.
- RADERMECKER, MA., VAN DAMME, H., KERZMANN, A., CREEMERS, E. and LIMET, R. Association of abdominal aortic aneurysm, horseshoe kidneys, and left-sided inferior vena cava: report of two cases. *Journal of Vascular Surgery*, 2008, vol. 47, n. 3, p. 645-648. PMID:18295119.
- SÈBE, P., PEYROMAURE, M., RAYNAUD, A. and DELMAS, V. Anatomical variations in the drainage of the principal adrenal veins: the results of 88 venograms. *Surgical and Radiologic Anatomy*, 2002, vol. 24, n. 3-4, p. 222-225. PMID:12375078.
- STACK, SP., ROSCH, J., COOK, DM., SHEPPARD, BC. and KELLER, FS. Anomalous left adrenal venous drainage directly into the inferior vena cava. *Journal of Vascular and Interventional Radiology*, 2001, vol. 12, n. 3, p. 385-387. PMID:11287520.
- SUZUKI, K., USHIYAMA, T., IHARA, H., KAGEYAMA, S., MUGIYA, S. and FUJITA, K. Complication of laparoscopic adrenalectomy in 75 patients treated by the same surgeon. *European Urology*, 1999, vol. 36, p. 40-47. PMID:10364654.
- TAKAGI, T., NOZAKA, Y. and OHSAWA, T. Double superior venae cavae with bilateral inferior vena cavae. *Acta Anatomica Nipponica*, 1982, vol. 57, n. 1, p. 9-14. PMID:7090729.
- TUBBS, RS., SALTER, ES. and OAKES, WJ. Unusual drainage of the testicular veins. *Clinical Anatomy*, 2005, vol. 18, n. 7, p. 536-539. PMID:16015633.

Received September 13, 2016

Accepted October 14, 2017