

Destructive effects of 4-methylimidazole on histomorphology of liver

YADAV, S.¹, KALRA, S.^{2*} and WADHWA, S.³

¹Department of Anatomy, Pt. B D Sharma PGIMS, Rohtak, India

²Department of Anatomy, University College of Medical Sciences, Delhi-110095, India

³Department of Anatomy, Maulana Azad Medical College, Delhi-110095, India

*E-mail: net31aug@yahoo.co.in

Abstract

Background & aims: Food coloring is being done commercially in the food products industry these days which include large number of food dyes including caramel colors. 4-Methylimidazole (4-MEI) is a component of various caramel colored food products such as bakery products, beer, soy sauces, gravy, colas and other soft drinks which are consumed daily. Humans can be exposed to 4-MEI by ingestion, inhalation and dermal contact. Ingestion is the most common route of exposure. **Methods:** The present study was conducted to evaluate the effects of 4-MEI consumption on liver in albino rats. Adult male Wistar albino rats weighing 150-200 grams were procured for the study and were divided into control and experimental groups. The experimental animals were given 4-MEI orally by gavage at a dose of 250mg/kg body weight daily for a period of one month while the control animals received distilled water. The animals were euthanized under ether anesthesia at the end of experiment within 24 hours of last dose by perfusion with formal saline. The liver was dissected out and processed for histopathological examination. **Results:** The histopathological observations of liver in experimental rats showed features of focal hepatocellular degeneration with mononuclear cell infiltration, kupffer cell hyperplasia, increased polyploidy and hepatocytic vacuolation. The findings in the present study strongly suggest hepatocellular damage caused by ingestion of 4-methylimidazole which is found in caramel colorants used routinely in food industry.

Keywords: caramel, 4-methylimidazole, hepatic damage.

1 Introduction

In this day and age, food coloring is being done on a very large scale in the food industry. Food colors or color additives impart color when added to food or drink. Commercially, a large number of food dyes are being used including caramel colors, turmeric, cochineal, chlorophyllin, saffron, annatto, betanin, paprika and lycopene etc (PETRUCI, PEREIRA and CARDOSO, 2013). One of the most widely used food color is caramel which is added to impart color to colas, soy sauces, seasonings, breads, grilled meat, coffee, roasted foods, pet foods, cereals and beverages (PETRUCI, PEREIRA and CARDOSO, 2013; KAMUF, NIXON, PARKER et al., 2003; CHAN, 2004). 4-Methylimidazole (4-MEI) (chemical formula: $H_3C-C_3H_3N_2$ or $C_4H_6N_2$) is nitrogen containing heterocyclic compound which is formed through the mallard reaction between carbohydrates and ammonia containing compounds. Thermolysis or fermentation of natural products such as caramel colors and soy sauces may also lead to production of this compound (KAMUF, NIXON, PARKER et al., 2003). It is even found in ammoniated hay forage used for livestock (WEISS, CONRAD, MARTIN et al., 1986; PERDOK and LENG, 1987). 4-MEI exposure is a matter of concern in human as well as veterinary toxicology (CHAN, 2004). Despite the widespread human exposure to foods containing 4-MEI and controversy regarding its carcinogenic potential, there is paucity of literature on its histopathological effects on liver. Hence the present study was designed to evaluate the histomorphological changes on liver in albino rats.

2 Materials and Methods

The study was conducted on adult male Wistar albino rats weighing 150-200 grams procured from the animal house of a medical college after obtaining approval from the ethical committee. Animals were given 4-MEI by oral route because ingestion is the most common route for human exposure. The chemical (4-MEI) was obtained from sigma pharmaceuticals (99% pure) in powder form, was kept in the refrigerator, away from light and moisture. The solution was prepared everyday by dissolving in distilled water. All the animals were group housed (12 hour light/dark cycle) with adequate access to food and water.

Animals were divided into two groups:

- 1) Experimental group: consisting of six animals and received 250mg/kg body weight of 4-MEI daily, dissolved in distilled water orally by gavage tube for 30 days;
- 2) Control group: consisting of six animals in which the equal amount of distilled water was given orally for the same period.

Animals were sacrificed under ether anesthesia at the end of experiment within twenty four hours of last dose by perfusion with formal saline till the animals became pale and stiff. The perfused rats were kept in formalin for 7 days. The liver was then carefully dissected out and observed for gross changes. The liver was cut into small pieces of 5mm for further processing. Tissues were put in a tissue capsule and were well washed in running tap

water for one hour to remove surplus fixative and then placed for dehydration in ascending grades of alcohol. Clearing of tissue was done by placing the dehydrated tissues in chloroform. Tissue was then embedded in paraffin wax and blocks were prepared. Eight micron thick sections were cut using a rotary microtome. Sections were picked up by the floatation method on a glass slide smeared with egg albumin, glycerin and thymol mixture. The sections were stained with: 1. Haematoxylin and eosin, 2. Periodic acid-Schiff (PAS) reaction and 3. Masson's trichrome

The various characteristics of the liver parenchyma and stroma regarding the architecture of hepatic lobule, shape and size of hepatocytes, sinusoidal lining, phagocytic and inflammatory cells infiltration, distribution of connective tissue content and PAS positive substances were studied under microscope with the help of different stains in both the experimental and control groups.

3 Results

3.1 Control group

In the control group, liver parenchyma comprised of hepatocytes arranged in one cell thick cords supported by connective tissue (Figure 1). The hepatic lobules were hexagonal in shape, bounded by loose connective tissue and consisted of hepatic cords along with sinusoids radiating from the central vein. Variable numbers of portal triad were seen at the angles of hepatic lobule. The hepatocytes appeared polyhedral in shape with a centrally placed euchromatic rounded nucleus and prominent nucleolus. Few hepatocytes were bi-nucleated. The cytoplasm of hepatocytes appeared vacuolated and stained pink with eosin. Hepatocytic vacuolation was because of presence of glycogen granules and lipids, which were not stained during haematoxylin and eosin staining.

The connective tissue was stained blue, cytoplasm was stained red while the nucleus was stained black with Masson's trichrome. PAS staining revealed magenta colored glycogen granules in the cytoplasm while the nucleus stained blue.

3.2 Experimental group

The orderly arrangement of the hepatocytic plates was disrupted at many places in 50% of the experimental rats (Figure 2). The hepatocytes were of variable size and not properly adherent to each other. Also, there were foci of degenerated hepatocytes which were seen as dark eosinophilic bodies with pyknotic nuclei when stained with haematoxylin and eosin (Figure 3). Majority of hepatocytes were highly vacuolated (66% of experimental rats) with central heterochromatic nucleus (Figure 2). In some hepatocytes nucleus was shifted to periphery giving signet ring appearance of cells (Figure 4). The cytoplasm of vacuolated hepatocytes gave empty appearance even when stained with PAS reaction and little PAS positive granularity was seen suggesting either excessive fat droplets or ballooning degeneration of hepatocytes (Figure 2). The numbers of bi-nucleated hepatocytes were noticeably increased. There were foci of inflammatory cells including macrophages and lymphocytes in between hepatocytes, around central vein as well as near portal triad in 50% of the experimental group which was not seen in the control rats (Figure 5). The sinusoids were present between the cords of hepatocytes and lined by endothelial cells. The kupffer cells were present in the lining as well as lumen of sinusoids. These cells were identified by their large irregular shape and dark flattened nucleus. There was appreciable dilatation of sinusoids and increase in the number of kupffer cells around the areas of hepatocellular degeneration and mononuclear infiltration (Figure 6).

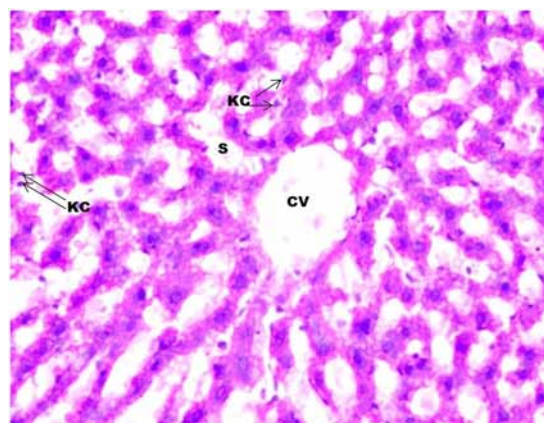


Figure 1. Photomicrograph of transverse section of liver of control rat at 200X magnification showing few kupffer cells in the sinusoids. CV (central vein); S (sinusoids); KC (kupffer cells).

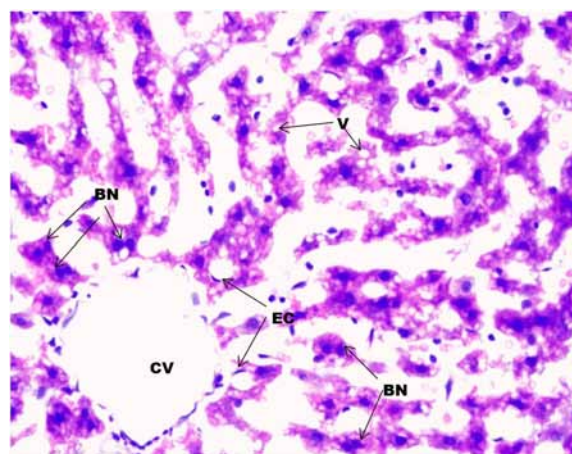


Figure 2. Photomicrograph of transverse section of liver of experimental rat at 200X magnification showing disruption of cords of hepatocytes and vacuolated cells. V (vacuolated hepatocytes); BN (binucleated cells); CV (central vein); EC (endothelial cells).

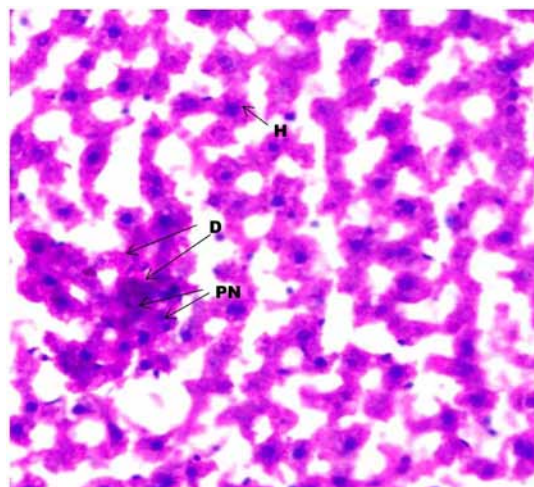


Figure 3. Photomicrograph of transverse section of liver of experimental rat at 200X magnification showing area of hyper-eosinophilic degenerating hepatocytes surrounded by healthy parenchyma. D (degenerating hepatocytes); H (normal hepatocytes); PN (pyknotic nuclei).

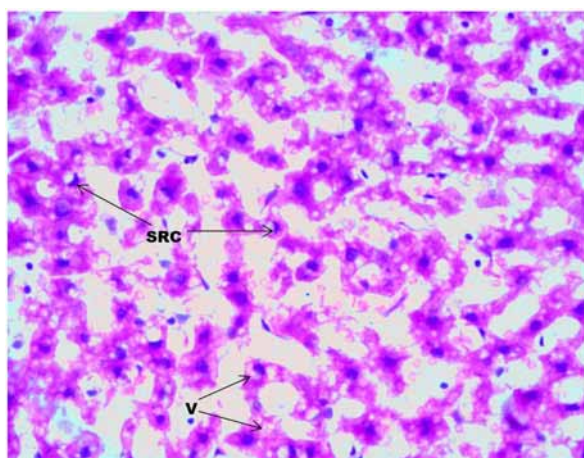


Figure 4. Photomicrograph of transverse section of liver of experimental rat at 200X magnification showing disruption of cords of hepatocytes and vacuolated cells along with signet ring appearance of few hepatocytes. SRC (signet ring cells); V (vacuolated hepatocytes).

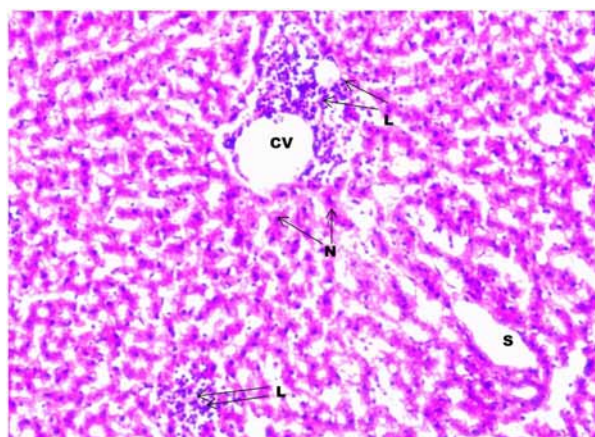


Figure 5. Photomicrograph of transverse section of liver of experimental rat at 100X magnification showing area of lymphocytic infiltration around central vein and in the sinusoids. S (sinusoids); L (lymphocytes); CV (central vein); N (nuclei of hepatocytes).

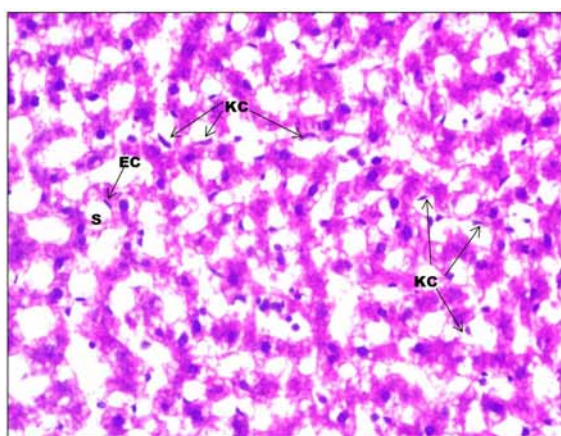


Figure 6. Photomicrograph of transverse section of liver of experimental rat at 200X magnification showing numerous kupffer cells in the sinusoids. S (sinusoids); KC (kupffer cells); EC (endothelial cells).

The connective tissue capsule was stained with haematoxylin and eosin, Masson's trichrome and PAS reaction. The capsule was uniformly thick and no difference was noticed in both the groups. There was no apparent difference in the amount of connective tissue around portal triad in both the groups.

4 Discussion

Consumption of food products in daily life includes many caramel colored foods which contain the chemical 4-MEI. Caramel color is produced by the controlled heat treatment of carbohydrates in presence of ammonium compounds. Ingestion is the most common route of exposure to 4-MEI and liver is the target organ of toxicity (CHAN, HILL, KISSLING et al., 2008). Our study evaluated the effects of exposure to this compound at daily oral dose of 250mg/kg bw for a period of 30 days on liver in Wistar albino rats and significant histomorphological changes in liver of experimental rats were observed.

In the present study, orderly arrangement of the hepatocytic plates was disrupted at many places. The hepatocytes appeared to be of variable size and were not properly adherent to each other. Focal areas of hepatocellular degeneration characterized by dark eosinophilic cytoplasm and small pyknotic nuclei were observed. These areas were infiltrated by lymphocytic cells and also accompanied by increase in kupffer cells. Also, the lymphocytic infiltration involved the areas around portal triad and central vein. Focal degeneration of liver parenchyma and polyploidy in our study could be explained on the basis of direct cytopathic injury along with excessive activity and incapability of the cells in order to get rid of 4-MEI, the toxic substance (MONFARED, 2013). In the studies done by other authors, they observed that 4-MEI exposure leads to hepatic histiocytosis and chronic inflammation of hepatic parenchyma, however in paradoxical to our they did not detect on kupffer cell reactivity and disruption of cords of hepatocytes (CHAN, HILL, KISSLING et al., 2008). Similar findings of hepatic necrosis, lymphocytic infiltration and kupffer cell hyperplasia were reported by other authors after exposure to cyclophosphamide and lindane, consumption of cyprinid fish and rhubarb as well as hepatitis B and C infections (BRAUNBECK, GÖRGE, STORCH et al., 1990; SHOKRZADEH, CHABRA, AHMADI et al., 2014; ASAKAWA and NOGUCHI, 2014; WANG, KONG, WANG et al., 2011; STANCULET, GRIGORAS, AVADANEI et al., 2013). It was even stated that statistically significant increase in the number of kupffer cells was associated with the degree of necro inflammatory activity as well as the degree of fibrosis in liver. The infiltration by neutrophils and lymphocytes observed in the current study indicates acute dysfunction of liver as suggested by other authors (ASAKAWA and NOGUCHI, 2014). Lymphocytic infiltration around central vein and portal triad observed in the present study were also observed after exposure to carbaryl (MUNGLANG, NAGAR and PRAKASH, 2009). Hence areas of mononuclear cellular infiltration accompanied by hepatic degeneration and kupffer cell hyperplasia in our study suggest inflammation of liver parenchyma and hepatic damage by 4-MEI exposure. In our study in some of the liver sections of experimental animals, bi-nucleated cells appeared to be increased around areas of lymphocytic infiltration and hepatocellular injury. Presence of such bi-nucleated cells in the tissues may be a protective mechanism against

toxic effects of any noxious stimuli to genetic makeup of cells as also hypothesized by other researchers (GENTRIC, DESDOUETS and CELTON-MORIZUR, 2012). Hepatic mitosis can be explained as attempts of regeneration and it has also been reported on exposure to after exposure to lindane and carbaryl in previous studies (SHOKRZADEH, CHABRA, AHMADI et al., 2014). The polyploidy of cells can also occur in response to injury by toxins, chronic inflammation, partial hepatectomy, oxidative stress and increased metabolic activity (GENTRIC, DESDOUETS and CELTON-MORIZUR, 2012). In our study, the presence of bi-nucleated cells could be a consequence of hepatocellular injury to compensate for the loss of hepatic parenchyma as well as excessive metabolic activity to get rid of the toxic agent which was 4-MEI. In the present study, there was presence of intense hepatocytic vacuolation along with signet ring appearance of hepatocytes in liver sections of some experimental rats. In the study done on cultured mammalian cells, vacuolation in cells has been explained as an adaptive physiological response in order to limit the damage by any noxious stimulus (WELLS, WEISBRODE, MAURER et al., 1988). Cellular vacuolation has also been associated with intracellular deposition of glycogen, exposure to various drugs and toxins including procaine hydrochloride, carbon tetrachloride, chloroquine, ammonia, glycerol, urea, adenine and insecticides (HENICS and WHEATLEY, 1999). Vacuolation of cells can also be a part of degeneration process such as in hydropic degeneration. The presence of hepatocytic vacuolation in our study could be a consequence of sequestration of lipids or ballooning degeneration of hepatocytes as a result of toxic injury by 4-MEI. The distribution of PAS positive substances and connective tissue distribution in liver sections of experimental rats was similar to that of control rats.

In the current study, the histopathological observations of liver in experimental rats showed features of focal hepatocellular degeneration with mononuclear cell infiltration and kupffer cell hyperplasia. Hepatocytic vacuolation was also observed in many sections of liver in 4-MEI exposed rats. Apart from the site of hepatocellular injury, lymphocytic infiltration was also present sporadically around the portal triad and in between the hepatocytes. These findings are suggestive of inflammatory and degenerative changes of hepatic parenchyma on regular consumption of 4-MEI in albino rats, therefore rational use of caramel colored foods should be considered in daily life.

References

- ASAKAWA, M. and NOGUCHI, T. Food poisonings by ingestion of cyprinid fish. *Toxins*, 2014, vol. 6, n. 2, p. 539-555. PMID:24476713. <http://dx.doi.org/10.3390/toxins6020539>.
- BRAUNBECK, T., GÖRGE, G., STORCH, V. and NAGEL, R. Hepatic steatosis in zebra fish (*Brachydanio rerio*) induced by long-term exposure to gamma-hexachlorocyclohexane. *Ecotoxicology and Environmental Safety*, 1990, vol. 19, n. 3, p. 355-374. PMID:1694756. [http://dx.doi.org/10.1016/0147-6513\(90\)90036-5](http://dx.doi.org/10.1016/0147-6513(90)90036-5).
- CHAN PC. NTP technical report on the toxicity studies of 2-and 4-methylimidazole (CAS No. 693-98-1 and 822-36-6) administered in feed to F344/N rats and B6C3F1 mice. *Toxicity Report Series*. 2004;(67):1-G12.
- CHAN, PC., HILL, GD., KISSLING, GE. and NYSKA, A. Toxicity and carcinogenicity studies of 4-methylimidazole in F344/n rats and B6c3f1 mice. *Archives of Toxicology*, 2008, vol. 82, n. 1, p. 45-53. PMID:17619857. <http://dx.doi.org/10.1007/s00204-007-0222-5>.
- GENTRIC G, DESDOUETS C, CELTON-MORIZUR S. Hepatocytes polyploidization and cell cycle control in liver physiopathology. *International Journal of Hepatology*. 2012;2012:1-8. <http://dx.doi.org/10.1155/2012/282430>.
- HENICS, T. and WHEATLEY, DN. Cytoplasmic vacuolation, adaptation and cell death: a view on new perspectives and features. *Biology of the Cell*, 1999, vol. 91, n. 7, p. 485-498. PMID:10572624. [http://dx.doi.org/10.1016/S0248-4900\(00\)88205-2](http://dx.doi.org/10.1016/S0248-4900(00)88205-2).
- KAMUF, W., NIXON, A., PARKER, O. and BARNUM JUNIOR, GC. Overview of caramel colors. *Cereal Foods World*, 2003, vol. 48, n. 2, p. 64-69.
- MONFARED AL Biochemical and histomorphometric studies on the liver rats administrated with glycyrrhizaglabra extracts. *Avian Biology Research*, 2013, vol. 7, n. 2, p. 67-71. <http://dx.doi.org/10.5829/idosi.abr.2013.7.2.1105>.
- MUNGLANG, M., NAGAR, M. and PRAKASH, R. Liver in carbaryl treated rats- a morphological and morphometric study. *Journal of the Anatomical Society of India*, 2009, vol. 58, n. 1, p. 6-9.
- PERDOK, HB. and LENG, RA. Hyperexcitability in cattle fed ammoniated roughages. *Animal Feed Science and Technology*, 1987, vol. 17, n. 2, p. 121-143. [http://dx.doi.org/10.1016/0377-8401\(87\)90009-5](http://dx.doi.org/10.1016/0377-8401(87)90009-5).
- PETRUCI, JF., PEREIRA, EA. and CARDOSO, AA. Determination of 2-methylimidazole and 4-methylimidazole in caramel colors by capillary electrophoresis. *Journal of Agricultural and Food Chemistry*, 2013, vol. 61, n. 9, p. 2263-2267. PMID:23379790. <http://dx.doi.org/10.1021/jf3048274>.
- SHOKRZADEH M, CHABRA A, AHMADI A, NAGHSHVAR F, HABIBI E, SALEHI F and ASSADPOUR S. Hepatoprotective effects of Zataria Multiflora ethanolic extract on liver toxicity Induced by cyclophosphamide in mice. *Drug Research*. 2014. PMID:24696425.
- STANCULEȚ, N., GRIGORAȘ, A., AVADANEI, R., FLOAREA-STRAT, A., AMALINEI, C. and CARUNTU ID. Relationship between kupffer cells, inflammation and fibrosis in chronic hepatitis B and C. *Revista medico-chirurgicală a Societății de Medici și Naturaliști din Iași*, 2013, vol. 117, n. 4, p. 880-889.
- WANG, JB., KONG, WJ., WANG, HJ., ZHAO, HP., XIAO, HY., DAI, CM., XIAO, XH., ZHAO, YL., JIN, C., ZHANG, L., FANG, F. and LI, RS. Toxic effects caused by rhubarb (*Rheum palmatum* L.) are reversed on immature and aged rats. *Journal of Ethnopharmacology*, 2011, vol. 134, n. 2, p. 216-220. PMID:21163343. <http://dx.doi.org/10.1016/j.jep.2010.12.008>.
- WEISS, WP., CONRAD, HR., MARTIN, CM., CROSS, RF. and SHOCKEY, WL. Etiology of ammoniated hay toxicosis. *Journal of Animal Science*, 1986, vol. 63, n. 2, p. 525-532. PMID:3759687. <http://dx.doi.org/10.2527/jas1986.632525x>.
- WELLS, MY., WEISBRODE, SE., MAURER, JK., CAPEN, CC. and BRUCE, RD. Variable hepatocellular vacuolization associated with glycogen in rabbits. *Toxicologic Pathology*, 1988, vol. 16, n. 3, p. 360-365. PMID:3194658. <http://dx.doi.org/10.1177/019262338801600307>.

Received February 13, 2017

Accepted September 29, 2017