

References

1. Calonje E, Fletcher CD, Wilson-Jones E, et al. Retiform hemangioendothelioma: a distinctive form of low-grade angiosarcoma delineated in a series of 15 cases. *Am J Surg Pathol* 1994;18:115-25.
2. Hirsh AZ, Yan W, Wei L, et al. Unresectable retiform hemangioendothelioma treated with external beam radiation therapy and chemotherapy: a case report and review of the literature. *Sarcoma* 2010;2010:756246. <http://dx.doi.org/10.1155/2010/756246>.
3. Tan D, Kraybill W, Cheney RT, et al. Retiform hemangioendothelioma: a case report and review of the literature. *J Cutan Pathol* 2005;32:634-7.
4. Zhang G, Lu Q, Yin H, et al. A case of retiform-hemangioendothelioma with unusual presentation and aggressive clinical features. *Int J Clin Exp Pathol* 2010;3:528-33.
5. Bhutoria B, Konar A, Chakrabarti S, et al. Retiform hemangioendothelioma with lymph node metastasis: a rare entity. *Indian J Dermatol Venereol Leprol* 2009;75:60-2.

Xanthogranuloma in Adolescence

Seong Oh Park¹, Eui Cheol Jeong², Ji Ung Park², Suk Wha Kim¹

¹Department of Plastic and Reconstructive Surgery, Seoul National University Hospital, Seoul;

²Department of Plastic and Reconstructive Surgery, SMG-SNU Boramae Medical Center, Seoul, Korea

Correspondence: Eui Cheol Jeong

Department of Plastic and Reconstructive Surgery, SMG-SNU Boramae Medical Center, 20 Boramae-ro 5-gil, Dongjak-gu, Seoul 156-707, Korea
Tel: +82-2-870-2331, Fax: +82-2-831-2826, E-mail: ajeong.md@gmail.com

This article was presented as a poster at the 69th Congress of the Korean Society of Plastic and Reconstructive Surgeons on November 11-13, 2011 in Seoul, Korea.

No potential conflict of interest relevant to this article was reported.

Received: 11 Jul 2011 • Revised: 22 Aug 2011 • Accepted: 25 Aug 2011
pISSN: 2234-6163 • eISSN: 2234-6171
<http://dx.doi.org/10.5999/aps.2012.39.1.82> • Arch Plast Surg 2012;39:82-84

Copyright © 2012 The Korean Society of Plastic and Reconstructive Surgeons
This is an Open Access article distributed under the terms of the Creative Commons Attribution Non-Commercial License (<http://creativecommons.org/licenses/by-nc/3.0/>) which permits unrestricted non-commercial use, distribution, and reproduction in any medium, provided the original work is properly cited.

Xanthogranuloma is a benign, self-limiting disease caused by proliferation of cutaneous histiocytes. It is predominantly a disease of infancy or early childhood. Lesions generally develop on the head, neck, and upper extremities and present in various sizes and numbers. Typically, they disappear in 5-6 years and do not require specific treatment [1]. Here, we report one case of adolescent xanthogranuloma on the nasal tip because xanthogranuloma is rare in adolescence.

A 14-year-old, male adolescent visited our dermatologic clinic for a mass-like lesion on the nose. This lesion had been developing for the past 2 months. The lesion was a circular, protruded papule with a diameter of 1 cm (Fig. 1). The size of the lesion had gradually increased. There was no remarkable past medical or family history. A dermatologist performed the punch biopsy. The result of the biopsy was chronic active inflammation with granulation tissue formation, foreign body type-multinucleated giant cells, and a granulomatoid appearance. The dermatologist

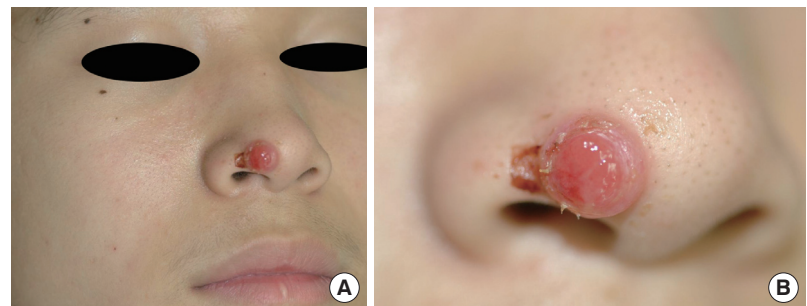
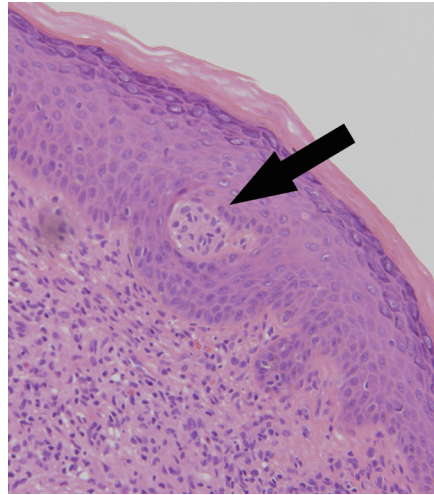


Fig. 1.

Photograph of initial state of the mass (A). The lesion was a circular, protruded papule on the nasal tip, with a diameter of 1 cm (B). Close-up photograph.

Fig. 2. Light micrographs of excised mass. The hematoxylin and eosin-stained section is a mixture of cytologically intense infiltration of histiocytes, lymphocytes, and multinucleated giant cells in the dermis. Touton giant cell (black arrow) (H&E, $\times 400$).



injected triamcinolone to the lesion twice but it had no effect. The patient was sent to the department of plastic surgery for surgical excision. For accurate diagnosis, we performed a shave biopsy with a #15 blade. Histopathological findings were consistent with the diagnosis of xanthogranuloma. The dermis was infiltrated by a mixed population of lymphocytes, foamy macrophages (xanthoma cells), and scattered Touton giant cells (multinucleated giant cells) (Fig. 2).

Xanthogranuloma is a self-limiting disease in most cases. Therefore, we decided to observe the patient regularly every 2 months in the outpatient clinic instead of performing an invasive surgical procedure such as a total excision. We sent the patient to a

Fig. 3. Photograph 5 months after the mass first developed. It had totally regressed and only a scarlet lesion remained.

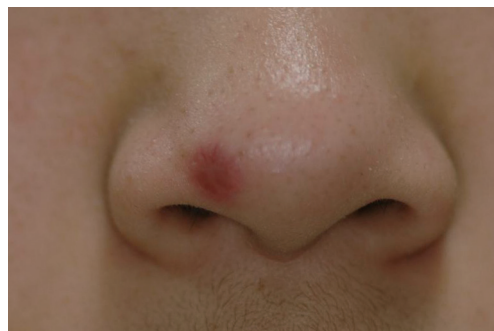
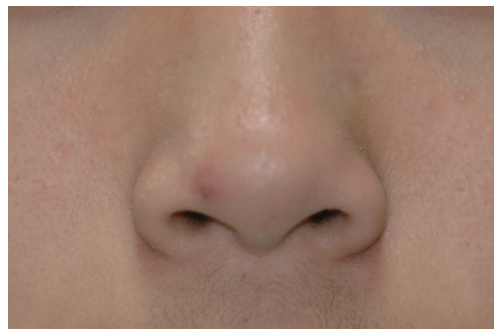
Fig. 4. Photograph at 11 months. It had almost totally healed, with only a small, postinflammatory hyperpigmented lesion remaining.



hematologist for the possibility of paraproteinemia and an ophthalmologist for the possibility of optic lesions. There were no abnormal findings. The lesion regressed slowly. Total regression with only a remnant scarlet lesion was observed at 5 months after mass development (Fig. 3). At 11 months, the lesion had totally healed and only a small, postinflammatory hyperpigmentation remained (Fig. 4).

The first case of xanthogranuloma was reported in 1905 by Adamson, who termed the entity "congenital xanthoma multiplex". Xanthogranuloma shows a bimodal distribution with lesions occurring in early childhood or during the late twenties or early thirties in adults. The histopathology is identical in both age groups; however, in adults, there is no specific area of occurrence and it usually presents as a single, asymmetrical lesion. Xanthogranuloma usually shows a higher male prevalence, although this may be variable according to the location of the lesion and age of the patient [2].

The pathophysiology of xanthogranuloma is not well understood. In previous reports, dermal dendrocytes were proposed as the cell of origin of xanthogranuloma. A recent report, however, suggested that plasmacytoid monocytes be considered the cell of origin of xanthogranuloma [3]. Nevertheless, these hypotheses have limitations in explaining the clinical features of xanthogranuloma, which usually develops in infants or children. Involvement of internal organs and tissues such as the lungs, bones, urogenital tract, gastrointestinal tract, pericardium, and orbit has been reported in about 20% of patients. Therefore, we sent the patient to a hematologist and an ophthalmologist.

In Korea, there are about fifteen reported cases of xanthogranuloma presenting in adults. Only two cases have been reported in adolescence. Adult xanthogranuloma shows a different clinical course from juvenile xanthogranuloma. Typically, it presents as a single persistent lesion in contrast to the juvenile type. It is difficult to predict a general tendency of xanthogranuloma in adolescence because it is rare. However, Hong and colleagues followed multiple xanthogranulomas in adolescence for 2 years. They found that the lesions regressed spontaneously [4].

Histologic analysis is essential for diagnosis of xanthogranuloma. The most characteristic finding is dermal infiltration by a mixed population of lymphocytes, foamy macrophages, and scattered Touton giant cells. The proportion of lymphocytes, foamy macrophages, and Touton giant cells varied from case to case. Immunohistochemistry can be helpful when

differential diagnosis is needed. Kraus et al. [3] examined 27 cases of xanthogranuloma. The mononuclear and xanthoma cells and most of the Touton cells exhibited reactivity for fascin and CD68, although 26 of 27 were reactive for HLA-DR, 25 of 27 for factor XIIIa, 25 of 27 for CD45, and 21 of 27 for CD4. None of the cases showed reactivity for CD1a, CD3, CD21, CD34, or CD35 [3].

When the patient visited our clinic, we performed shave biopsy because we needed a more accurate diagnosis. Without an accurate diagnosis of xanthogranuloma, there is a greater chance of surgical excision. If surgical excision was performed, the patient would be left with a surgical scar and distortion of the nasal tip. Punch biopsy is very commonly used in the initial assessment of suspicious cutaneous lesions. Punch biopsy, however, is limited in diameter. It may not encompass the entire periphery of the lesion, preventing the pathologist from being able to assess key pathologic features such as symmetry, overall size, and circumscription. This partial sampling can lead to misdiagnosis. The most significant aesthetic problem of such a cutaneous mass is protrusion. Shave biopsy provides the advantage of partial removal without any extension of the lesion [5]. Therefore, we prefer shave biopsy over punch biopsy.

In conclusion, the clinical diagnosis of typical xanthogranuloma is easily made. However, as our case shows, xanthogranuloma can occasionally develop in an unexpected age group such as adolescents. For an accurate diagnosis, a histopathological examination is mandatory. This case illustrates a rare case of xanthogranuloma in adolescence, which was diagnosed based on histological findings, while invasive surgery, with its accompanying aesthetic compromise, was avoided.

References

- Hernandez-Martin A, Baselga E, Drolet BA, et al. Juvenile xanthogranuloma. *J Am Acad Dermatol* 1997;36:355-67.
- Dehner LP. Juvenile xanthogranulomas in the first two decades of life: a clinicopathologic study of 174 cases with cutaneous and extracutaneous manifestations. *Am J Surg Pathol* 2003;27:579-93.
- Kraus MD, Haley JC, Ruiz R, et al. "Juvenile" xanthogranuloma: an immunophenotypic study with a reappraisal of histogenesis. *Am J Dermatopathol* 2001;23:104-11.
- Hong SS, Ko GB, Ihm CW. A case of multiple xanthogranuloma in adolescent. *Korean J Dermatol* 2002;40:423-7.
- Zager JS, Hochwald SN, Marzban SS, et al. Shave biopsy is a safe and accurate method for the initial evaluation of melanoma. *J Am Coll Surg* 2011;212:454-60.

Desmoplastic Fibroblastoma of the Finger Tip in an Adult

Ji Hwan Kim, Deuk Young Oh, Sang Wha Kim, Jung Ho Lee, Sang Tae Ahn, Jong Won Rhie

Department of Plastic Surgery, Seoul St. Mary's Hospital, The Catholic University of Korea School of Medicine, Seoul, Korea

Correspondence: Deuk Young Oh
Department of Plastic Surgery, Seoul St. Mary's Hospital, The Catholic University of Korea School of Medicine, 222 Banpo-daero, Seocho-gu, Seoul 137-040, Korea
Tel: +82-2-2258-2840, Fax: +82-2-594-7230
E-mail: ohdeuk1234@hanmail.net

This article was presented as a poster at the 69th Congress of the Korean Society of Plastic and Reconstructive Surgeons on November 11-13, 2011 in Seoul, Korea.

This research was supported by Seoul St. Mary's Clinical Medicine Research Program year of 2009 through the Catholic University of Korea.

Received: 11 Aug 2011 • Revised: 21 Oct 2011 • Accepted: 31 Oct 2011
pISSN: 2234-6163 • eISSN: 2234-6171
<http://dx.doi.org/10.5999/aps.2012.39.1.84> • Arch Plast Surg 2012;39:84-86

Copyright © 2012 The Korean Society of Plastic and Reconstructive Surgeons
This is an Open Access article distributed under the terms of the Creative Commons Attribution Non-Commercial License (<http://creativecommons.org/licenses/by-nc/3.0/>) which permits unrestricted non-commercial use, distribution, and reproduction in any medium, provided the original work is properly cited.

Desmoplastic fibroblastoma is a rare neoplasm characterized by spindle- to satellite-shaped fibroblastic cells that are sparsely distributed in a collagenous stroma. It was first described in 1995 by Evans [1], who reported seven cases of morphologically distinct, benign, fibrous, soft tissue tumors and gave this specific tumor type its name.

Since the characterization of this tumor by Evans, fewer than 100 cases have been reported in the English literature. Only 7.9% of 63 cases of desmoplastic fibroblastoma in one analysis were hand lesions. Furthermore, there is only one report of a finger lesion, which developed in the volar aspect of the metacarpophalangeal joint of the left little finger [2].

Clinically, desmoplastic fibroblastoma manifests as a painless, slow-growing mass of more than six months duration. It usually appears between the ages 25 to 83 years in the neck, forearm, shoulder, thigh, or feet. Most have been treated by surgical excision and neither local recurrence nor metastasis has been reported [3]. This paper presents a rare case of desmoplastic fibroblastoma of a finger with the clinicopathologic and immunohistochemical findings.