

by ectopic deposition of mature adipose tissue in the collagen bundles of the dermis [1-4]. NLCS is classified into two subtypes: the multiple (classical) type and solitary type [1-3]. The multiple type usually appears within the first two decades of life, most commonly in the pelvic girdle region and consists of flesh-colored or yellow papules or nodules [3,4]. Also, its histopathological features are relatively uniform [3]. In contrast, the solitary type consists of a single nodular lesion without a favored location and it usually occurs in adults [3]. Surgical excision is a simple and adequate treatment for all lesions [2]. Recently, some authors have reported that CO₂ laser is useful method of treatment for NLCS, especially in the multiple type [4].

We report here a case of multiple type NLCS on the right lower back, which recurred after CO₂ laser treatment and was treated by staged surgical excisions. To the best of our knowledge, there have not been any cases of recurred NLCS after laser treatment in the literature.

A 13-year-old girl presented with asymptomatic, yellow-orange papules on the right lower back measuring 14 × 5 cm and composed of three clusters (Fig. 1). According to her parents, the skin masses had appeared at age 5 and gradually increased in number and size as she grew. However, there was no evidence of any systemic disease and no symptoms due to her back mass. Her family history was unremarkable, with a lack of similar skin lesions. Three years earlier, the patient had been treated with CO₂ laser at another clinic to avoid the inconvenience of removing her clothes. At that time, they had thought that the mass was treated well. However, a few months

Recurrence of Nevus Lipomatosus Cutaneus Superficialis after CO₂ Laser Treatment

Young Joon Kim, Jung Hun Choi, Hoon Kim,
Sang Hyun Nam, Young Woong Choi

Department of Plastic and Reconstructive Surgery, Sanggye Paik Hospital, Inje University College of Medicine, Seoul, Korea

Correspondence: Sang Hyun Nam
Department of Plastic and Reconstructive Surgery, Sanggye Paik Hospital, Inje University College of Medicine, 1342 Dongil-ro, Nowon-gu, Seoul 139-707, Korea
Tel: +82-2-950-1048, Fax: +82-2-932-6373
E-mail: nsh1103@paik.ac.kr

No potential conflict of interest relevant to this article was reported.

Received: 10 Apr 2012 • Revised: 1 Jun 2012 • Accepted: 2 Jun 2012
pISSN: 2234-6163 • eISSN: 2234-6171
<http://dx.doi.org/10.5999/aps.2012.39.6.671> • Arch Plast Surg 2012;39:671-673

Copyright © 2012 The Korean Society of Plastic and Reconstructive Surgeons
This is an Open Access article distributed under the terms of the Creative Commons Attribution Non-Commercial License (<http://creativecommons.org/licenses/by-nc/3.0/>) which permits unrestricted non-commercial use, distribution, and reproduction in any medium, provided the original work is properly cited.

Nevus lipomatosus cutaneus superficialis (NLCS) is a relatively rare benign malformation characterized

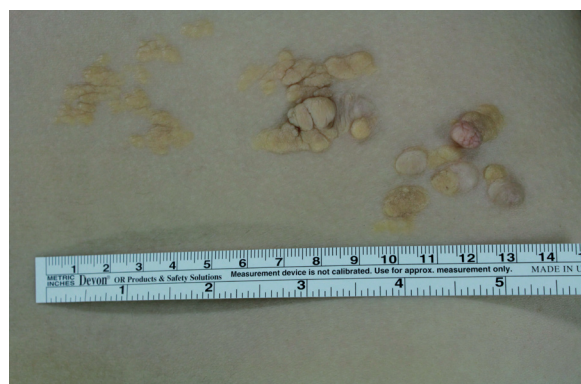

Fig. 1.

Clinical photograph of the case. A 14 × 4 cm nevus lipomatosus cutaneus superficialis lesion on the right flank. Initially, only the central cluster had been presented, but after CO₂ laser treatment, 2 more clusters were presented.

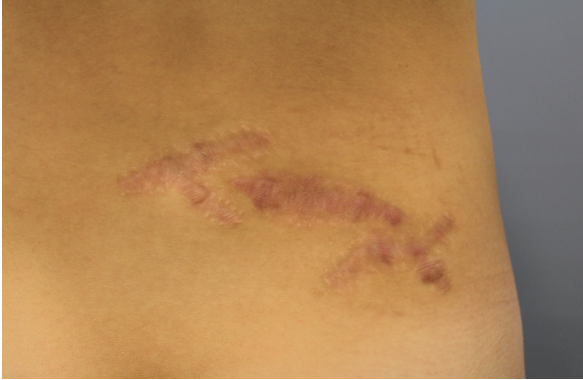

Fig. 2.

Photograph 6 months postoperatively. The lesion was completely excised and there were only wide scars remaining.

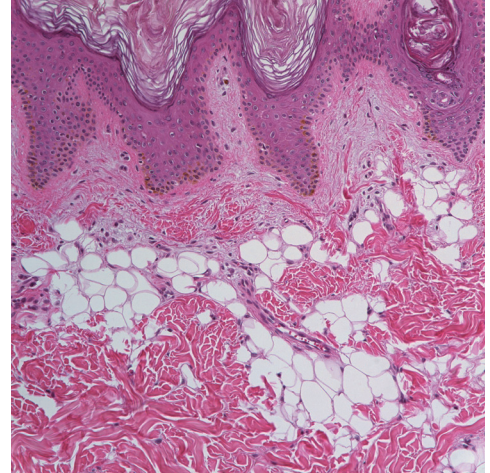


Fig. 3.

Histopathologic findings of the case. Lobules of mature fat are diffusely scattered between collagen fibers in the dermis. Fat lobules extending to reticular dermis are located around the capillaries (H&E, $\times 200$).

later, remarkably, the skin masses had recurred and increased in numbers and size very rapidly. On physical examination, there were multiple yellow-colored, non-tender, soft nodules coalescing into a plaque on her right lower back. Complete surgical excision was performed divided in three stages and covered with local advancement flaps (Fig. 2).

Histopathologically, lobules of the mature adipocytes were located between the collagen fibers in the entire dermis. Fat lobules extending to the reticular dermis were located around the capillaries. All of these findings coincide with NLCS (Fig. 3).

NLCS is a rare idiopathic benign malformation characterized by ectopic adipose tissue in the dermis [1-3]. Generally, there are no clinical symptoms during its course, although sometimes NLCS can appear with some symptoms [2]. Now NLCS is classified into two subtypes [1-3]. The multiple type usually appears within the first two decades of life, but occasionally it can have a later onset [3]. There is no sex or genetic predilection [3]. Usually the multiple type consists of grouped, flesh-colored or yellow papules or nodules on the pelvic girdle region in a segmental pattern that coalesce to form plaques [1,3,5]. The plaque surfaces are smooth, but sometimes they have a verrucous or cerebriform appearance [4,5]. In our case, the skin lesion appeared from age 5 on the right lower back, and there were no clinical symptoms from the NLCS. It presented typical characteristics of multiple type NLCS. The pathogenesis is still unknown and several theories have been proposed [4]. One

theory suggests that multiple type NLCS arises from adipose metaplasia in the course of degenerative changes in the dermal connective tissue [4]. Another theory is that the adipocytes represented a true nevus from the developmental displacement of adipose tissue [4]. A third proposal is that the mature adipocytes grow from mononuclear cells that were differentiating lipoblasts in a perivascular area [1].

The histopathology of NLCS usually shows clusters of ectopic mature adipose tissues among the collagen bundles in the dermis, and there is no connection to the subcutaneous fat tissue [1,2]. These ectopic adipocytes contain large intracytoplasmic lipid vacuoles, often associated with vascular structures [1,4].

Many authors have reported that treatment is not necessary in most cases, other than for cosmesis [2]. However, clinicians should be aware that sometimes the masses can become a larger tumor if untreated [5]. Simple surgical excision is sufficient for treatment without recurrence in almost cases [2]. However, if surgical excision is not adequate, recurrence is possible. Recently, some authors have reported that CO₂ laser treatment is effective for treating large lesions of multiple type NLCS without recurrence [4]. They argue that CO₂ laser treatment is somewhat better than surgical excision. Because multiple type NLCS usually involves a large area, sometimes it requires a skin graft. These skin grafts could cause unsatisfying cosmetic results, but the study reported that patients treated with CO₂ laser were pleased with the results [4]. The authors treated recurred multiple type NLCS

after CO₂ laser treatment with staged excisions and covered with local advancement flaps, but the patient was satisfied with the cosmetic results and there was no recurrence. Consequently, physicians should take note that insufficient treatment, including CO₂ laser or any surgical excision, can cause recurrence, as in this case. We suggest that staged excision can be another treatment modality for large multiple type NLCS.

References

1. Jones EW, Marks R, Pongsehirun D. Naevus superficialis lipomatosus. A clinicopathological report of twenty cases. *Br J Dermatol* 1975;93:121-33.
2. Hattori R, Kubo T, Yano K, et al. Nevus lipomatosus cutaneous superficialis of the clitoris. *Dermatol Surg* 2003;29:1071-2.
3. Kim KJ, Park BI, Kim YB, et al. Clinical experience of nevus lipomatosus cutaneous superficialis. *J Korean Soc Plast reconstr Surg* 1994;21:360-4.
4. Jung SJ, Kim HJ, Seo YJ, et al. A case of nevus lipomatosus cutaneous superficialis treated by CO₂ laser. *Korean J Dermatol* 2007;45:1093-5.
5. Knuttel R, Silver EA. A cerebriform mass on the right buttock. *Dermatol Surg* 2003;29:780-1.