

## IMAGES

**Angioleiomyoma of the Auricle**

Hyo-In Kim<sup>1</sup>, Si-Gyun Roh<sup>1</sup>, Nae-Ho Lee<sup>1</sup>,  
Kyung-Moo Yang<sup>1</sup>, Ho Sung Park<sup>2</sup>

Departments of <sup>1</sup>Plastic and Reconstructive Surgery and  
<sup>2</sup>Pathology, Chonbuk National University Medical School,  
Jeonju, Korea

**Correspondence:** Si-Gyun Roh  
Department of Plastic and Reconstructive Surgery, Chonbuk National  
University Medical School, 20 Geonji-ro, Deokjin-gu, Jeonju 561-712, Korea  
Tel: +82-63-250-1860, Fax: +82-63-250-1866  
E-mail: pssroh@jnu.ac.kr

No potential conflict of interest relevant to this article was reported.

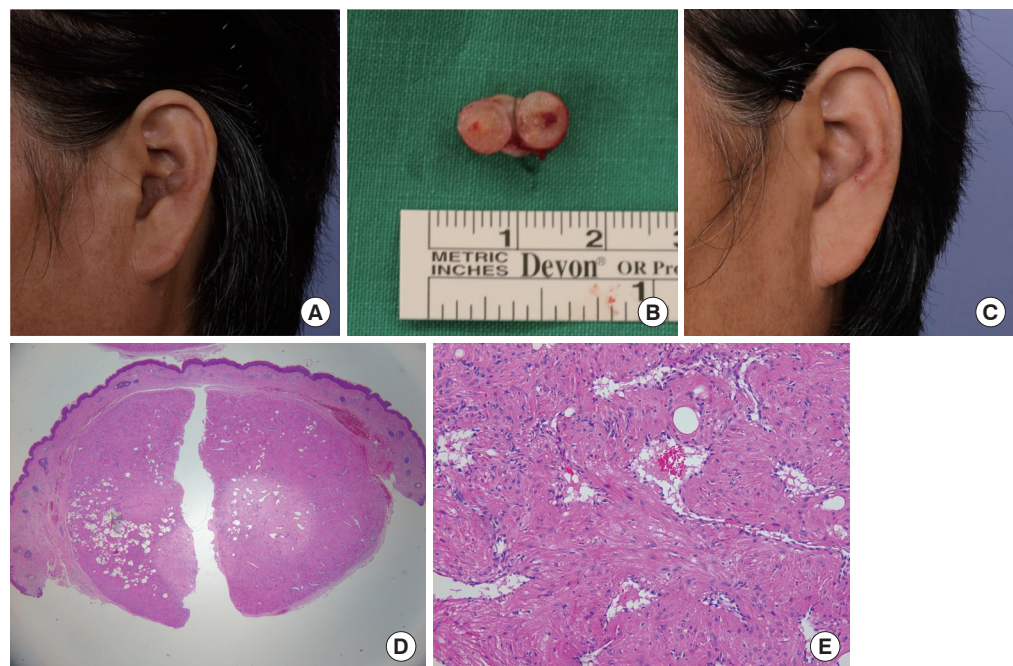
Received: 19 Sep 2012 • Revised: 22 Oct 2012 • Accepted: 2 Nov 2012  
pISSN: 2234-6163 • eISSN: 2234-6171  
<http://dx.doi.org/10.5999/aps.2013.40.1.68> • Arch Plast Surg 2013;40:68-69

Copyright © 2013 The Korean Society of Plastic and Reconstructive Surgeons  
This is an Open Access article distributed under the terms of the Creative Commons  
Attribution Non-Commercial License (<http://creativecommons.org/licenses/by-nc/3.0/>)  
which permits unrestricted non-commercial use, distribution, and reproduction in any  
medium, provided the original work is properly cited.

Angioleiomyoma is a rare benign tumor arising from the vascular smooth muscle cells and occurs most frequently on the lower limbs of middle-aged women. The prevalence of angioleiomyoma on the head and neck area is 8.5%. Unlike angioleiomyomas that occur on the lower extremities, pain is not common in patients with head and neck presentation. Making an initial diagnosis of angioleiomyoma is difficult at a

location apart from the predilection sites because of its nature of having no clinical symptoms or diagnostic characteristics. We report a rare case of angioleiomyoma on the antihelix of the left ear and a review of the literature on such tumors.

A 58-year-old woman was referred to our clinic for excision of a mass on the antihelix of her left ear. The patient gave a history of noticing a tiny mass 5 years earlier on her auricle without any symptoms. However, the mass exhibited a sudden increase in size within the previous month without symptoms such as ulceration, bleeding, or pain. The patient first visited the Department of Dermatology and underwent a punch biopsy under suspicion of hemangioma. The pathologic report confirmed angioleiomyoma, and the patient was transferred to the Department of Plastic Surgery for surgical excision. A physical examination revealed a 1 cm purplish round mass on the antihelix of the left ear. The mass was non-tender and firm on palpation (Fig. 1A). The mass did not show any signs of thrill or bruit. Complete surgical excision was performed, and the resected mass measured 9 × 5 × 5 mm with encapsulation (Fig. 1B). On follow-up 2 months after the operation, the patient had no clinical problems, and she was satisfied with the results (Fig. 1C). A histopathological examination showed a well circumscribed mass with a fibrous capsule (Fig. 1D). The tumor was composed of smooth muscle, presenting as interlacing bundles between numerous vascular channels (Fig. 1D, E).



**Fig. 1.** A case of angioleiomyoma on the left ear. (A) A firm, round-shaped, purple-colored mass was on the antihelix of the left ear. (B) The excised specimen was a 9 × 5 × 5 mm mass, encapsulated by fibrous tissue. (C) Postoperative follow-up at 2 months revealed excellent functional and cosmetic outcomes. (D) Histopathologically, the tumor was well circumscribed with a fibrous capsule (H&E, ×20). (E) The tumor was composed of smooth muscle, presenting as interlacing bundles between numerous vascular channels (H&E, ×400).

Leiomyoma is a benign mesenchymal tumor characterized by the proliferation of smooth muscle cells. These tumors are histologically classified into three groups: solid leiomyoma, angioleiomyoma, and epithelioid leiomyoma. A case of leiomyoma on the wall of a blood vessel was first published by Aufrecht [1] in 1868. Angioleiomyoma most commonly occurs in middle-aged women and is usually solitary and painful. Hachisuga et al. [2] reported in their clinicopathologic study of angioleiomyoma that among 562 cases, 500 (89.0%) had developed on the extremities, and 375 of these cases were on the lower extremities. Angioleiomyoma occurred on the head and neck area in 48 cases (8.5%) and on the trunk in 12 cases (2.5%).

Morimoto [3] categorized angioleiomyomas into three types according to their histologic patterns: solid or capillary, cavernous, and venous types. A solid or capillary type, the most common type of angioleiomyoma, consists of smooth muscle bundles. Because of their close interlocking structures, these bundles give angioleiomyoma a slit like shape. A solid or capillary angioleiomyoma on the extremities is usually painful, whereas pain is relatively uncommon for patients with an angioleiomyoma on the head and neck area. A cavernous type tumor is composed of a dilated vascular channel with thin smooth muscular wall. A venous angioleiomyoma has a thick smooth muscle wall and often develops on the head and neck area of males.

It is difficult to make a differential diagnosis of an angioleiomyoma from other diseases because it does not have any specific clinical manifestations. This tumor is unusual in that one symptom is pain, appearing usually when the lesion is located on an extremity. As in this case, angioleiomyomas on the head and neck area usually are not painful. Fibroma, neurofibroma, neurilemmoma, pleomorphic adenoma, and hemangioma should be ruled out when diagnosing angioleiomyoma. In our case, a punch biopsy was performed under a suspicion of hemangioma, which turned out to be angioleiomyoma. Magnetic resonance imaging (MRI) and digital subtraction angiography are useful for diagnosis. Radiologic images of MRI for angioleiomyoma show an isointense to slightly hyperintense signal compared with muscle on T1-weighted images, and mixed hyper- and iso-intensity areas with a hypointense rim corresponding to a fibrous capsule on T2-weighted images. On the other hand, neurofibroma shows low-to-intermediate intensity on T1-weighted images and heterogeneity on T2-

weighted images. Neurilemmoma, one of the differential diagnoses, shows the specific "target sign" around the peripheral nerves on MRI [4].

Angioleiomyoma can be diagnosed with a pathologic examination. However, neurofibroma, palisaded encapsulated neuroma, and neurilemmoma need to be ruled out. Immunohistochemistry markers such as desmin, smooth muscle antibodies (SMA), HHHF-35, S-100 protein, and CD 34 can be helpful in making a differential diagnosis. Desmin, SMA, and HHHF-35 are specific markers for smooth muscle. The S-100 protein can rule out neurogenic tumors from angioleiomyomas because the S-100 protein is positive for only neurogenic tumors. Positivity for CD-34 implies that the tumor has arisen from endothelial cells [5].

Complete surgical excision is the treatment of choice for angioleiomyoma, and it has been reported that recurrence after complete excision is rare. As in this case, angioleiomyoma developing on the antihelix of the auricle is rare. Making a differential diagnosis is important because this disease entity does not have any specific clinical manifestations. Furthermore, after a precise diagnosis is made, performing complete surgical excision is of paramount importance because angioleiomyomas have the potential for malignant progression into leiomyosarcoma.

## References

1. Aufrecht E. Ein myom der vena saphena. *Virchows Arch Pathol Anat Physiol Klin Med* 1868;44:133-5.
2. Hachisuga T, Hashimoto H, Enjoji M. Angioleiomyoma. A clinicopathologic reappraisal of 562 cases. *Cancer* 1984;54:126-30.
3. Morimoto N. Angiomyoma (vascular leiomyoma): a clinicopathological study. *Med J Kagoshima Univ* 1973; 24:663-83.
4. Ramesh P, Annareddy SR, Khan F, et al. Angioleiomyoma: a clinical, pathological and radiological review. *Int J Clin Pract* 2004;58:587-91.
5. Brooks JK, Nikitakis NG, Goodman NJ, et al. Clinicopathologic characterization of oral angioleiomyomas. *Oral Surg Oral Med Oral Pathol Oral Radiol Endod* 2002;94:221-7.