

---

## Reconstruction of Unexpected Huge Chest Wall Defect after Recurrent Breast Cancer Excision Using a TRAM Flap Combined with Partial Latissimus Dorsi Muscle Flap

Jae A Jung, Yang Woo Kim, So Ra Kang

*Department of Plastic and Reconstructive Surgery, Ewha Womans University Hospital, Ewha Womans University School of Medicine, Seoul, Korea*

**Correspondence:** So Ra Kang  
Department of Plastic and Reconstructive Surgery, Ewha Womans University Hospital, Ewha Womans University School of Medicine, 1071 Anyangcheon-ro, Yangcheon-gu, Seoul 158-710, Korea  
Tel: +82-2-2650-5149 Fax: +82-2-2651-9821  
E-mail: 00511@ewha.ac.kr

No potential conflict of interest relevant to this article was reported.

---

Received: 20 Sep 2012 • Revised: 27 Nov 2012 • Accepted: 10 Dec 2012  
pISSN: 2234-6163 • eISSN: 2234-6171  
<http://dx.doi.org/10.5999/aps.2013.40.1.76> • Arch Plast Surg 2013;40:76-79

Copyright © 2013 The Korean Society of Plastic and Reconstructive Surgeons  
This is an Open Access article distributed under the terms of the Creative Commons Attribution Non-Commercial License (<http://creativecommons.org/licenses/by-nc/3.0/>) which permits unrestricted non-commercial use, distribution, and reproduction in any medium, provided the original work is properly cited.

---

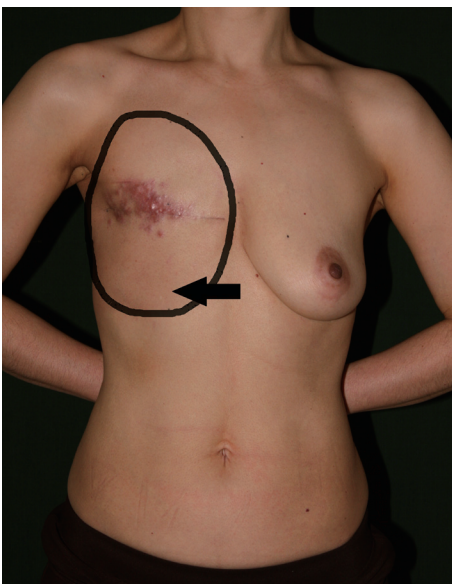The incidence of breast cancer is gradually increasing and immediate breast reconstruction after mastectomy is now widely conducted. In advanced breast cancer, postoperative adjuvant chemotherapy and radiotherapy rates are also increasing. In these patients, plastic surgeons are presented with the substantial challenge to cover an extensive skin and soft tissue defect after mastectomy with autologous tissue. The transverse rectus abdominis musculocutaneous (TRAM) flap, which was introduced by Hartrampf et al. [1] in 1982, is the most commonly used autologous tissue flap used for breast reconstruction. Its advantages include flexibility for breast shaping, the provision of a natural consistency and feel to the reconstructed breasts, and the avoidance of the potential complications associated with breast implant use. However, TRAM flaps may not provide sufficient volume in all patients. In particular, insufficient abdominal bulk limits the amount of tissue available, and thus, additional soft-tissue augmentation and contouring may be necessary to produce adequate volume, contour, and symmetry.

In some previous cases, after partial TRAM flap necrosis, the use of an autologous latissimus dorsi (LD) musculocutaneous flap is an attractive option [2], because it has a reliable vascular supply, provides an adequate volume of richly vascularized tissue to reconstruct even large defects, and has sufficient pliability to be molded to fit smoothly into even the most irregularly shaped partial mastectomy defects. Although many case reports have been issued about immediate breast reconstruction, no previous case

report has described the use of both a TRAM and LD flap for reconstruction. Here, we describe the successful reconstruction of a huge breast defect after the excision of a recurrent tumor using a TRAM flap and a partial LD muscle flap.

A 47-year-old female patient with a history of modified radical mastectomy of the right breast two years previously at another hospital visited with skin and multiple lymph node metastases of the right breast. Because postoperative radiotherapy was planned, we planned immediate reconstruction using autologous tissue after right breast cancer total excision and axillary lymph node resection (right axillary lymph node dissection level III). The defect size created by cancer excision was  $19 \times 30$  cm (from below the clavicle to the 8th rib level). The BMI of this patient was 18.3 with a slim body contour. At first we tried a contra-lateral unipedicled TRAM flap including zone I-IV (the blood circulation of zone IV was checked during the operation), but due to a larger defect size than expected before operation and the lack of sufficient anterior chest tissue, a  $7 \times 15$  cm defect remained in the right upper region. Thus, we designed a partial LD muscle flap to reconstruct the remaining defect. Maintaining the supine position and the previous incision, we split the LD muscle vertically with pedicle and rotated it medially to cover the remaining defect. The result was successful. The partial LD muscle flap was covered with a skin graft from the right thigh. The donor site of the TRAM flap was repaired with a primary closure. Closed suction drains were inserted into the donor and recipient sites.

On the third postoperative day, mild congestion was found at the distal margin of zone IV due to a circulation problem, but this was improved by applying a leech to the congested area. On postoperative day 14, the flap had totally survived, and during 3 months of follow-up, no complications, such as seroma, flap necrosis, dehiscence, or hernia, were encountered. Furthermore, at 2 months postoperatively, follow-up positron emission tomography revealed no recurrence at the right breast, although a suspicious metastatic bone lesion was detected around the 2nd lumbar ver-



**Fig. 1.**

Preoperative view of the 47-year-old patient with right breast cancer. The black circle and arrow indicate the defect size. After cancer excision, the defect size measured in the operation room was  $19 \times 30$  cm (from below the clavicle to the 8th rib level).

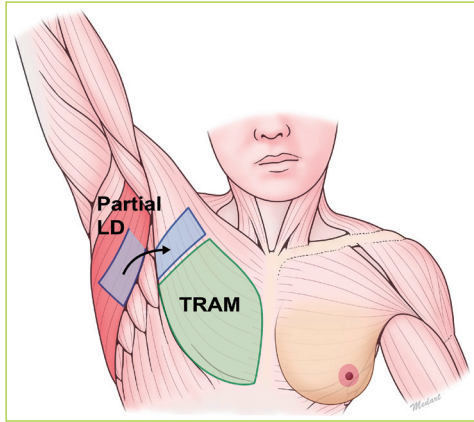


Fig. 2.

Schematic illustration of a partial LD flap with pedicle: splitting of LD muscle. LD, latissimus dorsi; TRAM, transverse rectus abdominis musculocutaneous.

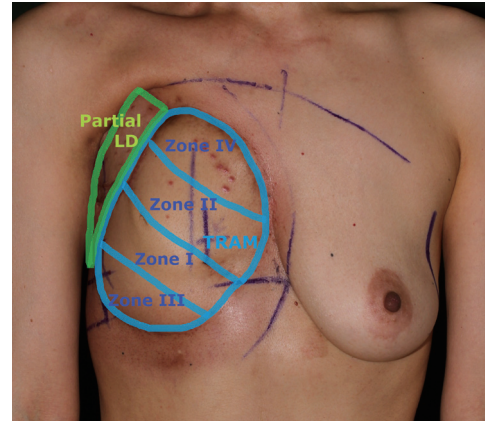


Fig. 3.

Photograph taken at the 85th day postoperatively. The green circle indicates the area of partial LD flap and skin graft, and the blue circle indicates the TRAM flap. LD, latissimus dorsi; TRAM, transverse rectus abdominis musculocutaneous.

tebra. Accordingly, additional chemotherapy and radiotherapy were administered, but no flap complication was detected other than slight flap shrinkage (Figs. 1-4).

Experience over the past 30 years has demonstrated that breast reconstruction is a safe, reliable operation that does not hide local recurrences or accelerate the rate or risk of breast cancer spread. Immediate breast reconstruction is widely conducted in early stage breast cancer because aesthetic results are satisfactory, although controversy remains regarding patients with locally advanced or recurrent breast cancer. In the recent past, locally advanced breast cancer was considered a contraindication to reconstruction because of 1) fear of an increased risk of local recurrence and delayed detection, 2) the recuperation time required prior to adjuvant chemotherapy, 3) a higher wound infection rate during postoperative chemotherapy, and 4) technical difficulties associated with reconstructed breast tissue during postoperative radiotherapy.

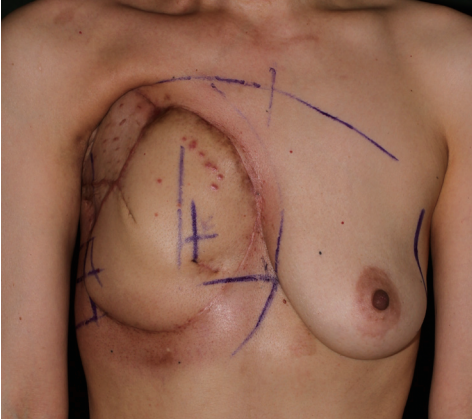
Nevertheless, immediate reconstruction can be conducted without specific problems in locally advanced breast cancer patients. Recently, many studies have demonstrated that cancer relapse rates are similar for locally advanced breast cancer patients regardless of immediate reconstruction [3]. Furthermore, in one comparative study of survival rates in cancer excised and non-excised groups, the excised group was found to have the higher survival rate [3]. In addition, the survival rate and quality of life were found to be better when a larger region was removed. Thus, to improve survival times, tumor

excisions are conducted broadly, which often leaves enormous skin and soft tissue defects requiring reconstruction. Moreover, the majority of patients now request immediate reconstruction due to higher expectations regarding body contours.

After its introduction by Hartrampf et al. [1] in 1982, the TRAM flap became the most commonly used autologous tissue flap for breast reconstruction. This flap has many advantages, which include, flexibility in terms of breast shaping, a natural consistency and feel, and the avoidance of any of the complications associated with the use of breast implants. However, many young candidates for breast reconstruction have a slim body contour and medium-sized breasts, and often, these women are very concerned about aesthetic outcome. The most natural result is generally achieved using autologous tissue, but many thin patients do not have sufficient abdominal volume for TRAM flap reconstruction, and thus, a combine implant and autologous flap procedure is usually performed [4]. However, thin patients can still benefit from a TRAM flap if it is combined with another autologous flap.

A LD musculocutaneous flap is selected when the TRAM flap is unavailable or otherwise unusable. For LD musculocutaneous flap operation, skin and muscle from the back are transferred around to the breast area to replace the skin and muscle removed during mastectomy. This is a safe, reliable flap with a good blood supply.

Despite improved equipment, techniques, and a greater awareness of radiation-associated morbidities,

**Fig. 4.**

Photograph taken at the 85th day postoperatively during radiation therapy, showing slight radiotherapy-induced flap shrinkage.

the cellular changes and injuries caused by radiotherapy are unavoidable, and in particular, skin and flap contractures caused by radiotherapy progress with time [5]. Therefore, if adjuvant radiotherapy is planned, breast reconstruction with autologous tissue should be conducted with enough tissue to cope with subsequent flap shrinkage.

We describe the successful reconstruction of an unexpected large soft tissue defect after recurrent breast cancer excision using a TRAM flap combined with a partial LD muscle flap. Because no positional change during surgery or incision lengthening is needed, this procedure is simple and quick, and can cover broad defects of the anterior chest and enable prompt further concomitant adjuvant radiation therapy after surgery.

## References

1. Hartrampf CR, Schefflan M, Black PW. Breast reconstruction with a transverse abdominal island flap. *Plast Reconstr Surg* 1982;69:216-25.
2. Serletti JM, Higgins J, Carras AJ. Free latissimus dorsi myocutaneous flap for secondary breast reconstruction after partial loss of a TRAM flap. *Plast Reconstr Surg* 1997;100:690-4.
3. Lee TJ, Hur WJ, Kim EK, et al. Outcome of management of local recurrence after immediate transverse rectus abdominis myocutaneous flap breast reconstruction. *Arch Plast Surg* 2012;39:376-83.
4. Kronowitz SJ, Robb GL, Youssef A, et al. Optimizing autologous breast reconstruction in thin patients. *Plast Reconstr Surg* 2003;112:1768-78.
5. Tran NV, Chang DW, Gupta A, et al. Comparison of immediate and delayed free TRAM flap breast reconstruction in patients receiving postmastectomy radiation therapy. *Plast Reconstr Surg* 2001;108:78-82.