

was no malignant transformation at all, nor any local or distant metastasis. This case is the largest in size ever reported in the literature, measuring 21 cm × 17 cm × 12 cm. Although the radiological findings suggested the involvement of the pericranium, surgical exploration and the management plan favored simple excision with a free margin and skin graft coverage. During extended follow-up, no signs or symptoms of recurrence were noted. This case illustrates the importance of the knowledge of the patterns of recurrence and the malignant potential of such lesions together with their application to various presentations.

## References

1. Satyaprakash AK, Sheehan DJ, Sanguenza OP. Proliferating trichilemmal tumors: a review of the literature. *Dermatol Surg* 2007;33:1102-8.
2. Anolik R, Firoz B, Walters RF, et al. Proliferating trichilemmal cyst with focal calcification. *Dermatol Online J* 2008;14:25.
3. Markal N, Kurtay A, Velidedeoglu H, et al. Malignant transformation of a giant proliferating trichilemmal tumor of the scalp: patient report and literature review. *Ann Plast Surg* 1998;41:314-6.
4. Poiares Baptista A, Garcia ES, Born MC. Proliferating trichilemmal cyst. *J Cutan Pathol* 1983;10:178-87.
5. Wang X, Yang J, Yang W. Multiple proliferating trichilemmal tumors in a middle-aged yellow man. *Tumori* 2010;96:349-51.

## Treatment of Atypical Pyoderma Gangrenosum on the Face

Hyo Hyun Seok, Min Suk Kang, Ung Sik Jin

*Department of Plastic and Reconstructive Surgery, Seoul National University College of Medicine, Seoul, Korea*

**Correspondence:** Ung Sik Jin  
Department of Plastic and Reconstructive Surgery, Seoul National University College of Medicine, 101 Daehak-ro, Jongno-gu, Seoul 110-744, Korea  
Tel: +82-2-760-3759, Fax: +82-2-745-5986, E-mail: usj1011@snu.ac.kr

This article was presented as poster at the second Research and Reconstructive Forum on June 1-2, 2012 in Gwangju, Korea.

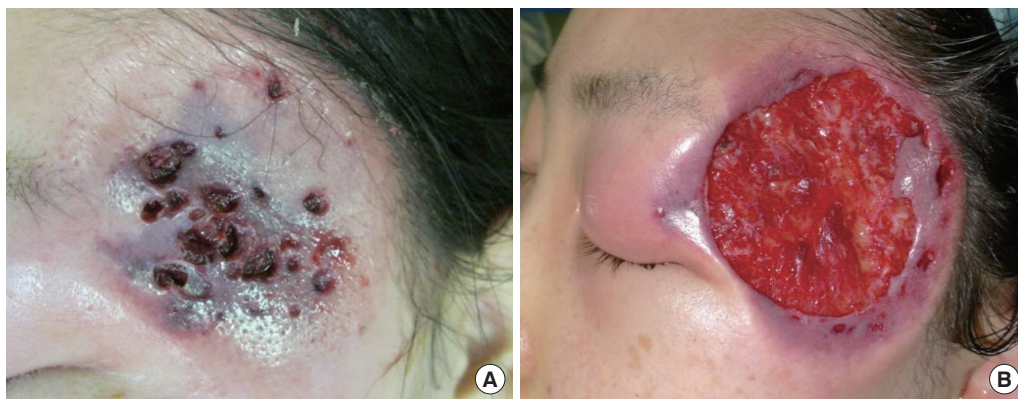No potential conflict of interest relevant to this article was reported.

Received: 27 Mar 2013 • Revised: 19 Apr 2013 • Accepted: 7 May 2013  
pISSN: 2234-6163 • eISSN: 2234-6171  
<http://dx.doi.org/10.5999/aps.2013.40.4.463> • Arch Plast Surg 2013;40:463-465

Copyright © 2013 The Korean Society of Plastic and Reconstructive Surgeons  
This is an Open Access article distributed under the terms of the Creative Commons Attribution Non-Commercial License (<http://creativecommons.org/licenses/by-nc/3.0/>) which permits unrestricted non-commercial use, distribution, and reproduction in any medium, provided the original work is properly cited.

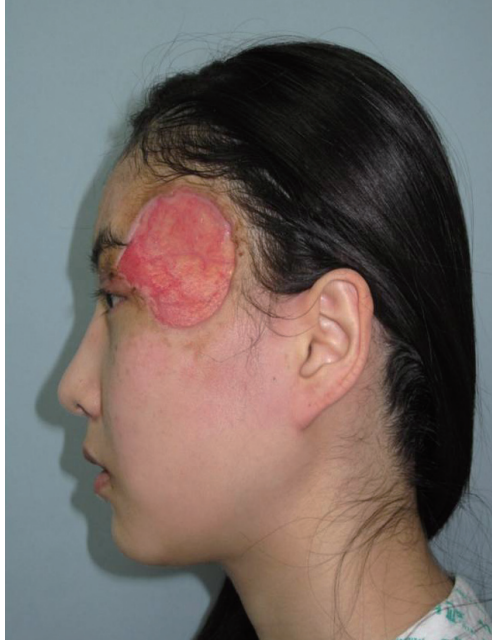Pyoderma gangrenosum is a rare destructive cutaneous disease characterized by a painful, progressive, and necrotizing wound. Pathologically, pyoderma gangrenosum is a noninfectious neutrophilic dermatitis that usually starts with a sterile pustule, which rapidly progresses to a large painful ulcer with undermined violaceous borders [1].

The treatment of pyoderma gangrenosum has been well reviewed but not established. Conservative management utilizing prolonged, high-dose systemic corticosteroids and other immunosuppressive agents, in addition to gentle local wound care, characterizes traditional treatment of pyoderma gangrenosum.

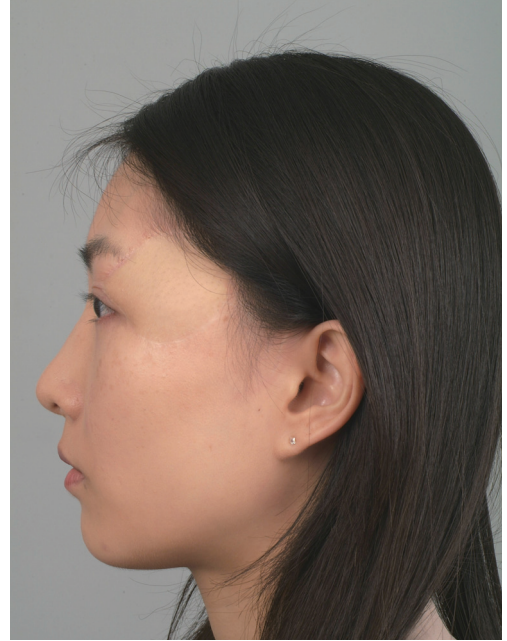

**Fig. 1.**

Atypical pyoderma gangrenosum on the face. (A) Multiple ulcerative lesions around a reddish-purple margin. (B) Rapidly progressive lesion with ulceration, following serial surgical debridement.

**Fig. 2.**

Importance of conjunction with medical treatment. Ten days following the commencement of prednisolone. Stabilized wound following surgical debridement and steroid therapy.

**Fig. 3.**

Photograph of the patient two years after the operation.

Surgical treatment of pyoderma gangrenosum patients in the reconstruction field is very challenging due to the systemic immunologic condition of this disease. Surgical treatment, itself, could initiate other loci of disease with the development of new lesions at the areas of surgical trauma. Notably, the microvascular free flap reconstruction, despite its advantages in soft tissue volume replacement, has not been generally performed.

The objective of this paper is to 1) present a rare case of refractory facial ulcerative lesion presented as pyoderma gangrenosum, 2) emphasize the exact diagnosis of this disease, and 3) recommend active surgical intervention like free flap reconstruction in conjunction with medical therapy as a treatment option for similar patients in the future.

A 27-year-old female patient was referred from the dermatologic clinic with a 6 cm × 5.5 cm painful, ulcerative, and necrotic lesion in the left temporal area. Her lesion began with a small pustule and progressed to a widening, painful ulcerative lesion (Fig. 1). Repeated cultural studies and biopsies of the affected area were performed at the dermatologic clinic. The findings were nonspecific. The lesion progressed despite dermatologic management, including local wound care.

When we met her in our clinic, we suspected some

information was missing. Through complete history taking, we found out that she had been previously diagnosed with Crohn's disease. We clinically suspected and diagnosed her with pyoderma gangrenosum. We referred her to an internal medicine physician for her medical treatment. Through a thorough medical examination, including colonoscopy and blood testing, we determined that she had been in the active stage of pyoderma gangrenosum. According to the recommendation from the Department of Internal Medicine, we started steroid therapy (prednisolone 0.5 g/kg per day for 5 days, initially) for her and tapered it progressively.

Slight improvement was noticed after 1 week and became obvious after 2 weeks (Fig. 2). It was decided to discontinue the steroid treatment after 3 weeks. The pain subsided and healthy granulation tissue grew. We then performed a groin free flap on her skin and subcutaneous defect and facial deformity. The pedicles of the harvested groin flap used were from the superficial circumflex iliac artery and superficial circumflex iliac vein. The recipient vessels were the superficial temporal artery and superficial temporal vein. The facial contour showed aesthetically satisfactory results after the surgery, and the volume deficiency of her face was restored (Fig. 3).

Unlike a split-thickness skin graft, which is known to be commonly used in surgical management of

pyoderma gangrenosum, through a well-designed groin free flap reconstruction, we observed satisfactory patient outcomes, including rapid wound closure and a favorable cosmetic appearance. We were able to maintain her facial contour with the groin free flap reconstruction. We were also able to decrease the wound healing time and hospital stay by a combination of active medical and surgical therapy. No recurrence of the disease has been noted.

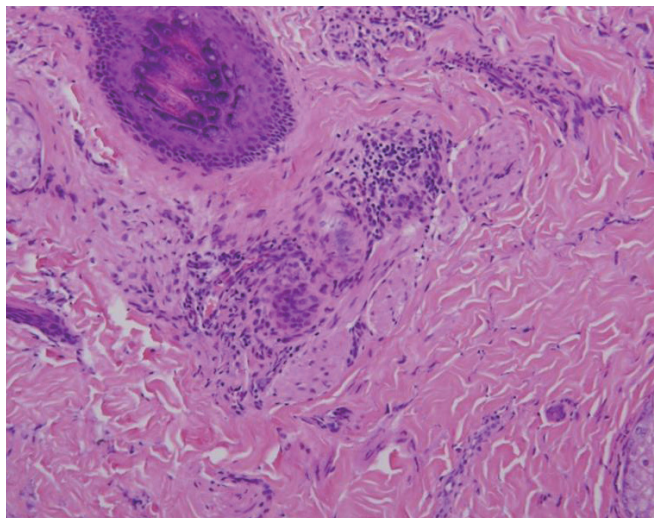
Although pyoderma gangrenosum is rare, it usually occurs in the lower limbs. More than 70% of patients have involvement of the lower limbs. Facial involvement of pyoderma gangrenosum such as this case is very rare. Pyoderma gangrenosum on the upper extremities, head, or neck, as a more superficial lesion, is classified as atypical pyoderma gangrenosum.

Pyoderma gangrenosum is diagnosed clinically. It involves the exclusion of other diseases like infection or cellulitis. A patient's history of possible underlying disease, and specific investigations based on that background, are necessary. In as many as 70% of cases, pyoderma gangrenosum may be associated with a variety of diseases, including inflammatory bowel disease and rheumatoid arthritis. A high index of suspicion is essential to clinically diagnose this condition. Failure to recognize this disease could lead to large tissue defects in the lesions and hazardous results.

Although the histopathologic findings are not specific or diagnostic of pyoderma gangrenosum, a biopsy of the affected area and tissue culture allowed us to exclude other diseases (Fig. 4) [2].

Management of pyoderma gangrenosum includes local wound care, topical therapy, and systemic therapy. Many patients respond initially to systemic glucocorticoids. In a chronic course, immunosuppressive agents, such as cyclosporine, are usually added due to several side effects of the prolonged use of steroids.

Reconstruction of tissue defects in pyoderma gangrenosum patients is challenging in several respects. Pathergy, the development of cutaneous lesions at the sites of trauma, is known to be a common feature of pyoderma gangrenosum. Surgery, itself, may be a trigger factor initiating other lesions. Split skin grafts have been used as a surgical option for pyoderma gangrenosum in some reported cases [3,4]. The important limitation of this option is a lack of bulk to maintain the patient's contour. In our case also, we would not have been able to maintain this patient's facial contour if we had performed a skin graft for the skin and subcutaneous defect. Many surgeons, having the distorted view that free flap reconstruction will



**Fig. 4.** Histologic examination. The vasculitis: mixed lymphocytic and neutrophilic perivascular infiltrations and focal fibrinoid necrosis of the vascular wall with no observable evidence of bacterial or fungal organisms (H&E,  $\times 200$ ).

hinder wound healing in pyoderma gangrenosum, choose a simpler method, such as split skin grafts.

Although treatment for these patients is more complex because they require close consultation with the department of internal medicine for combination therapy with steroids or immunosuppressive agents, we should not be afraid to initiate active surgical intervention, like free flap reconstruction. As plastic surgeons, we should always consider aesthetic outcomes in addition to the recovery of patient status. In this paper, we presented a successful case of reconstruction with a free flap in an atypical case of pyoderma gangrenosum in the face, an area requiring contour maintenance to ensure the best aesthetic results.

## References

1. Wollina U. Clinical management of pyoderma gangrenosum. *Am J Clin Dermatol* 2002;3:149-58.
2. Su WP, Davis MD, Weenig RH, et al. Pyoderma gangrenosum: clinicopathologic correlation and proposed diagnostic criteria. *Int J Dermatol* 2004;43:790-800.
3. Seul CH, Kim BJ, Lee SJ, et al. Surgical management of pyoderma gangrenosum: a case report. *J Korean Soc Plast Reconstr Surg* 2005;32:135-8.
4. Lim SY, Park DH, Pae NS, et al. Clinical experience of pyoderma gangrenosum with extensive soft tissue necrosis. *J Korean Soc Plast Reconstr Surg* 2008;35:615-8.